



Case Report

Treatment of Acute Upper Limb Ischemia after Iatrogenic Left Subclavian Artery Injury during Coronary Artery Bypass Grafting

Modugno P^{1*}, Annuvolo PA², Peluso N², Centritto EM¹, Picone V¹, Maiorano M¹, Spalletta C³, Cuzzone V⁴, Aloisi G⁴, Modugno FM⁵, Magnano D⁴, Castellano G³

¹Unit of Vascular Surgery, Gemelli Molise S.p.A, Campobasso, Italy

²Università Cattolica del Sacro Cuore, Unit of Vascular Surgery, Fondazione Policlinico Universitario A. Gemelli I.R.C.C.S., 00168 Rome, Italy

³Department of Cardiovascular Sciences, Gemelli Molise S.p.A, Campobasso, Italy

⁴Department of Anesthesia and Intensive Care, Gemelli Molise S.p.A., Campobasso, Italy

⁵Medicine and Surgery School of Medicine, University of Cattolica del Sacro Cuore, Rome, Italy

*Corresponding author: Pietro Modugno, Unit of Vascular Surgery, Gemelli Molise Hospital, Catholic University of the Sacred Heart, Campobasso, Italy

Citation: Modugno P, Annuvolo PA, Peluso N, Centritto EM, Picone V, et al (2023) Treatment of Acute Upper Limb Ischemia after Iatrogenic Left Subclavian Artery Injury during Coronary Artery Bypass Grafting. Ann Case Report. 8: 1343. DOI:10.29011/2574-7754.101343

Received: 07 June 2023, Accepted: 12 June 2023, Published: 08 July 2023

Abstract

Background: Iatrogenic subclavian artery lesion during surgical exposure of the left internal mammary artery represents a rare complication of cardiac surgery for myocardial revascularization and difficult to manage and can lead to major comorbidities. When signs of acute ischemia occur, revascularization of the upper limb is necessary. When an endovascular approach with artery stenting is not feasible, carotid-subclavian bypass is considered the technique of choice. Carotid-axillary bypass as an alternative for revascularization of the upper limb can be choose when the location of the lesion makes it very difficult to expose the vessel.

Case Description: We describe the case of a patient undergoing a left carotid-axillary bypass for acute upper limb ischemia due to iatrogenic occlusion of subclavian artery during coronary artery bypass grafting. Complete revascularization of the upper limb was assessed with a duplex ultrasound and a post-operative Computed Tomography Angiography, in the absence of procedure-related neurological complications.

Conclusions: Carotid-axillary bypass represents a viable alternative for surgical revascularization of the upper limb when a carotid subclavian bypass is not feasible. It is a safe and technically simple procedure with good short and long-term results and low complication rates.

Keywords: Acute Upper Limb Ischemia; Carotid-Axillary Bypass; Subclavian Arterial Injury; Massive Hemorrhage

Introduction

Iatrogenic subclavian artery lesion during surgical exposure of the left internal mammary artery represents a rare complication of cardiac surgery for myocardial revascularization and, moreover, difficult to manage and can lead to major comorbidities. When signs of acute ischemia occur, revascularization of the upper limb is necessary. When feasible, subclavian artery stenting is the gold standard for short and proximal occlusions of the artery. On the other hand, carotid-subclavian bypass is considered the technique of choice, although not without risk, when stenting is not possible or to treat longer and highly calcified lesions. Because of the lower complication rate, high technical success rate and good long-term patency rate (> 80% at 5 years), endovascular treatment has become increasingly popular [1]. In case of subclavian artery perforation during an upper limb revascularization procedure, placement of a covered stent may be a valid solution [2]. The inability to navigate a stent or a lesion in the supraclavicular tract of the subclavian artery could require a surgical conversion with artery closure via direct suture and pledget use, then a carotid-subclavian bypass with an increase in loco-regional complications such as supraclavicular hematoma and left hemothorax, as well as damage of major lymphatic vessels and nerves. Exposure of axillary artery through infraclavicular approach is technically easier. However, a potential risk of brachial plexus damage may be related [3]. Carotid-axillary bypass is a viable surgical alternative in upper limb revascularization when subclavian artery lesion interest the supraclavicular tract and makes subclavian exposure not possible. Criado et al, performed 26 carotid-axillary surgical procedures in 10 years and reported 96% graft patency rate in four years of follow-up [4]. We describe the case of a 63-year-old female patient undergoing a left carotid-axillary bypass using an 8 mm expanded poly-tetra-fluor-ethylen (PTFE – Propaten, Gore) graft for acute upper limb ischaemia due to iatrogenic occlusion of subclavian artery during coronary artery bypass grafting (CABG).

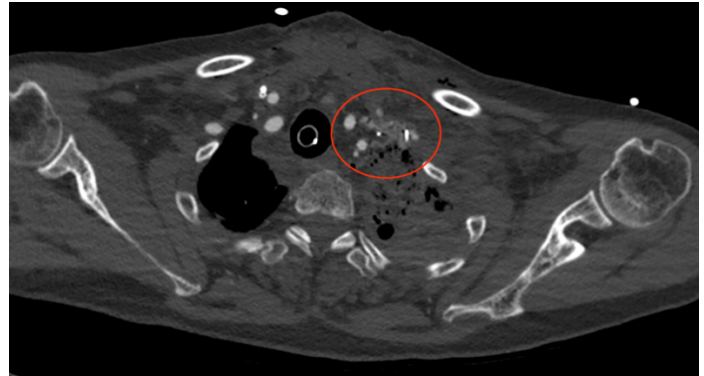


Figure 1: Computed Tomography Angiography of hematoma and hemorrhagic infarction of tissues of the supraclavicular fossa after subclavian artery lesion.

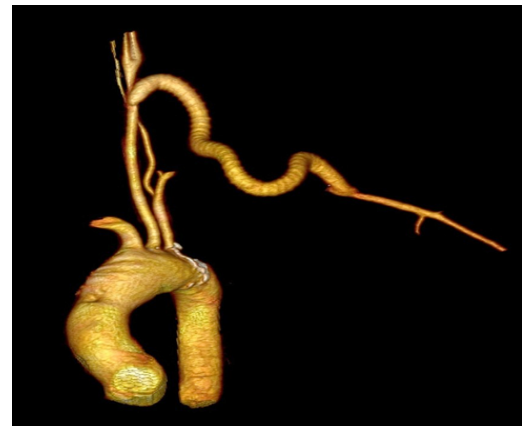

Figure 2: 3D-rendering of carotid-axillary bypass.

Case Description

A 63-year-old woman was admitted to the Cardiac Surgery Unit of our Institution for single-vessel ischemic heart disease. The patient reported the onset of typical chest pain, and then she underwent a coronary angiography that documented significant stenosis of the ostial Anterior Interventricular Artery with

involvement of the common trunk. The patient underwent off-pump surgical myocardial revascularization through single aorto-coronary bypass surgery (left mammary artery on LAD). During the left internal mammary artery isolation, the left subclavian artery was injured with subsequently massive haemorrhage which required Extracorporeal Circulation. The lesion was treated with suture of the artery with pledgets reinforcement immediately after the origin of the left vertebral artery to control massive bleeding. In the immediate post operative course in the Intensive Care Unit, acute left upper limb ischaemia with the presence of cyanosis, hypothermia and pulseless was observed. An urgent Computed Tomography Angiography (CTA) was performed showing complete occlusion of the left subclavian artery after the origin of the vertebral artery, with the presence of hematoma and hemorrhagic infarction of tissues of the supraclavicular fossa (Figure 1). The patient then underwent an urgent surgical revascularization of the left upper limb through a left carotid-axillary bypass with an 8 mm expanded poly-tetra-fluor-ethylen (PTFE – Propaten, Gore) graft. At the end of the procedure, brachial and radial pulses were present. Post-operative course was uneventful. Complete revascularization of the upper limb was assessed in the absence of procedure-related neurological complications. Duplex ultrasound showed patency of the bypass and normal perfusion of the brachial, radial and ulnar arteries. The 3-months follow up CTA documented good patency of the bypass graft with normal vascularization of the axillary, brachial, radial and ulnar arteries (Figure 2).

Discussion

In most cases, massive bleeding due to iatrogenic subclavian artery injury, particularly those located at the thoracic outlet, is catastrophic. Management of a lesion of the subclavian artery in the upper thoracic outlet through a left thoracotomy is extremely difficult and requires great skill and synergy between surgeons and anesthetist. The first step is to control the bleeding from the rupture site of the subclavian artery and to replace the sudden and copious blood loss. The second step is to ensure hemostasis by repairing the lesion. In our case, the lesion of the left subclavian artery occurred during the cardiac surgery of coronary artery bypass grafting using LIMA-LAD through left mini-invasive thoracotomy. Furthermore, as usual, the wall of the subclavian artery is particularly fragile and thin and in case of iatrogenic injuries, it tends to tear completely. Therefore, a severe haemorrhage with hypovolemic shock immediately started which made it necessary to perform a temporary haemostasis with manual compression and to convert the operation through a median sternotomy to allow extracorporeal circulation to start as soon as possible to avoid cardiac arrest. After extracorporeal circulation was started and the patient was stabilized from a haemodynamic point of view, the cardiac surgeon proceeded to prepare the left subclavian artery and repair the lesion with suture of the artery with pledgets reinforcement to ensure haemostasis.

Two hours later acute left upper limb ischaemia occurred. In such cases, endovascular or surgical approaches can represent the treatment of choice. Percutaneous angioplasty has become an increasingly popular option to treat symptomatic subclavian artery (SCA) lesions. The technical success rate of percutaneous SCA stenosis therapy with stenting is up to 91%-100% and ranges from 83% to 94% in totally occluded SCAs [5], while comorbidity and mortality rates are low. SCA stenting is also characterised by its proven efficacy, long-term patency, possibility to avoid general anaesthesia and shorter hospitalisation [6]. Therefore, when an intervention is indicated, a percutaneous approach is currently favored over surgical intervention. Despite many advantages, there are still some possible procedural complications, including stroke, dissection, distal embolization, arterial thrombosis, and access site complication. SCA perforation during stenting has rarely been reported; however, it may cause severe complications, such as supraclavicular hematoma and left hemothorax. Endovascular intervention is frequently preferred over surgical bypass, because of its higher safety [7]. In our case, the deployment of a covered stent could certainly be the solution but could not be performed due to the non-thrombotic or atherosclerotic nature of the lesion, with the risk of not being able to cross the occlusion with the guide or stent. A left carotid-subclavian bypass was a non-viable option due to the localisation of the lesion and for the presence of a hematoma with haemorrhagic infarction of the soft tissues as documented at the CT scan. The only target vessel suitable for an extraanatomical bypass to left upper limb revascularization was the axillary artery in the deltoid-pectoral groove. Therefore, a caroti-axillary bypass with an 8 mm heparinized reinforced expanded poly-tetra-fluor-ethylen (PTFE – Propaten, Gore) graft was performed. Extra thoracic revascularization is an effective and safe way to treat branch occlusions of the aortic arch. The carotid-subclavian bypass, first proposed by Diethrich, is the treatment of choice [3]. Its excellent long-term results have been replicated by physicians around the world. Nevertheless, the potential risks and difficulties of subclavian artery exposure must be further emphasized. The proximity of important lymphatic and nerve structures can create technical difficulties and increase the risk of complications. During our surgery we preferred to avoid a subclavicular tunnelling of the graft in favour of a subcutaneous one because of the risk of venous injury. Many authors [8-10] state that the use of the axillary artery as a distal anastomotic site would simplify the procedure and avoid the risk of lymphatic injury. Carotid axillary bypass can be a valid alternative to carotid-subclavian bypass. The perioperative stroke risk connected to manipulation of the carotid artery is very low. Shunting is unnecessary unless a significative internal carotid lesion co-exists on the same side. Concomitant carotid endarterectomy at the donor graft site may be performed in patients with severe atheromatous plaques.

Conclusions

Carotid axillary bypass represents a viable alternative for surgical revascularisation of the upper limb when a carotid subclavian bypass is not feasible. It is a safe and technically simple procedure with good short and long-term results and low complication rates.

Conflict of Interest: All authors have no conflicts of interest to declare.

Ethical Statement: The authors are accountable for all aspects of the work in ensuring that questions related to the accuracy or integrity of any part of the work are appropriately investigated and resolved. The patient

References

1. Patel SN, White CJ, Collins TJ, Daniel GA, Jenkins JS, et al (2008) Catheter-based treatment of the subclavian and innominate arteries. *Catheter Cardiovasc Interv* 71: 963-968.
2. Chih-Hung L, Chung-Lin T, Wei-Chung C, Su CC, Lee WL (2017) Iatrogenic Subclavian Artery Perforation Rescued by Operator-Modified Graft Stent. *Yonsei Med J* 58: 462-466.
3. Diethrich EB, Garrett HE, Ameriso J, Crawford ES, el-Bayar M, et al (1967) Occlusive disease of the common carotid and subclavian arteries treated by carotid-subclavian bypass: analysis of 125 cases. *Am J Surg* 114: 800-808.
4. Criado FJ (1982) Extrathoracic management of aortic arch syndrome. *Br J Surg* 69: S45-S51.
5. Ochoa VM, Yeghiazarians Y (2011) Subclavian artery stenosis: a review for the Vascular Medicine practitioner. *Vasc. Med.* 16: 29-34.
6. Takach TJ, Duncan JM, Livesay JJ (2005) Brachiocephalic reconstruction II: operative and endovascular management of single-vessel disease. *J Vasc Surg* 42:55-61.
7. Naganur S, Santosh K., Sihag BK, Gawalker AA, Prasad K (2020) Bailout subclavian artery stenting in a sick child with iatrogenic subclavian artery perforation: case report. *The Egyptian Heart Journal* 72: 10-22.
8. Lyons C., Galbraith G (1957) Surgical treatment of atherosclerotic occlusion of the internal carotid artery. *Ann. Surg* 146: 487-498.
9. Lowell RC, Mills J (1993) Critical evaluation of axillaryartery bypass for surgical management of symptomatic subclavian and innominate artery occlusive disease. *Cardiovasc. Surg.* 1: 530-535.
10. Barakat TI, Kenny L., Khout H. Timmons G, Bhattacharya V (2011) Carotid axillary bypass in a patient with blocked subclavian stents: a case report. *J of Medical Case Reports* 5: 237-240.