



Research Article

# Therapeutic Effects of Endoscopic Sinus Surgery in Eosinophilic Sinusitis Patients with Severe Headache

Tessei Kuruma\*, Mariko Arimoto, Kinga Yo, Yuka Kawade, Yutaka Kondo, Yasue Uchida, Tetsuya Ogawa, Yasushi Fujimoto

Department of Otorhinolaryngology, Head and Neck Surgery, Aichi Medical University, Aichi, Japan

\*Corresponding author: Tessei Kuruma, Department of Otorhinolaryngology, Head and Neck Surgery, Aichi Medical University, Aichi, Japan

Citation: Kuruma T, Arimoto M, Yo K, Kawade Y, Kondo Y, et al. (2022) Therapeutic Effects of Endoscopic Sinus Surgery in Eosinophilic Sinusitis Patients with Severe Headache. J Surg 7: 1539. DOI: 10.29011/2575-9760.001539

Received Date: 22 July, 2022; Accepted Date: 25 July, 2022; Published Date: 28 July, 2022

## Abstract

**Background:** Eosinophilic Chronic Rhinosinusitis (ECRS) is an intractable disease with symptoms that affect daily life, such as nasal obstruction and olfactory disturbances. Among the symptoms, headache is the symptom that most affects daily life.

**Method:** In this study, we examined and compared the clinical findings of 40 ECRS patients who underwent Endoscopic Sinus Surgery (ESS) at our hospital, focusing on eight patients who complained of severe headache. The 40 ECRS patients were divided into three groups: those with severe headache (group S) (n=8), moderate headache (group M) (n=14), and without headache (group N) (n=18), and the clinical features in each group were compared. The six main symptoms of the three groups were compared using the Nasal Symptoms Questionnaire (NSQ) before and 2 years after surgery.

**Results:** In group S, there was a significant improvement in headache after ESS in all patients ( $P<0.05$ ). In the S+M group, 91% of patients showed improvement in headache after ESS. In each of the three groups, most of the symptoms, and not only headache, were significantly improved after ESS. In group S, six patients (75%) expressed preoperative improvement in headache symptoms with oral steroids. This suggests that it might be possible to preoperatively determine whether headache is caused by ECRS or other causes based on whether it improves with preoperative steroid therapy. Intergroup comparisons showed that more patients in group S had a short anteroposterior diameter of the frontal sinus than in the other groups, and evaluation indicated that ECRS patients with a short antero-posterior diameter of the frontal sinus are more likely to have severe headache.

**Conclusion:** ESS led to a significant improvement in all symptoms in ECRS cases. Severe headache is known to interfere with daily life in ECRS patients. We speculated that patients with severe headaches might show a relatively greater improvement in headache severity after ESS. However, since ECRS is a recurrent disease, postoperative follow-up and treatment, such as with nasal rinses and steroid nasal sprays, are very important for maintaining the efficacy of surgery.

**Keywords:** Endoscopic sinus surgery; Eosinophilic chronic rhinosinusitis; Headache; Nasal symptoms questionnaire.

## Introduction

Headaches are a common complaint among the general public; the World Health Organization estimates the prevalence of headaches among adults at 47%, with half to three-quarters of adults aged 18-65 years experiencing headache in the previous year. The International Classification of Headache Disorders (ICHD) defines a myriad of more than 200 different types of headache [1]. The ICHD also includes headaches that occur secondary to nasal and paranasal sinus pathology, such as acute rhinosinusitis, chronic or recurring sinusitis, and disorders of the nasal turbinates or septum. Two major Chronic Rhinosinusitis (CRS) guidelines include the presence of facial pain and headache as part of the clinical diagnostic criteria for CRS [2,3]. However, the association between headache and CRS continues to be controversial, such that the European Position Paper on Rhinosinusitis and Nasal Polyps (EPOS) guidelines highlight literature demonstrating that only a minority of subjects with CRS experience headache [3]. Classically, primary CRS is divided into two major subtypes based on its phenotypic appearance: CRS with Nasal Polyps (CRSwNP) and CRS without Nasal Polyps (CRSsNPs) [4,5]. CRS is also subtyped as Eosinophilic CRS (E CRS) and non-E CRS (NECRS) according to the presence or absence of predominant tissue eosinophilic infiltration. E CRS is considered a special subtype of CRS [6-8] and also a subtype of recalcitrant CRS, which usually has worse disease severity [9-11] and poorer treatment outcomes [11-14] compared to NECRS. Half of the cases of CRSwNP in Japan have been reported to be E CRS [8,15]. CRS patients rank headache as the most debilitating symptom associated with CRS [16], although the results of studies examining resolution of facial pain and headache after ESS are mixed. The other main symptoms of E CRS include olfactory disturbances, nasal obstruction, and posterior rhinorrhea. However, few reports have described the relationship between E CRS cases and headache and its improvement with treatment in CRS cases. In the present study, we describe our experience with eight E CRS patients with migraine-like headache that was more severe than olfactory dysfunction or posterior rhinorrhea, in whom the headache improved after surgery. By comparing these cases with other E CRS cases stratified according to the degree of headache, we aimed to explore the efficacy of Endoscopic Sinus Surgery (ESS) for headache symptoms and the causes of headache in E CRS cases.

## Subjects and Methods

In this study, we retrospectively evaluated 40 patients who were diagnosed with E CRS and underwent ESS by the same surgeon at the Department of Otolaryngology, Aichi Medical University, between January 2018 and December 2019. Of the 40 E CRS cases,

the characteristics and clinical course of eight E CRS cases with severe headache as the main complaint were investigated. Various clinical and surgical characteristics in the eight E CRS cases with severe headache (age, gender, pain site, pain frequency, duration of headache, change in headache with oral steroids, surgical method, severity of headache before and after surgery, surgery performed, and the time post-surgery when the headache disappeared) were examined retrospectively. E CRS was diagnosed based on the diagnostic criteria of the Japanese Epidemiological Survey of Refractory Eosinophilic Chronic Rhinosinusitis (JESREC) [17]. All 40 patients underwent Endoscopic Sinus Surgery (ESS), and the Headache Impact Test-6 (HIT-6) (minimum possible score 36 points, maximum 78 points) [18] was used to assess headache before and after surgery. The 40 E CRS patients were divided into three groups based on the severity of headache as the severe headache group (group S) (n=8), mild to moderate headache group (group M) (n=14), and no headache group (group N) (n=18). The three groups were compared with respect to age, gender, presence of Allergic Rhinitis (AR), presence of Bronchial Asthma (BA) complications, eosinophils in blood, and eosinophil count in biopsy specimens of polyps (mean eosinophil count in specimens examined using 400x magnification in three fields of view). In order to further investigate the mechanism of headache, sinus CT scores by Lund and Mackey [19], location of the anterior ethmoidal nerve canal, anteroposterior diameter of the nasofrontal canal, and presence of nasal mucosa contact points were compared between the three groups. The location of the anterior ethmoidal nerve canal was divided into three regions according to its course, as follows: 2: the second basal lamella, 2-3: between the second and third basal lamellas, and 3: the third basal lamella). A Nasal Symptoms Questionnaire (NSQ) was administered before and 2 years after surgery. The NSQ evaluates a total of 16 symptoms to assess subjective symptoms and quality of life in CRS patients [20]. Of the 16 items, the six items of headache, nasal congestion, post-nasal drip, olfactory disorder, sleep disorder, and mood disorder were evaluated in the E CRS patients using a 7-point scale from 0 to 6, and the improvements in nasal symptom scores before and after surgery in each group were compared.

## Statistical Methods

Comparison of HIT-6 before and after surgery in patients with severe headache was statistically analyzed by the Wilcoxon rank sum test. The Steel-Dwass method was used to compare the various items in the three groups. The superiority difference was determined at a risk rate of 5%. The Mann-Whitney U test was used to compare pre- and postoperative NSQ scores in the three groups. Data are presented as the mean  $\pm$  standard deviation, and were considered statistically significant when  $p$  was  $< 0.05$ . The statistics software Statcel 4 (Tokyo, Japan) was used for all evaluations.

## Results

Of the 40 cases diagnosed with ECRS and treated using ESS performed by the same surgeon at the Department of Otolaryngology of Aichi Medical University between January 2019 and December 2020, eight cases presented with severe headache as the main complaint. Table 1 shows the characteristics of the study items in these cases. The cases included three males and five females, with a mean age of  $44.8 \pm 10.9$  years (range 21 to 51 years). The mean duration of headache was  $41.1 \pm 77.4$  months (range 1 week to 240 months). Pain was located in the forehead area in five cases, temporal area in one case, parietal area in one case, and occipital area in one case. The frequency of pain was daily in six cases and several times a week in the remaining two cases. Five patients (62.5%) also had asthma. Six of the eight patients (75%) showed changes in headache symptoms after preoperative steroid therapy. Full house ESS was performed in all eight patients, and all the paranasal sinuses were opened. Posterior nasal neurectomy was performed in two cases. Headache resolved or diminished after surgery in all eight patients. The follow-up period after surgery was  $29.3 \pm 5.95$  months (range 24-39 months). The mean interval from surgery to resolution of headache was  $11.1 \pm 7.8$  days (range 3 to 30 days).

Case	Age	Sex	Symptom duration (month)	Pain area	Frequency of pain	Changes in headache caused by oral steroids	Surgical method	Postoperative observation period(month)	Pain disappearance time after surgery(day)
1	52	Female	240	Forehead	Several times a week	Improved	ESS,S,IT PNN	39	28
2	51	Female	6	Forehead	Several times a week	Improved	ESS,S,IT	39	14
3	46	Male	2	Forehead	Every day	No change	ESS,S,IT PNN	27	14
4	43	Female	3	Forehead	Every day	Improved	ESS	24	7
5	21	Male	0.25	Top of the head	Every day	Improved	ESS,S	24	3
6	58	Male	12	Back of the head	Every day	No change	ESS,S,IT	27	6
7	36	Female	60	Forehead	Every day	Improved	ESS,S,IT	24	3
8	51	Female	6	Temporal head	Every day	Improved	ESS,S,IT	30	14

ESS: Endoscopic Sinus Surgery; S: Septoplasty; IT: Inferior Turbinectomy; PNN: Posterior Nasal Neurectomy

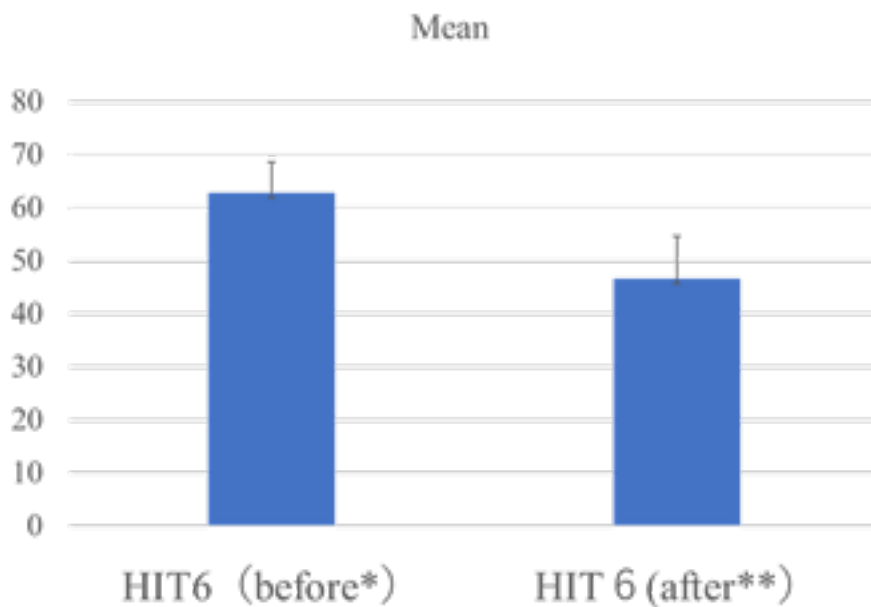
**Table 1:** Clinical features of the ECRS group with severe headache.

In one of the eight patients, headache recurred one year after surgery. The headache disappeared after performance of an Endoscopic Modified Lothrop Procedure (EMLP) to convert the frontal sinus into a single sinus. This patient did not develop further recurrence of headache 24 months after surgery. Comparison of mean HIT-6 scores in group S before and 2 years after surgery is shown in Table 2 and Figure 1. The mean preoperative HIT-6 score was  $62.9 \pm 5.7$ , while the postoperative score was  $46.6 \pm 7.95$ , indicating a significant improvement ( $P = 0.012$ ).

Case	HIT6*(before)	HIT6(after)	P value Wilcoxon rank sum test
1	64	50	
2	66	54	
3	58	46	
4	74	61	
5	66	38	
6	59	40	
7	62	36	
8	54	48	
Average	62.875	46.625	0.012
Standard deviation	± 5.73	± 7.95	

\*HIT6: Headache Impact Test-6

**Table 2:** Evaluation of headache scores before and after surgery in the ECRS group with severe headache.



\*HIT6: Headache Impact Test-6

**Figure 1:** Evaluation of headache scores before and after surgery in the ECRS group with severe headache.

### Comparison of Clinical Findings Between the Three ECRS Groups

A comparative study of age, gender, presence or absence of allergic rhinitis, presence or absence of asthma, blood eosinophil count, and eosinophil count in polyps in the patients in the three groups are shown in Table 3. Statistical analyses indicated no significant differences between the three groups for the six items evaluated. Among the 22 patients with headache complaints, the surgical improvement rate was 91% (20 patients). The results of comparison of Lund-Mackay's CT image score, antero-posterior diameter of the frontal sinus, location of the anterior ethmoidal nerve tract, and presence of nasal mucosal contact points, performed to investigate the cause of headache in the three groups, are shown in Table 4. Lund-Mackay CT image scores were 18±4.9 (group S), 17.64±5.87

(group M), and 18.9±5.0 (group N), with no significant differences between the three groups. There were no significant differences in the location of the anterior ethmoidal artery (2/2-3/3) between the three groups: group S (2/5/1), group M (3/7/4), and group N (1/10/7), respectively. There were no significant differences in the number of cases with nasal mucosal contact points between the three groups: seven (87.5%) in group S, eight (57.1%) in group M, and 11 (61.1%) in group N. The anteroposterior diameter of the frontal sinus (mm) was 8.1±3.4 in group S, 21.6±38.9 in group M, and 11.7±2.9 in group N, indicating a significant difference between the S and M groups and the S and N groups.

	Strong headache group(n=8)	Mild headache group(n=14)	No headache group(n=18)	Superiority difference between 3 groups by Steel-Dwass method
Age (yr), mean ± SD	44.75 ± 10.9	56.14 ± 11.23	51.47 ± 15.29	No significant difference
Sex (Male Female)	(5 3)	(8 6)	(11 7)	No significant difference
With AR(%)	7(87.5%)	8(57.1%)	11 (61.1%)	No significant difference
With asthma(%)	7(87.5%)	8(57.1%)	13(72.2%)	No significant difference
Blood eosinophil percentage (%)	9.93 ± 4.62	12.27 ± 14.18	10.33 ± 6.1	No significant difference
Tissue eosinophil count/HPF	100.4 ± 37.9	179.3 ± 324.2	98.5 ± 56.5	No significant difference

SD: Standard Deviation; AR: Allergic Rhinitis; HPF: High Power Field

**Table 3:** Demographic and clinical characteristics of the three ECRS groups.

	Strong headache group	Mild headache group	No headache group	Superiority difference between 3 groups by Steel-Dwass method
The Lund and Mackey CT Score	18 ± 4.9	17.64 ± 5.87	18.9 ± 5.0	No significant difference
the location of AENC+(2/2-3/3)	(2 5 1)	(3 7 4)	(1 10 7)	No significant difference
A-P diameter of FS <sup>++</sup> (mm)	8.11 ± 3.42	21.59 ± 38.85	11.73 ± 2.90	* ** significant difference
With nasal mucosa contact point(%)	7(87.5%)	8(57.1%)	11 (61.1%)	No significant difference

+:Running site of the canopy of the ethmoid sinus of the anterior ethmoidal nerve canal (AENC) (2:the second basal lamella, 2-3:between the second to third basal lamella, 3:The middle turbinate's basal lamella),

++: Anterior-posterior diameter of the nasal frontal canal

**Table 4:** Comparison of study items on sinus CT images between the three ECRS groups.

### Comparison of nasal symptom questionnaire scores before and two years after surgery in the three ECRS groups

Table 5 shows a comparison of NSQ scores in the three ECRS groups before and 2 years after surgery. Headache improved significantly following ESS in groups S and M. In group N, there were no complaints of headache before surgery, and no new cases of headache appeared after surgery. In addition, the three groups showed a significant improvement in their other symptoms (rhinorrhea, posterior rhinorrhea, olfactory disturbance, sleep disturbance, and mood disturbance) after surgery ( $P < 0.05$ ), with only sleep disturbance in group S showing no significant improvement ( $P > 0.05$ ). The improvement rates after surgery by symptom in all 40 patients in the three ECRS groups were as follows: headache (97.5%), nasal obstruction (95%), posterior rhinorrhea (87.5%), olfactory disturbances (97.5%), sleep disturbances (90%), and mood disturbances (95%).

	S group <sup>+</sup> (n=8)	M group <sup>++</sup> (n=14)	N group <sup>+++</sup> (n=18)
Headache (before*)	5.13 ± 1.05	2.07 ± 0.78	0
Headache (after**)	1.25 ± 0.83	0.5 ± 0.63	0
P Value	0.012	0.0015	-
Nasal obstruction(before)	4.38 ± 1.8	4.5 ± 2.06	4.22 ± 1.44
Nasal obstruction(after)	0.63 ± 1.11	0.71 ± 0.88	1.06 ± 1.08
P Value	0.021	0.0015	0.00029
Posterior rhinorrhea(before)	3.75 ± 2.11	3.36 ± 2.16	3.41 ± 1.96
Posterior rhinorrhea(after)	1.13 ± 0.93	0.57 ± 0.9	1.72 ± 1.76
P Value	0.0346	0.0022	0.0029
Olfactory disturbances(before)	4.5 ± 2.12	3.92 ± 2.43	4.33 ± 2.19
Olfactory disturbances(after)	1 ± 1.32	1.07 ± 1.39	1.89 ± 1.88
P Value	0.018	0.00335	0.0076
Sleep disturbances(before)	2.75 ± 2.22	2.96 ± 1.52	1.56 ± 1.38
Sleep disturbances(after)	0.75 ± 1.09	0.29 ± 0.59	0.33 ± 0.58
P Value	0.059	0.0029	0.00335
Mood disturbances(before)	2.5 ± 2.55	1.61 ± 1.51	0.89 ± 1.24
Mood disturbances(after)	0.13 ± 0.33	0.21 ± 0.56	0.39 ± 1.01
P Value	0.043	0.0087	0.018

\*before: before surgery, \*\*after: after surgery; +S group: Strong headache group, ++M group: Mild headache group, +++N group: No headache group

**Table 5:** Comparison of nasal symptom questionnaire item scores before and after surgery in the three ECRS groups

## Discussion

ECRS is considered a refractory disease. Eosinophil accumulation and degradation, cytokine release, and mucus secretion play an important role in the pathogenesis of ECRS. Patients with ECRS present with thick mucus secretion, prolonged nasal obstruction, loss of sense of smell, and intermittent acute exacerbations due to bacterial infection, all of which severely impair the patients' quality of life. However, there are very few reports of cases in which headache was the primary symptom of ECRS, or reports of the relationship between ECRS and headache.

Amal et al. reported headache in 24 of 59 (40.7%) patients with CRSwNP who underwent surgery. They also found a predominance of headache in the ECRS group (46.1%) compared to the No ECRS group (35.5%) [21]. The incidence of headache in our ECRS group was 55%, which is very similar to that reported by Amal et al. In this study, the characteristics of the headache in group S were very similar to those of migraine headaches. In other words, frontal headaches were common (62.5%), and most patients (75%) had headaches almost every day. In fact, most of the patients had symptoms that could be described as chronic migraine. Chronic migraine is a migraine headache that initially has no aura, and after a certain period of time, as the frequency of headaches increase, the

typical migraine features such as “throbbing headache,” “light and sound sensitivity,” and “nausea and vomiting” disappear, and the headache turns into a persistent and lingering headache, similar to a tension-type headache [22].

Chandrashekarappa et al. performed ESS on 100 patients with sinusitis who had chronic headache, excluding those diagnosed with migraine, and evaluated subjective symptoms before and after surgery. They concluded that these patients had vascular headache, because 20% of them had no improvement in headache after surgery [23]. In our ECRS case series, 20% of the patients had persistent, severe migraine-like symptoms. All of these patients had improvement in headache after surgery. Lien et al. followed 47 CRSwNP patients for 12 years after ESS. Before surgery, 18.9% of the patients complained of severe headache. When moderate headaches were included, 40.5% of the patients had headaches. Including mild headache, 62.1% of the patients had headache (24). Although the present study group of patients had ECRS, which is not exactly the same condition as CRSwNP, 20% of the patients had severe headache and 55% of the patients complained of some degree of headache, which is similar to the incidence reported by Lien et al. They also reported that the proportion of patients with severe headache decreased to 8.0% within 6 years after surgery and to 2.6% after 12 years [24]. In our patient group, headache did not improve in 9% of patients at 2 years after ESS. However, it is possible that the proportion of patients complaining of headache will decrease over time.

Steroids regulate nasal polyp mucosal remodeling by promoting epithelial repair, modulating tissue remodeling markers, increasing total collagen content, reducing tissue eosinophil infiltration [25], improving nasal symptoms and airflow, and reducing polyp size [26]. Oral steroids, in particular, are expected to have an immediate effect in relieving symptoms such as nasal obstruction, posterior rhinorrhea, and olfactory disturbances. In our study, six of the eight patients in group S experienced headache relief with oral steroids. This suggests that preoperative steroid therapy might help to determine whether the headache is due to ECRS or other causes. At the very least, the headache in sinusitis cases that are relieved by oral steroids can be considered to be due to ECRS. The response to surgery might also help to determine whether the headache is due to ECRS. Apart from headache, ECRS often presents with strong nasal obstruction due to nasal polyp formation and nasal mucosa-to-mucosa contact associated with nasal septal deviation, etc., as was seen in seven cases (87.5%) in group S in this study. Vascular headache and CRS are conditions with similar symptoms and are prevalent in similar patient populations [27,28]. Both conditions are accompanied by headache, facial pain, nasal symptoms, and environmental changes [1,29,30]. They can, however, be confused with migraine headaches, which involve activation of the trigeminal nerve, which innervates both the sinuses and the meninges. Rhinitis

and CRS can increase migraine-related morbidity by stimulation of trigeminal receptors, leading to a 9-fold increase in migraine frequency [31,32]. In addition, nasal obstruction has been identified as a factor that enhances headache [23]. In migraine, activation of the trigeminal vasculature causes a release of substance P (SP), Calcitonin Gene-Related Peptide (CGRP), and other neuropeptides that cause vasodilation of the nasal cavity, resulting in nasal congestion and hypersecretion. In addition, the release of neuropeptides causes mast cell degranulation and the release of other proinflammatory substances. As a result, migraine attacks can present with symptoms such as pressure on the face, runny nose, nasal obstruction, sinusitis, nasal tearing, and itching [33].

Pain occurs when nasal mucosal surfaces come into contact with each other [34]. Although nasal polyps do not have nerves, in ECRS patients with significant nasal polyp formation, nasal polyps might cause nasal mucosal contact by compression of the middle turbinate. In fact, the entire nasal cavity becomes edematous and narrowed in ECRS, and contact between the nasal membranes is very common. In ECRS patients with a predisposition to migraine headaches, the vasodilating effect of trigeminal nerve stimulation might synergistically increase swelling of the nasal mucosa, which might result in very severe headaches due to nasal mucosal contact. In terms of the timing of postoperative headache resolution in group S, all patients had headache resolution within 1 month; half of the patients had resolution of symptoms within 1 week. Few reports have investigated the timing of postoperative headache resolution, with most studies evaluating it at 1 year after surgery. Wang et al. reported that most patients in the CRSwPOLYP and CRSsPOLYP groups had improvement in all symptoms except olfactory disturbance within 1 week after ESS surgery, although there was no significant difference between the two groups [35]. Oral steroids are often used for about 2 months after surgery with gradual tapering of the dose. However, it is possible that this headache relief at 1-2 weeks after surgery could be related to the fact that the intranasal hemostatic gauze and sponges are removed and swelling of the nasal sinus cavities decreases at this time.

Chandrashekarappa et al. performed ESS surgery on 100 CRS patients with headache and reported that 80% of the patients had improvement in headache. However, they reported that there was no significant difference in headache assessed by the Visual Analogue Scale before and after surgery [23]. In our study, the headache improvement rate after surgery was 100% in group S and 91% in the combined S+M group. Additionally, there was a significant difference ( $P<0.05$ ) in HIT-6 scores in group S between before and after surgery. On the HIT-6, a score of 56 or higher indicates a headache that affects daily life. However, since most patients in group S in our study had scores of 56 or higher, this might have led to the relatively greater difference between the severity of headache before and after surgery. We also compared demographic and clinical findings between the three ECRS groups

in this study. Evaluation showed that the patients in group S were slightly younger than in the other groups, the proportion of males tended to be slightly higher than that of females in all three groups, the prevalence of allergic rhinitis and asthma tended to be higher in group S, and eosinophils in blood and tissues tended to be higher in group M, although with no significant differences between the three groups in any of these characteristics. In addition, to investigate the factors contributing to the severity of headache, a comparison of sinus CT findings among the three groups was conducted. The Lund and Mackey CT Score was high in all groups, at around 18, with no significant differences between the three groups. The anterior ethmoidal nerve canal was mostly located between the second and third basal lamellas in all cases, with no significant differences between the three groups.

The anterior ethmoidal nerve runs with the anterior ethmoidal artery in the anterior ethmoidal neural tube. The anterior ethmoidal nerve is a branch of the first trigeminal nerve, and sinus headaches caused by irritation of the anterior ethmoidal nerve are known as the anterior ethmoidal nerve syndrome [36]. Although we assumed that the anterior ethmoidal nerve probably traveled along the second basal lamella near the foramen of the frontal sinus in more cases in group S, we found no significant difference between the three groups, and there seemed to be no association between the anatomical site of the anterior ethmoidal nerve and headache.

The presence of nasal mucosal contact tended to be higher in subjects in group S (87.5%), although there was no significant difference between the three groups. Comparison indicated that the anteroposterior diameter of the frontal sinus was significantly shorter in group S than groups M and N. In addition, a case of recurrent headache in group S was treated with a Modified Endoscopic Lothrop Procedure (MELP), in which the bilateral frontal sinuses were converted to a single sinus, resulting in improvement of the headache. Takeno et al. suggested that strong eosinophilic infiltration of the frontal sinus mucosa is observed in ECRS. They also examined the expression of eosinophil-related cytokines in the nasal sinus mucosa and reported that the frontal sinuses of patients with eosinophilic sinusitis have a similar profile as the ethmoid sinus mucosa, with increased expression of cytokines such as IL-5 [37]. In ECRS, the frontal sinus shows a high degree of eosinophilic infiltration and inflammation, and the foramen of the frontal sinus is anatomically very narrow. Thus, ECRS patients with a short antero-posterior diameter of the frontal sinus might experience severe headache, as was seen in the group S subjects in this study. In this study, we evaluated six symptoms affecting daily life in ECRS cases using the NSQ. The evaluation was performed after a relatively long interval of 2 years after surgery. The results showed improvement in all six symptoms in each group. Among them, group N, which did not have any symptoms of headache before surgery, had no new occurrence of surgery after headache either. Improvements in sleep and mood

disorders were seen in group S, but were not significant ( $P > 0.05$ ). The overall improvement rate of the six major symptoms in all the ECRS cases was 85% or more in our study, which was similar to the improvement rate of life after surgery of 85% reported by Damm et al. [38]. Our study and previous reports thus show that ESS and nasal septoplasty are very useful for improving not only headache, but also other symptoms in ECRS cases. Lien et al. followed 47 CRSw polyp cases who underwent ESS for 12 years, showing significant improvement in nasal congestion ( $P > 0.01$ ) and olfactory dysfunction ( $P > 0.001$ ), as well as headache and runny nose [24]. They stated that these effects were not only due to the modified surgery, which was performed in 36.8% of the patients, but also due to postoperative treatment according to EPOS guidelines, including saline nasal rinses, steroid nasal sprays, and treatment with antibiotics or oral steroids for acute exacerbations of ECRS, such as the appearance of purulent nasal discharge.

Our results and those of previous studies show that ESS is an effective method for the treatment of headache and other symptoms of ECRS. However, since ECRS has a high recurrence rate, postoperative follow-up and treatment are very important for maintenance of the efficacy of the surgery. If symptoms recur, it is necessary to consider revision surgery or administration of drugs such as monoclonal antibodies.

## Conclusion

Our study showed that ESS is an effective procedure for treating the symptoms of ECRS, including headache, although postoperative follow-up and postoperative treatment, such as with nasal irrigation and nasal steroid drops, are very important for maintaining the effect of surgery. Our results also showed that cases with a short antero-posterior diameter of the frontal sinus are more likely to have severe headache. Additionally, the response to preoperative oral steroids might be effective in determining whether the cause of the headache is ECRS or some other etiology.

## References

1. Headache Classification Committee of the International Headache Society (IHS) (2013) The International Classification of Headache Disorders: 3rd edition. *Cephalalgia* 33: 629-808.
2. Benninger MS, Ferguson BJ, Hadley JA, Hamilos DL, Jacobs M, et al. (2003) Adult chronic rhinosinusitis: definitions, diagnosis, epidemiology, and pathophysiology. *Otolaryngol Head Neck Surg* 129: S1-32.
3. Fokkens WJ, Lund VJ, Mullol J, Bachert C, Alobid I, et al. (2012) EPOS 2012: European position paper on rhinosinusitis and nasal polyps 2012. A summary for otorhinolaryngologists. *Rhinology* 50: 1-12.
4. Fokkens W, Lund V, Mullol J, European Position Paper on Rhinosinusitis and Nasal Polyps Group (2007) European position paper on rhinosinusitis and nasal polyps 2007. *Rhinol Suppl* 20: 1-136.
5. Fokkens WJ, Lund VJ, Mullol J, Bachert C, Alobid I, et al. (2012) European position paper on rhinosinusitis and nasal polyps 2012. *Rhinol Suppl* 23:3 p preceding table of contents 1-298.



6. Ouyang Y, Fan E, Li Y, Wang X, Zhang L (2013) Clinical characteristics and expression of thymic stromal lymphopoietin in eosinophilic and non-eosinophilic chronic rhinosinusitis. *ORL J Otorhinolaryngol Relat Spec* 75: 37-45.
7. Sakuma Y, Ishitoya J, Komatsu M, Shiono O, Hiramasa M, et al. (2011) New clinical diagnostic criteria for eosinophilic chronic rhinosinusitis. *Auris Nasus Larynx* 38: 583-588.
8. Ishitoya J, Sakuma Y, Tsukuda M (2010) Eosinophilic chronic rhinosinusitis in Japan. *Allergol Int* 59: 239-245.
9. Snidvongs K, Chin D, Sacks R, Earls P, Harvey RJ (2013) Eosinophilic rhinosinusitis is not a disease of ostiomeatal occlusion. *Laryngoscope* 123: 1070-1074.
10. Kountakis SE, Arango P, Bradley D, Wade ZK, Borish L (2004) Molecular and cellular staging for the severity of chronic rhinosinusitis. *Laryngoscope* 114: 1895-1905.
11. Ferguson BJ (2004) Categorization of eosinophilic chronic rhinosinusitis. *Curr Opin Otolaryngol Head Neck Surg* 12: 237-242.
12. Soler ZM, Sauer DA, Mace J, Smith TL (2009) Relationship between clinical measures and histopathologic findings in chronic rhinosinusitis. *Otolaryngol Head Neck Surg* 141: 454-461.
13. Haruna S, Shimada C, Ozawa M, Fukami S, Moriyama H (2009) A study of poor responders for long-term, low-dose macrolide administration for chronic sinusitis. *Rhinology* 47: 66-71.
14. Soler ZM, Sauer D, Mace J, Smith TL (2010) Impact of mucosal eosinophilia and nasal polyposis on quality-of-life outcomes after sinus surgery. *Otolaryngol Head Neck Surg* 142: 64-71.
15. Kimura N, Nishioka K, Nishizaki K, Ogawa T, Naitou Y, et al. (1997) Clinical effect of low-dose, long-term roxithromycin chemotherapy in patients with chronic sinusitis. *Acta Med Okayama* 51: 33-37.
16. Soler ZM, Mace J, Smith TL (2008) Symptom-based presentation of chronic rhinosinusitis and symptom-specific outcomes after endoscopic sinus surgery. *Am J Rhinol* 22: 297-301.
17. Tokunaga T, Sakashita M, Haruna T, Asaka D, Takeno S, et al. (2015) Novel scoring system and algorithm for classifying chronic rhinosinusitis: the JESREC Study. *Allergy* 70: 995-1003.
18. Kosinski M, Bayliss MS, Bjorner JB, Ware JE, Jr, Garber WH, et al. (2003) A six-item short-form survey for measuring headache impact: the HIT-6. *Qual Life Res* 12: 963-974.
19. Lund VJ, Mackay IS (1993) Staging in rhinosinusitis. *Rhinology* 107: 183-184.
20. Yoshida T, Kojima J, Mori E, Iimura J, Shigeta Y, et al. (2010) About the subjective symptoms and QOL improvement after endoscopic operation. *Oto-Rhino-Laryngology, Tokyo* 53: 293-299.
21. Abdulla A, Faisal AI, Darwish A, Bella MH (2017) Chronic eosinophilic rhinosinusitis clinical implications. *Bahrain Medical Bulletin* 39: 92-95.
22. Yalin OÖ, Uluduz D, Özge A, Sungur MA, Selekler M, Siva A (2016) Phenotypic features of chronic migraine. *J Headache Pain* 17: 26.
23. Chandrashekarappa S, Shetty S, Shetty TS, Khan A, Joshi P (2017) Impact of co-existing vascular headache on symptom relief after endoscopic sinus surgery. *Indian J Otolaryngol Head Neck Surg* 69: 221-224.
24. Calus L, Van Bruaene N, Bosteels C, Dejonckheere S, Van Zele T, Holtappels G, et al. (2019) Twelve-year follow-up study after endoscopic sinus surgery in patients with chronic rhinosinusitis with nasal polyposis. *Clin Transl Allergy* 9: 30.
25. de Borja Callejas F, Martínez-Antón A, Picado C, Alobid I, Pujols L, Valero A, et al. (2015) Corticosteroid treatment regulates mucosal remodeling in chronic rhinosinusitis with nasal polyps. *Laryngoscope* 125: E158-167.
26. Alobid I, Mullol J (2012) Role of medical therapy in the management of nasal polyps. *Curr Allergy Asthma Rep* 12: 144-153.
27. Schramm SH, Obermann M, Katsarava Z, Diener HC, Moebus S, Yoon MS (2013) Epidemiological profiles of patients with chronic migraine and chronic tension-type headache. *J Headache Pain* 14: 40.
28. Smith TL, Litvack JR, Hwang PH, et al. (2010) Determinants of outcomes of sinus surgery: a multi-institutional prospective cohort study. *Otolaryngol Head Neck Surg* 142: 55-63.
29. Rosenfeld RM, Andes D, Bhattacharyya N, Cheung D, Eisenberg S, et al. (2007) Clinical practice guideline: adult sinusitis. *Otolaryngol Head Neck Surg* 137: S1-S31.
30. DeConde AS, Mace JC, Smith TL (2014) The impact of comorbid migraine on quality-of-life outcomes after endoscopic sinus surgery. *Laryngoscope* 124: 1750-1755.
31. Aaseth K, Grande RB, Kvaerner K, Lundqvist C, Russell MB (2010) Chronic rhinosinusitis gives a ninefold increased risk of chronic headache. The Akershus study of chronic headache. *Cephalalgia* 30: 152-160.
32. Martin VT, Fanning KM, Serrano D, et al. (2014) Chronic rhinitis and its association with headache frequency and disability in persons with migraine: results of the American Migraine Prevalence and Prevention (AMPP) Study. *Cephalalgia* 34: 336-348.
33. Dalessio DJ. *Wolff's headache and other head pain* (1972) New York: Oxford University Press 3rd ed.
34. Abu-Bakra M, Jones NS (2001) Prevalence of nasal mucosal contact points in patients with facial pain compared with patients without facial pain. *J Laryngol Otol* 115: 629-632.
35. Wang ET, Zheng Y, Liu PF, Guo LJ (2014) Eosinophilic chronic rhinosinusitis in East Asians. *World J Clin Cases* 2: 873-882.
36. Shalom, AS (1963) The Anterior Ethmoid Nerve Syndrome. *The Journal of Laryngology & Otology* 77: 315-325.
37. Takeno S, Kubota K (2015) Frontal sinus disease in eosinophilic chronic rhinosinusitis. *Journal of Japan Society of Immunology & Allergology in Otolaryngology* 33: 221-224.
38. Damm M, Quante G, Jungehuelsing M, Stennert E (2002) Impact of functional endoscopic sinus surgery on symptoms and quality of life in chronic rhinosinusitis. *Laryngoscope* 112: 310-315.