



# The Role of Cognitive Targeted Biopsy in the Diagnosis of Early Prostate Cancer

**Olukayode A. Oseni<sup>1</sup>, Kehinde H. Tijani<sup>1</sup>, Moses A. Ogunjimi<sup>1</sup>, Adekunle A. Adeyomoye<sup>2</sup>, Charles C. Anunobi<sup>3</sup>, Emmanuel A. Jeje<sup>1</sup>, Rufus W. Ojewola<sup>1</sup>, Emmanuel A. Animashaun<sup>1</sup>, Abraham T. Oladimeji<sup>4</sup>**

<sup>1</sup>Department of Surgery, Lagos University Teaching Hospital, Lagos, Nigeria

<sup>2</sup>Radiodiagnosis Department, Lagos University Teaching Hospital, Lagos, Nigeria

<sup>3</sup>Anatomic and Molecular Medicine Department, Lagos University Teaching Hospital, Lagos, Nigeria

<sup>4</sup>Department of Surgery, Federal Medical Centre, Ebute Metta, Lagos, Nigeria

\*Corresponding author: Olukayode A. Oseni, Department of Surgery, Lagos University Teaching Hospital, Lagos, Nigeria

**Citation:** Oseni OA, Tijani KH, Ogunjimi MA, Adeyomoye AA, Anunobi CC, et al. (2025) The Role of Cognitive Targeted Biopsy in the Diagnosis of Early Prostate Cancer. J Surg 10: 11246 DOI: 10.29011/2575-9760.011246

**Received Date:** 17 January 2025; **Accepted Date:** 22 January 2025; **Published Date:** 24 January 2025

## Abstract

**Introduction:** Prostate cancer is the second most common cancer in men worldwide. Prostate cancer screening protocols includes the use of serum prostate specific antigen assay and digital rectal examination. Diagnosis of prostate cancer is usually confirmed through histopathologic examination of prostate biopsy specimen. Transrectal ultrasound guided prostate biopsy is currently the procedure of choice. MRI-guided prostate biopsy (MRGB) improves the quality of a biopsy after a diagnostic MRI; it is now becoming the new gold standard. Cognitive targeted prostate biopsy is one of the modalities of MRI-guided prostate biopsy. This study aims to determine the predictive value of cognitive targeted prostate biopsy using multiparametric magnetic resonance imaging findings in the diagnosis of prostate cancer.

**Materials and Methods:** This was a prospective observational cross-sectional study involving patients undergoing evaluation for prostate cancer. All participants underwent clinical evaluation including Digital Rectal Examination (DRE), serum Prostate Specific Antigen (PSA) assay and ultrasonography of the prostate. Those who met the indication for prostate biopsy underwent a pre-biopsy multiparametric magnetic resonance imaging (mp-MRI); to detect any suspicious lesions using Prostate Imaging Reporting And Data System (PIRADS) score. Subsequently, a cognitive targeted Trans Rectal Ultrasound (TRUS)-guided prostate biopsy was done by targeting any suspicious areas that are present; subsequently systematic TRUS-guided biopsy was carried out. Patients with negative findings on mp-MRI had only the systematic TRUS-guided biopsy done. Data was analysed using Statistical Package for the Social Sciences Version 22.0. Diagnostic efficacy of cognitive targeted prostate biopsy and transrectal ultrasound scan guided prostate biopsy were analysed ( $p < 0.05$ ).

**Results:** Fifty (50) patients (age range – 51 – 83 years) were enrolled in the study. Of the 50 patients, 32 had histological diagnosis of prostate cancer with mean age of 65.72 years. The sensitivity, specificity, PPV, NPV, accuracy and cancer detection rate of transrectal ultrasound systematic prostate biopsy were 10.81%, 99.75%, 85.71%, 88.83%, 88.78% and 16% respectively. The sensitivity, specificity, Positive Predictive Value (PPV), Negative Predictive Value (NPV), accuracy and cancer detection rate of cognitive targeted prostate biopsy as determined by multiparametric magnetic resonance imaging were 86.49%, 98.48%, 88.89%, 98.11%, 97.00% and 64% respectively.

**Conclusion:** Multiparametric magnetic resonance imaging with cognitive targeted prostate biopsy is more accurate and detected a greater percentage of patients with clinically significant prostate cancer as compared to systematic prostate biopsy with transrectal ultrasound alone. There is a positive correlation between PIRADS score and cancer detection rate.

**Keywords:** Cognitive Targeted Prostate Biopsy; Multiparametric MRI; Prostate Cancer; Prostate Needle Biopsy; Suspicious Lesions; Systematic Prostate Biopsy

## Introduction

Prostate cancer is the second most common cancer in men worldwide and the fifth most common cause of cancer death in men [1]. The late 1980s saw an increased incidence of prostate cancer because of the introduction of Prostate Specific Antigen (PSA) as a screening tool. Prostate cancer incidence increases as men age; as many as 60% of men over 65 years of age may be diagnosed with prostate cancer [2]. It is however commonly diagnosed in men aged 65 – 74 years with the median age at diagnosis being 66 years [3]. Screening for prostate cancer is still a controversial topic. Serum PSA and Digital Rectal Examination (DRE) are currently being used as screening tools. Trans Rectal Ultrasound (TRUS)-guided biopsy is performed to confirm diagnosis following abnormal finding(s) from the screening modalities. Screening for prostate cancer is not without its limitation despite a reduction in cancer related mortality that has been observed. The risk of over-diagnosis of clinical insignificant cancers remains worrisome and significant. A clinically significant cancer is defined via imaging or histology as a tumour with a volume greater than 0.5cm<sup>3</sup> or a Gleason score of greater or equals to seven/ 6mm in length respectively [4]. Newer techniques are being developed to improve detection of clinically significant cancer and concurrently reducing detection of insignificant tumours. Modalities that allow for better visualization of the suspicious lesions within the prostate may help in image guided prostate biopsy. These modalities include colour Doppler ultrasonography, elastography and MRI.

Magnetic Resonance Imaging (MRI) is a tool with growing importance in prostate cancer evaluation; the introduction of Multiparametric MRI (mp-MRI) has seen an increase in accuracy for localisation and detection of Prostate Cancer (Pca) [5-8]. Prostate MRI reporting is getting more structured by implementation and improvement of the Prostate Imaging Reporting and Data System (PI-RADS) [9,10]. The increased use of diagnostic prostate MRI is resulting in an increased demand for targeted prostate biopsies. Studies show that MRI-Guided Prostate Biopsy (MRGB) improves the quality of a biopsy after a diagnostic MRI and is now becoming the new gold standard [11,12]. MRGB is however not readily available in many centres; for this reason, other targeted biopsy techniques are necessary. A clinical method for targeted prostate biopsy is the targeted TRUS-guided biopsy of Clinical Suspicious

Lesions (CSL) on prostate MRI also known as Cognitive Targeted Biopsy (CTB) or visually- registered targeted biopsy. Recent studies show promising results for cognitive targeting of CSL [13,14]. In this study, after appropriate selection of patients, mp-MRI and CTB was done subsequently; biopsy outcomes of CTB and TRUS-GB was compared and analysed.

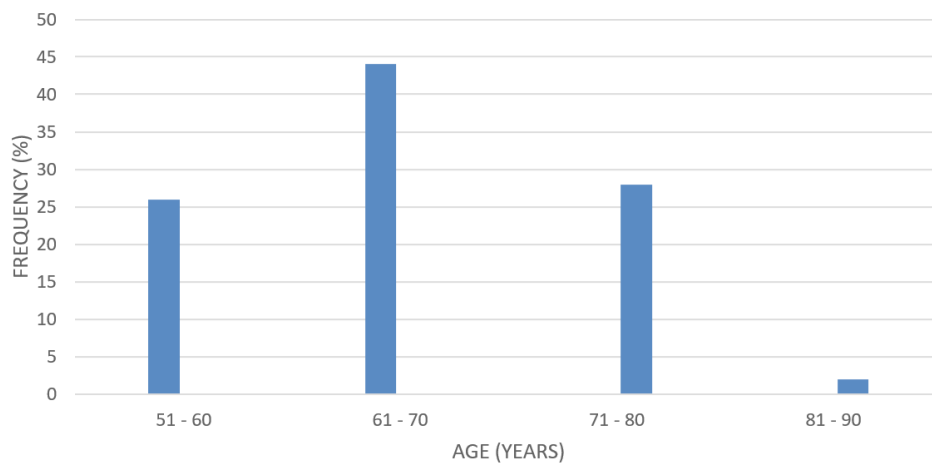
## Materials and Methods

The study was prospectively conducted in the urology unit of the Lagos University Teaching Hospital (LUTH) between November 2022 to December 2023. The sample size was estimated to be 43 (at attrition rate of 40%) using Cochran's formula. All male patients who presented for evaluation of their prostatic diseases had DRE and serum PSA assay performed on them. The study protocol was approved by the Lagos University Teaching Hospital Human Research and Ethics Committee (LUTHHREC). Inclusion criteria were the presence of elevated PSA (>4ng/ml) or abnormal prostatic findings on DRE and ultrasonography. Patients with clinical and radiologic features of advanced malignant disease of the prostate were excluded. Fifty patients met the inclusion criteria and gave consent to participate in the study. All the subjects were sent for multiparametric MRI of the prostate (mp-MRI) using a Toshiba Elan Vantage (eS Edition) with a magnetic strength of 1.5T. Suspicious areas (PIRADS 4 and PIRADS 5 lesions) and corresponding zones was noted following review of the MRI images. Each patient was worked up for TRUS-guided prostate biopsy using unit protocol of preparation viz; stoppage of anticoagulants and anti-platelets, administration of rectal suppository (bisacodyl 10mg) the night before the procedure and prophylactic intravenous antibiotics (levofloxacin 500mg stat + metronidazole 500mg stat) prior to the procedure. Patients were placed in lateral decubitus position; a preliminary DRE was done by the researcher and findings documented. About 10mls of 2% xylocaine gel was instilled intra-rectally for topical anaesthesia and lubrication 15 minutes before biopsy was commenced. TRUS of prostate was performed with a 7.5MHz trans rectal probe using a digital ultrasound scanner (S22; SonoScape Medical Corp, Guangdong, China). The prostate volume, presence of nodules and the presence of hyper-vascular areas was assessed and noted. A peri-prostatic nerve block was done using 5ml of 1% lidocaine injection to the apex and both sides of the prostate base. For patients with identified suspicious area on pre biopsy multiparametric MRI (PIRADS 4 & 5); the rectal probe was placed first at the suspicious area and biopsies were taken with the aid of an 18G core biopsy

needle mounted on a spring-loaded automated biopsy gun, systematic biopsy protocol was then carried out while also taking samples from suspicious areas on TRUS, to complete extended (18) cores. Patients with negative findings on mp-MRI had systematic biopsies of 18 cores, including sonographic suspicious areas. Each of the 18 core prostatic tissues was preserved with 10% buffered formalin in a separate universal bottle labelled and submitted to the pathology department for histopathologic analysis. Relevant information including demographic data, examination findings, indications for biopsy and results of histopathology were obtained using a pro forma. The data were analysed using Statistical Package for the Social Sciences (SPSS) version 23.0. The results are described in statistical indices (sensitivity, specificity, NPV, PPV and accuracy). For statistical analysis, a 2-tailed test, Chi-squared test, Receiver Operating Characteristic (ROC) curve and Pearson’s correlation coefficient were used with the  $P < 0.05$  considered as significant.

**Results**

A total of fifty (50) patients were studied with age range of 51 - 83 years and a mean age of  $65.90 \pm 7.56$  years; most patients (22 i.e. 44%) falling within the 61 - 70 years (Figure 1) bracket while only one patient was aged over 80 years(2%). Mean age of patients with benign prostatic hyperplasia is  $66.22 \pm 6.916$  years while the mean age of patients with adenocarcinoma of the prostate was  $65.72 \pm 8.005$  years



**Figure 1:** Age Distribution Of Patients Who Had Prostate Biopsy (N=50).

Forty-four (88%) of the fifty patients had Lower Urinary Tract Symptoms (LUTS) while the rest were asymptomatic. Duration of LUTS ranged from 6 months to 12 years. Only 30% of the patients were without comorbidities; 42% had only hypertension, 14% had diabetes only while 14% had both hypertension and diabetes. All the patients had benign findings on Digital Rectal Examination (DRE). Thirty two of the fifty patients (64%) had prostatic adenocarcinoma while eighteen patients (36%) had benign features on histology of the prostate. The range of the prostate-specific antigen (PSA) was from 0.97 – 20ng/ml. The mean PSA for patients diagnosed with benign prostatic hyperplasia and prostate cancer were  $9.8150 \pm 4.683$ ng/ml and  $14.2875 \pm 4.745$ ng/ml respectively (Table 1).

	HISTOLOGY	FREQUENCY OF HISTOLOGY	MEAN PSA	STANDARD DEVIATION	T	P VALUE
PSA	BENIGN	18	9.815	4.68336	3.214	0.002
	CAP	32	14.2875	4.7451		

**Table 1:** Mean Psa For Patients With Benign And Malignant Prostate Disease

Out of the thirty-two (32) patients who had prostate cancer, 19 (59.4%) had Gleason score of 7; making it the highest occurring Gleason score of the group (intermediate grade). Nine patients had Gleason score of 6 while three and one patient had Gleason score of 8 and 9 respectively. No patient had Gleason score of 10 (Table 2).

GLEASON SCORE	FREQUENCY(N)	PERCENTAGE (%)
6	9	28.1
7	19	59.4
8	3	9.4
9	1	3.1
<b>TOTAL</b>	<b>32</b>	<b>100</b>

**Table 2:** Distribution Of Gleason Score Of Patients With Prostate Cancer.

### Transrectal Ultrasonography in Prostate Cancer Detection

Out of the 900 prostatic zones and corresponding core biopsies (this obtained from prostate biopsy cores i.e. 18 cores per patient, where the total number of patients was 50); transrectal ultrasound identified 12 (1.3%) suspicious areas (Table 3) that were eventually histologically cancerous (true positives). Seven hundred and eighty seven (87.4%) zones had no sonographic features suggestive of possible malignancy and were found to be histologically benign (true negatives). Two (0.2%) prostatic zones had suspicious feature of malignancy but had no malignancy histologically (false positive) and 99 (11.0%) zones had no feature suggestive of malignancy sonographically but were discovered to be malignant histologically (false negative).

DIAGNOSTIC VARIABLES	FALSE NEGATIVE	FALSE POSITIVE	TRUE NEGATIVE	TRUE POSITIVE	TOTAL
FREQUENCY	99	2	787	12	900
PERCENT (%)	11	0.2	87.4	1.3	100

**Table 3 :** Transrectal Ultrasound Scan In Prostate Cancer Detection.

Even though the sensitivity of TRUS in the detection of prostate cancer was low, 10.81%; the specificity was 99.75%. Positive predictive value (PPV), negative predictive value (NPV) and accuracy of TRUS in prostate cancer detection were 85.71%, 88.83% and 88.78% respectively (Table 4).

	VALUE	95% CI
SENSITIVITY	10.81%	5.71% to 18.12%
SPECIFICITY	99.75%	99.09% to 99.97%
POSITIVE LIKELIHOOD RATIO	42.65	9.67 to 188.05
NEGATIVE LIKELIHOOD RATIO	0.89	0.84 to 0.95
DISEASE PREVALENCE	12.33%	12.26% to 14.66%
POSITIVE PREDICTIVE VALUE	85.71%	57.64% to 96.36%
NEGATIVE PREDICTIVE VALUE	88.83%	88.17% to 89.45%
ACCURACY	88.78%	86.53% to 90.77%
AREA UNDER CURVE (AUC)	0.547	

**Table 4:** Predictive Value Of Transrectal Ultrasonography Guided Biopsy In Prostate Cancer Detection.

Twenty-two patients with prostate malignancy had prostate imaging reporting and data system score (PIRADS) of 5; only 3 patients with PIRADS 5 lesions on MRI had benign features. None of the patients with PIRADS 1 – 3 lesions on MRI had malignant histology (Table 5).

PIRADS	BENIGN	MALIGNANT
1	1	0
2	10	0
3	2	0
4	2	10
5	3	22

**Table 4:** Pirads Score Distribution Of Patients.

The mean prostate imaging reporting and data system score (PIRADS) on multiparametric MRI of the prostate of patients who were found histologically to have prostate adenocarcinoma and benign features are 4.63 and 2.83 respectively (Table 6) ; which represents a positive correlation with histological outcome.

HISTOLOGY	FREQ.	MEAN	STD DEVIATION	T	P VALUE
BENIGN	18	2.83	1.249	6.662	0
PROSTATE CANCER	32	4.63	0.66		

**Table 6:** Mean Pirads Score For Benign And Malignant Disease.

### Multiparametric MRI of the prostate in prostate cancer detection

Ninety six (96) of the 900 prostatic zones had features suggestive of malignancy on MRI (PIRADS 4 & 5) and resulted in a histology of adenocarcinoma (true positive) while 777 prostatic zones had non-malignant feature with benign feature histologically (86.3%), true negative. False negative and false positive accounted for 15 and 12 prostatic zones respectively of the 900 zones (Table 7).

DIAGNOSTIC VARIABLES		FALSE NEGATIVE	FALSE POSITIVE	TRUE NEGATIVE	TRUE POSITIVE	TOTAL
MpMRI	FREQ	15	12	777	96	900
	PERCENT	1.7	1.3	86.3	10.7	100
TRUS	FREQ	99	2	787	12	900
	PERCENT	11	0.2	87.4	1.3	100

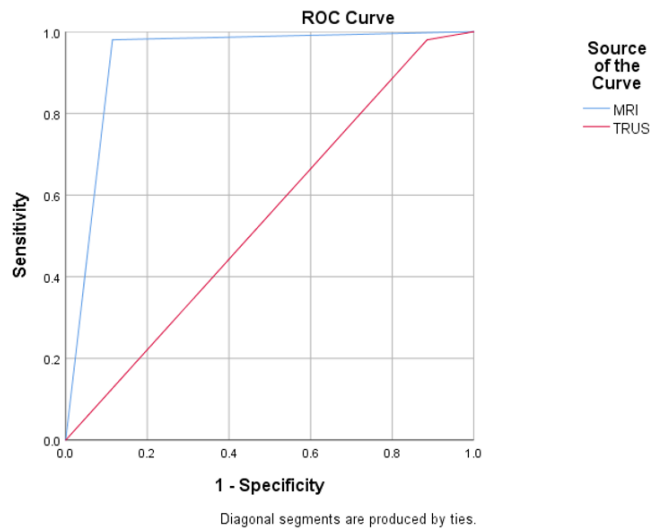
**Table 7:** Multiparametric Mri Versus Trus In Prostate Cancer Detection.

The sensitivity, specificity, positive predictive value, negative predictive value and accuracy of MRI in prostate adenocarcinoma detection were 86.49%, 98.48%, 88.89%, 98.11% and 97.00 respectively (Table 8).

	mpMRI	95% CI	TRUS	95%CI
SENSITIVITY	86.49%	78.69% - 92.23%	10.81%	5.71% - 18.12%
SPECIFICITY	98.48%	97.36% - 99.21%	99.75%	99.09% - 99.97%
POSITIVE LIKELIHOOD RATIO	56.86	32.28 - 100.18	42.65	9.67 – 188.05
NEGATIVE LIKELIHOOD RATIO	0.14	0.09 - 0.22	0.89	0.84 – 0.95
DISEASE PREVALENCE	12.33%	10.26% - 14.66%	12.33%	12.26% - 14.66%
POSITIVE PREDICTIVE VALUE	88.89%	81.95% - 93.37%	85.71%	57.64% - 96.36%
NEGATIVE PREDICTIVE VALUE	98.11%	97.00% - 98.81%	88.83%	88.17% - 89.45%
ACCURACY	97.00%	95.67% - 98.01%	88.78%	86.53% 90.77%
AUC	0.933		0.547	

**Table 8:** Predictive Value Of Mpmri Versus Trus In Prostate Cancer Detection.

Both transrectal ultrasound scan and multiparametric magnetic resonance imaging show a high strength in the ability to correctly determine the absence of prostate cancer. This translates to a comparable high specificity of 99.75% for TRUS and 98.48% for mMRI. However, the accuracy, sensitivity, PPV and NPV of mMRI which were 97.00%, 86.49%, 88.89% and 98.11% respectively; were higher than the corresponding value for TRUS which were; 88.78%, 10.81%, 85.71% and 88.83%. The area under the receiver operating characteristic (ROC) curve for mpMRI was 0.933 while it was 0.547 for TRUS. The mpMRI curve is closer to 1 which signifies a higher accuracy (Figure 2) (Table 9).



**Figure 2:** Area Under Curve Of Receiver Operating Characteristic Comparing Sensitivity And Specificity Of mpMRI AND TRUS.

Area Under the Curve					
Test Result Variable(s)	Area	Std. Error <sup>a</sup>	Asymptotic Sig. <sup>b</sup>	Asymptotic 95% Confidence Interval	
				Lower Bound	Upper Bound
MRI	0.933	0.019	0	0.895	0.97
TRUS	0.547	0.033	0.129	0.483	0.612
The test result variable(s): MRI, TRUS has at least one tie between the positive actual state group and the negative actual state group. Statistics may be biased.					
a. Under the nonparametric assumption					
b. Null hypothesis: true area = 0.5					

**Table 9:** Area Under Curve Of Receiver Operating Characteristic Comparing Sensitivity And Specificity Of Mpmri And Trus.

Out of the 32 patients with prostate cancer in this study, 10 had PIRADS 4 lesions while 22 had PIRADS 5 lesions; this gives an overall cancer detection rate for cognitive targeted biopsy to be 64%(32 of 50 patients). Only 8 patients had suspicious lesions for malignancy on TRUS that were prostate cancer on histology; corresponding to a cancer detection rate of 16% (8 of 50 patients); p-value of less than 0.0001(CDR of CTB compared to TRUS GB) Cancer detection rate (CDR) was observed to correlate positively with increasing PIRADS score (Table 10). Ten (10) of 12 patients with PIRADS 4 lesions had prostate cancer (CDR of 83.3%) while 22 of 25 patients with PIRADS 5 had prostate cancer (CDR of 88%).



PIRADS SCORE	BENIGN HISTOLOGY	MALIGNANT HISTOLOGY	TOTAL	CANCER DETECTION RATE (%)
1	1	0	1	0
2	10	0	10	0
3	2	0	2	0
4	2	10	12	83.3
5	3	22	25	88

**Table 10:** Cancer Detection Rates For Cognitive Targeted Biopsy And Systematic Trus-Guided Prostate Biopsy

## Discussion

Prostate cancer is the second most common cancer in men worldwide and the fifth most common cause of cancer death in men [1]. Screening for prostate cancer is still a controversial topic. Serum Prostate Specific Antigen (PSA) and Digital Rectal Examination (DRE) are currently being used as screening tools, newer techniques are also being developed to improve detection of clinically significant prostate cancer. The introduction of multiparametric magnetic resonance imaging has seen an increase in accuracy for localisation and detection of prostate cancer [5-8]. This study revealed the prevalent age for prostate cancer to be 51 – 83 years with a mean age of  $65.90 \pm 7.56$  years; this is comparable to various local and international studies. Ajape et al [15] in Ilorin, also found a mean age of presentation of  $68.4 \pm 10.1$ . In a community-based study by Ikuero et al [16] a lower mean age of presentation at 60.8 years was observed; this may be explained by the earlier diagnosis expected of a screening exercise that identified patients with prostate cancer without bothersome symptoms which would have prompted presentation to the hospital. Rawla et al [2] identified an increasing incidence of prostate cancer as men age; with 60% of men over age 65 years being at risk. Similarly, another study reported a median age of diagnosis of prostate cancer to be 66 years [3]. This age distribution and mean age confirm that age is a known risk factor in prostate cancer pathology. Digital rectal examination for all the patients with prostate cancer in this study revealed benign findings. Ojewola et al [17] however in a study that evaluated the usefulness of digital rectal examination in the diagnosis of prostate cancer in an unscreened population, reported a sensitivity, specificity and accuracy of 75.7%, 44.7% and 58% respectively; this may be due to the wider spectrum of patients seen ranging from early to advanced cases of prostate cancer compared to the predominantly early stage prostate cancer of patients in this study. The prostate specific antigen range of the patients in this study was from 0.97 – 20ng/ml; mean PSA for patients with prostate cancer being 14.2875ng/ml. This is similar to studies by Porpiglia et al [8] and Ahmed et al [19] who carried

out a similar study comparing systematic biopsy to MRGB of the prostate; both having a maximum PSA of 15. Up to 60 – 75% of prostate cancer have lower echogenicity on TRUS compared to surrounding tissue; [20] the main role of TRUS is however to provide guidance for prostate biopsy due to its low sensitivity and specificity for diagnosis of prostate cancer.

Like in most malignancies, angiogenesis is one of the key pathologic features in prostate cancer, this underscores the importance of the use of doppler ultrasound to detect tumour neovascularity which helps in predicting malignancy in the prostate gland. The sensitivity, specificity, PPV, NPV and accuracy of TRUS in prostate cancer detection of this study were 10.81%, 99.75%, 85.71%, 88.83% and 88.78% respectively. Santos et al [21] in a study on the current role of trans rectal ultrasonography in the early detection of prostate cancer reported a sensitivity, specificity, PPV and NPV of 58.0%, 79.2%, 62.0% and 73.6% respectively. Reason for this reduced sensitivity in this study may be due to the difference in the regions biopsied as both the transitional and peripheral zones were biopsied in this study as compared to peripheral zone biopsied predominantly by Santos et al [21]; moreover, a lower disease prevalence (12.33%) was seen in this study as compared to 36.9% reported by Santos et al. [21] Multiparametric MRI is a promising diagnostic tool for clinically significant prostate cancer. MRI-guided biopsies may offer an improvement in avoiding overdiagnosis and subsequent overtreatment of prostate cancer [19]. In this study, overall Cancer Detection Rate (CDR) for cognitive targeted biopsy was 64% (32 patients with malignancy of 50 patients); while standard systemic biopsy had a CDR of 16% (8 patients with suspicious features on TRUS who has prostate cancer on histology from the total 50 patients); difference being statistically significant with a p value of  $< 0.0001$ . Tonttila et al [22] found a comparable cancer detection rate for cognitive targeted biopsy at 64% however they reported a higher value for systematic biopsy (SB) at 57%; this may be due to the higher sample size used by Tonttila et al [22] (130) over a 3 year period; moreover, all the patients in this study had both

CTB and TRUS guided biopsy while Tonttila et al [22] conducted the CTB and TRUS guided systematic study in separate group of patients. Studies by Porpiglia et al [18] and Ahmed et al [19] showed that the cancer detection rate improved by the addition of multiparametric MRI guided targeted biopsy to the systematic biopsy. Cancer detection rate for SB and CTB in the study by Porpiglia et al [18] was 20% and 46% respectively (p-value of less than 0.001). Similarly, Ahmed et al [19] study showed CDR with SB and CTB alone at 9.2% and 47.5% respectively. PIRADS score has been found to be a useful prognostic tool for prostate cancer stratification. This study found the yield of clinically significant prostate cancer for PIRADS 4 and 5 to be 83.3% and 88%. Thangarasu et al [23] in the prospective study on the efficacy of cognitive targeted transrectal ultrasound prostate biopsy in diagnosing clinically significant prostate cancer reported a lower cancer detection rate for PIRADS 4 and 5 at 52.17% and 70% respectively. Osseff et al [24] however reported 69% for PIRADS 4 and 95% for PIRADS 5 for cancer detection rate on cognitive targeted biopsy for clinically significant prostate cancer; differences may be due to the larger sample size in these studies as compared to this and the use of 3T MRI used as against 1.5T MRI used in this study. The accuracy of a test is the proportion of the screened population that will be correctly labelled as either diseased or disease free. The ROC curve is a plot of the sensitivity versus 1 – specificity of a diagnostic test (where 1 represents sum of true negative rate and false positive rates). An ROC curve can be considered as the average value of the sensitivity for a test over all possible values of specificity or vice versa. An AUC value of 0.5 depicts no discriminatory ability whereas AUC value of 1 connotes perfect predictor [25]. The AUC for multiparametric MRI was 0.933 which revealed that the use of mpMRI for cognitive targeted biopsy was more accurate than TRUS alone for systematic biopsy with an AUC of 0.547. This is statistically significant with p-value less than 0.05.

## Conclusion

In biopsy-naïve men in the study population with suspected early prostate cancer; multiparametric magnetic resonance imaging with cognitive targeted biopsy has a higher accuracy and a higher detection rate of clinically significant prostate cancer as compared to standard systematic biopsy with transrectal ultrasonography alone. There is also a positive correlation between PIRADS score and cancer detection rate.

## Reference

1. Mohammed AZ, Edino ST, Ochicha O, Gwarzo AK, Samaila AA (2008) Cancer in Nigeria: a 10 year analysis of the Kano Cancer Registry. *Nigerian Journal of Medicine* 17: 280-284.
2. Rawla P (2019) Epidemiology of Prostate Cancer. *World J Oncol* 10 : 63-89.
3. (2021) CancerStat Facts: Prostate Cancer. National Cancer Institute.
4. Chen FK, De Castro Abreu AL, Palmer SL (2016) Utility of Ultrasound in the Diagnosis, Treatment, and Follow-up of Prostate Cancer: State of the Art. *Journal of Nuclear Medicine*. 57 : 13S-18S
5. Hoeks CM, Barentz JO, Hambrock T, Yakar D, Somford DM (2011) Prostate cancer: multiparametric MR imaging for detection, localisation, and staging. *Radiology* 261: 46-66.
6. Kim CK, Park BK (2008) Update of prostate magnetic resonance imaging at 3T. *J Comput Assist Tomogr* 32: 163-172.
7. Kim CK (2015) Magnetic resonance imaging-guided prostate bioUpsy: present and future. *Korean J Radiol* 16:90-98.
8. Bjurlin MA, Meng X, Le Nobin J, Wysock JS, Lepor H (2014) Optimisation of prostate biopsy: the role of magnetic resonance imaging targeted biopsy in detection, localisation and risk assessment. *J Urol* 192: 648-658.
9. Barentsz JO, Richenberg J, Clements R, Choyke P, Verma S (2012) ESUR prostate MR guidelines 2012. *Eur Radiol* 22 : 746-757
10. Weinreb JC, Barentsz JO, Choyke PL, Cornud F, Haider MA (2016) PI-RADS prostate imaging-reporting and data system: 2015, Version 2. *Eur Urol*. 69:16-40.
11. Hambrock T, Hoeks C, Hulsbergen-van de Kaa C, Scheenen T, Futterer J (2012) Prospective assessment of prostate cancer aggressiveness using 3-T diffusion-weighted magnetic resonance imaging guided biopsies versus a systematic 10-core transrectal ultrasound prostate biopsy cohort. *Eur Urol* 61:177-184.
12. Franiel T, Stephan C, Erbersdobler A, Dietz E, Maxeiner A (2011) Areas suspicious for prostate cancer: MR-guided biopsy in patients with at least one transrectal US-guided biopsy with a negative finding-multiparametric MR imaging for detection and biopsy planning. *Radiology* 259:162-172.
13. Peuch P, Rouviere O, Renard-Penna R, Villers A, Devos P (2013) Prostate cancer diagnosis: multiparametric MR-targeted biopsy with cognitive and transrectal US-MR fusion guidance versus systematic biopsy-prospective multicentre study. *Radiology* 268: 461-469.
14. Haffner J, Lemaitre L, Puech P, Haber GP, Leroy X (2011) Role of magnetic resonance imaging before initial biopsy: comparison of magnetic resonance imaging-targeted and systematic biopsy for significant prostate cancer detection. *BJU Int* 108: E171-178.
15. Ajape AA, Ibrahim OO, Fakeye JA, Abiola OO (2010) An Overview of Cancer of the Prostate, Diagnosis and Management in Nigeria: the Experience in a Nigerian Tertiary Hospital. *Annals of African Medicine* 9: 113-117.
16. Ikuero SO, Omisanjo OA, Bioku MJ, Ajala MO, Nonyelim Mordi VP, et al (2013) Prevalence and Characteristics of Prostate Cancer among Participants of a Community Based Screening in Nigeria Using Serum Prostate-Specific Antigen and Digital Rectal Examination. *Pan African Medical Journal*. 15: 129
17. Ojewola RW, Tijani KH, Jeje EA, Ogunjimi MA, Anunobi CC, et al (2013) An evaluation of usefulness of prostate specific antigen and digital rectal examination in the diagnosis of prostate cancer in an unscreened population; experience in a Nigerian Teaching Hospital. *West Afr.J.Med* 32: 8-13.
18. Porpiglia F, Manfredi M, Mele F, Cossu M, Bollito E, et al. (2017)



- Diagnostic Pathway with Multiparametric Magnetic Resonance Imaging Versus Standard Pathway; Results from a Randomized Prospective Study in Biopsy-naïve Patients with Suspected Prostate Cancer. *Eur Urol* 72: 282-288.
19. Ahmed HU, El-Shater Bosaily A, Brown LC and the PROMIS study group (2017) Diagnostic accuracy of multi-parametric MRI and TRUS biopsy in prostate cancer(PROMIS): a paired validating confirmatory study. *Lancet* 389: 815-822.
  20. Salji MJ, Ahmad I, Slater S, Poon FW, Alhasso A (2019) Prostate neoplasm. In: Omar M. Aboumarzouk, Editor. *Blandy's Urology* 3rd Edition. Hoboken: Wiley Blackwell 563-598.
  21. Santos VCT, Milito MA, Machiori E (2006) Current role of transrectal ultrasonography in the early detection of prostate cancer. *Radiol.Bras* 39:185-192.
  22. Tonttila PP, Lantto J, Paako E, Piippo U, Kauppila S (2016) Prebiopsy Multiparametric Magnetic Resonance Imaging for Prostate Cancer Diagnosis in Biopsy-naïve men with Suspected Prostate cancer Based on Elevated Prostate-specific Antigen Values;Results from a Randomized Prospective Blinded Controlled Trial. *Eur Urol* 69: 419-425.
  23. Thangarasu M, Jayaprakash SP, Selvaraj N, Bafna S, Paul R (2021) A Prospective Study on the Efficacy of Cognitive Targeted Transrectal Ultrasound Prostate Biopsy in Diagnosing Clinically Significant Prostate Cancer. *Research and Reports in Urology* 207-213.
  24. Ossess DF, van Asten JJ, Tijsterman JD (2018) Cognitive-Targeted versus Magnetic Resonance Imaging- Guided Prostate Biopsy in Prostate Cancer Detection. *Curr Urol* 11:182 -188.
  25. Mandrekar JN (2010) Receiver Operating Characteristic curve in diagnostic test assessment. *J.ThoracOncol* 5: 1315-1316.