



Research Article

Surgical Care for Children with Foreign Bodies in the Airways

Shamsiev AM, Shamsiev JA*, Ruziev JA, Dusyarov JT, Shamsiev RJ

Specialized Pediatric Surgeon Clinic of the Samarkand State Medical University, Samarkand, Uzbekistan

***Corresponding author:** Jamshid Shamsiev, Department of Surgery, Specialized Pediatric Surgeon Clinic of the Samarkand State Medical University, Samarkand, Uzbekistan

Citation: Shamsiev AM, Shamsiev JA, Ruziev JA, Dusyarov JT, Shamsiev RJ (2024) Surgical Care for Children with Foreign Bodies in the Airways. Arch Surg 4: 121 DOI: 10.29011/3066-2559.000021

Received Date: 04 October, 2024; **Accepted Date:** 27 December, 2024; **Published Date:** 30 December, 2024

Summary

An analysis was made of 1355 children with a suspected foreign body of the respiratory tract (IT FB), treated in the Specialized Pediatric Surgeon Clinic of the Samarkand Medical University over the past 20 years. Of these patients, 948 patients were diagnosed and were divided into two subgroups according to the method of treatment. The first subgroup of 478 patients with FB AP, in the period from 2000 to 2009, the removal of FB was performed using rigid bronchoscopy. The second subgroup of 470 patients treated in the period from 2010 to 2019, the removal of FB was performed by video bronchoscopy. The use of video bronchoscopy contributed to a clear visualization of all departments of the AP and IT, made it possible to easily and quickly remove the latter, significantly improved the course of the post-bronchoscopy period and reduced the development of late complications.

Keywords: Children; Foreign Body of the Respiratory Tract; Video Bronchoscopy

FBs of the trachea and bronchi are an emergency pathology that often manifests itself as acute respiratory failure and requires urgent medical intervention [1,2,3,4]. The annual percentage of hospitalization of children with RT inhalation in relation to all children who are on inpatient treatment ranges from 2.7% to 14.3% [5,6]. Aspiration of FB in the vast majority of cases occurs in childhood (66.1–97.2%). Among patients with FB RT, the majority are children aged 1 to 5 years [1,5,7]. The relevance of this pathology in children is also due to anatomical and physiological features that contribute to the rapid development of severe, often irreversible changes in the respiratory system [5,8]. The aim of the study was to improve the results of treatment of children with foreign bodies of the respiratory tract based on the optimization of the treatment and diagnostic program and bronchoscopic technologies.

Materials and Methods

For the period from January 2000 to June 2019, 14432 patients with

various diseases were treated in the Department of Thoracic Surgery of the 2nd Clinic of the Samarkand State Medical University, including 1355 patients with suspected FB RT. Of these, 407 children (30.0%) with an excluded diagnosis constituted a CCG, which is necessary to determine the sensitivity of the diagnostic methods used, and 948 (70.0%) patients with FB RT constituted the main clinical group. In order to study the effectiveness of the proposed tactics for treating the pathology under study, MCG was divided into two subgroups (Figure 1). Young children prevailed - (56.3%), of which 190 (46.6%) were from the clinical comparison group and 573 (60.4%) from the main clinical group. In second place in terms of number were patients aged 3 to 7 years (Table 1). As can be seen from Table 1, among all patients, young children prevailed 763 (56.3%), 190 (46.6%) in the CCG and 573 (60.4%) in the MCG. There were 292 (21.6%) patients in the age group of 3-7 years, with 80 (19.7%) children in the CCG and 212 (22.4%) in the MCG. here were almost 2 times more boys than girls - 63.3% and 36.7%, respectively. There were 4.5 times more children from rural areas than from urban areas. In 14.2% of cases, patients were admitted in severe, extremely severe or in a state of clinical death.

To achieve this goal, an anamnesis was taken, clinical, radiological, bronchological research methods, cytological and bacteriological examination of Bronchoalveolar Fluid (BALF) were used. When collecting an anamnesis, the main task was to record the fact of FB aspiration. The circumstances of the delayed diagnosis of aspiration of a foreign body during its long stay in the RT were studied. According to indications, bronchography, Multislice Computed Tomography (MSCT), virtual bronchoscopy were performed.

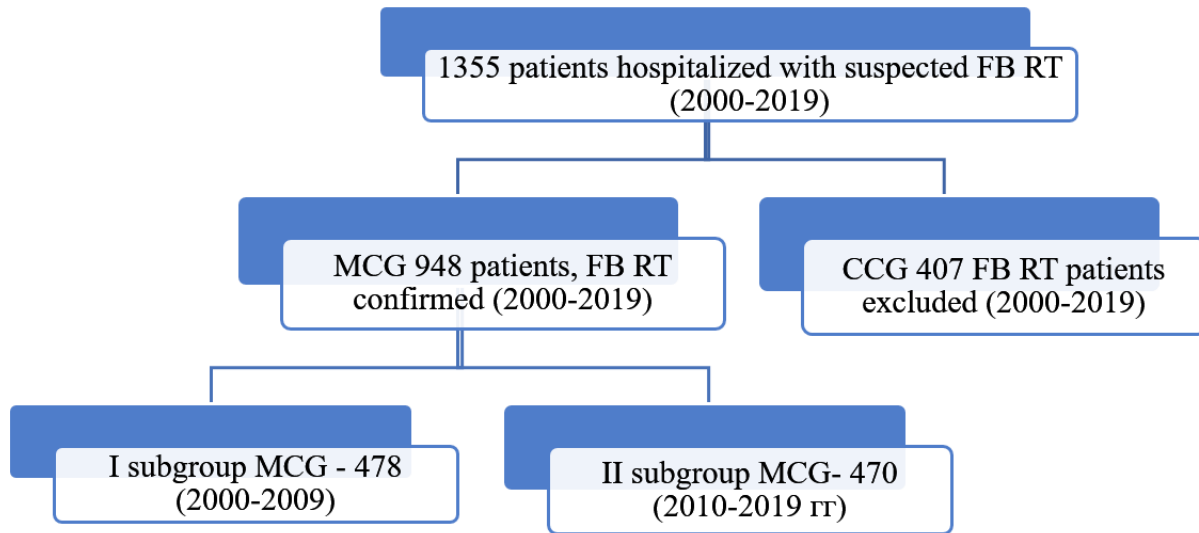


Figure 1: Study Design

Age	Clinical group		Total
	MCG	CCG	
Up to 1 year	92 (22,6%)	53 (5,6%)	145 (10,7%)
1-3 year	190 (46,6%)	573 (60,4%)	763 (56,3%)
3-7 year	80 (19,7%)	212 (22,4%)	292 (21,6%)
7-12 year	35 (8,6%)	92 (9,7%)	127 (9,4%)
12-15 year	8 (2,0%)	13 (1,4%)	21 (1,5%)
15-18 year	2 (0,5%)	5 (0,5%)	7 (0,5%)
Total	407 (100%)	948 (100%)	1355 (100%)

$\chi^2=88,595$; critical value $\chi^2=15,086$ ($p=0,01$); $p<0,01$

Table 1: Distribution of patients according to the age and groups.

Results and Discussion

When analyzing the anamnesis of 948 MCG patients, it was revealed that in 902 (95.1%) children, the parents recorded the moment of FB aspiration. Of these, only 355 (37.4%) patients sought medical help in the first 24 hours, the remaining 547 (60.6%) - later than the first day (Figure 2). It should be noted that doctors with other diagnoses treated more than 50% of them. The leading complaints at admission in patients with a duration of FB stay in the RT up to a day were: cough - in 355 (100%) patients; change in breathing (noisy, difficult, stridor breathing, shortness of breath) - in 334 (94.1%) children (Table 3). In 593 (62.6%) children admitted later than a day after the aspiration of FB, the main complaints were: cough, often wet, in 593 (100%) patients, respiratory change in 570 (96.1%) children. Organic FB was in 776 (81.9%) children, non-organic - in 172 (18.1%). The most frequent organic FBs were various seeds and nuts, accounting for 58.1% of cases. Among inorganic FB, plastic items were the most common - 103 (59.8%) cases. The main localization

of aspirated FBs in children (Table 2) is the bronchi (85.5% of cases), much less often they remain in the larynx 34 (3.6%) and in the trachea 61 (6.5%). In the bronchi of the right lung, foreign bodies were found more often 486 (51.3%) than in the bronchi of the left lung 284 (30.0%). FBs were located in both main bronchi in 41 (4.3%) patients. In 56 (12.8%) cases, simultaneous aspiration into different parts of the Tracheobronchial Tree (TBT) was noted, which significantly worsened the condition of the children and their treatment. Most of the aspirated organic FBs were chewed - 439 (57.7%), that is, multiple FBs fell into the RT. On chest radiographs, the following signs were revealed in patients: increased lung pattern in 582 (75.4%) patients, increased pneumatization on the FB side in 336 (43.5%) patients. Hypoventilation of the lung - in 268 (34.7%). In 172 (17.7%) children, direct and indirect signs of FB RT were absent on chest radiographs. MSCT of the chest organs was performed in 49 patients. Of these, in 22 (44.9%) FB RT was subsequently removed, and in 27 (55.1%) this diagnosis

was excluded. In 22 (44.9%) patients, the presence of FB in the RT (MCG) was noted, and in 27 (55.1%) children (CCS) there were no foreign objects in the TBT. In MSCT of 49 patients with suspected FB RT in 20 (40.8%) cases, a positive conclusion was obtained on the proposed diagnosis. Confirmation of this diagnosis during bronchoscopy was obtained in 22 (44.9%) of these patients. There were 2 (4.1%) false-negative conclusions on MSCT. A negative conclusion on the diagnosis of FB RT according to MSCT data occurred in 26 (53.1%) cases. Of the indicated number of patients with an excluded diagnosis, subsequently, no FB was found in all children, that is, MSCT data turned out to be true negative. However, there was 1 false positive case (2.0%). With MSCT of the RT, diagnostic errors, presented as false negative and false positive conclusions, were made in 3 (6.1%) cases. Calculations were performed to obtain the following performance indicators of MSCT in FB RT: the sensitivity of the latter was 90.1%, the specificity was 96.3%, and the diagnostic accuracy was 93.9%.

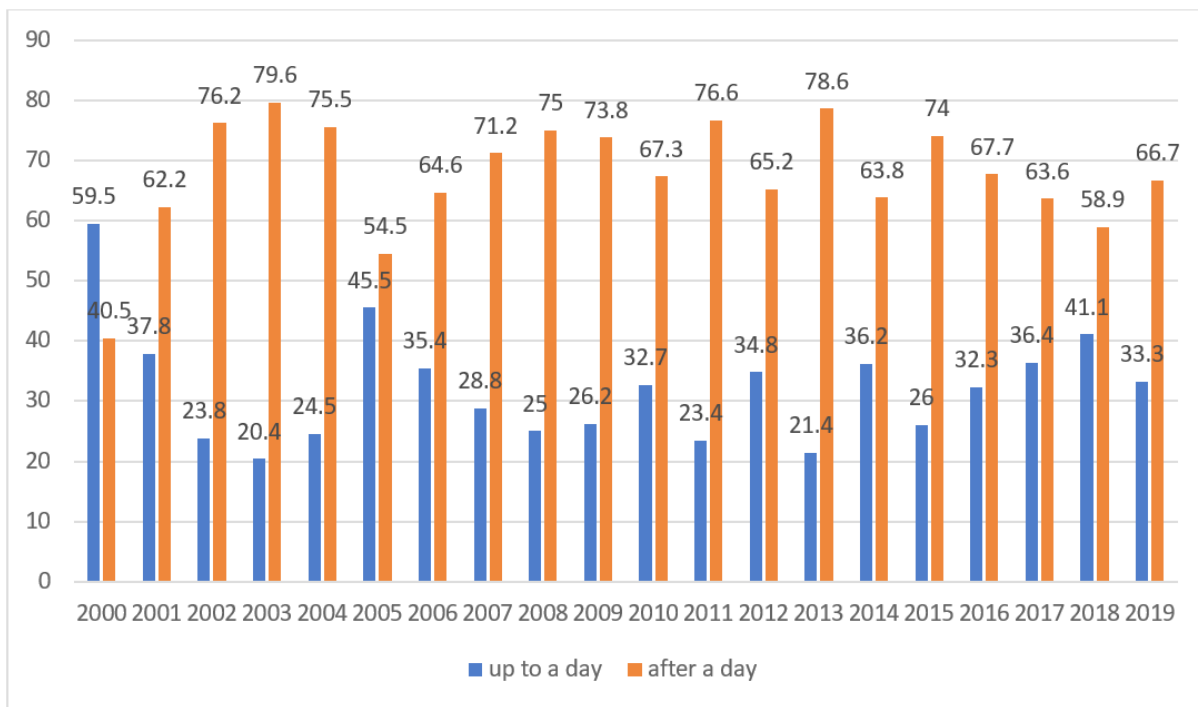


Figure 2: Diagram of the number of children admitted to the hospital on the first day and after the day after FB aspiration by years of observation.

Sections of the tracheobronchial tree	Organic	not organic	Total
	FB 776	FB 172	
Larynx	30 (3,9%)	3 (1,7%)	33 (3,5%)
Larynx and bronchi	1 (0,1%)	-	1 (0,1%)

Trachea	34 (4,4%)	13 (7,6%)	47 (5,0%)
Trachea and bronchi	14 (1,8%)	-	14 (1,5%)
Both bronchi	34 (4,4%)	7 (4,1%)	41 (4,3%)
Right main bronchus	383 (49,3%)	76 (44,2%)	459 (48,4%)
Right lower lobe	7 (0,9%)	5 (2,9%)	12 (1,3%)
Left main bronchus	162 (20,9%)	41 (23,8%)	203 (21,4%)
Left lower lobe	65 (8,4%)	16 (9,3%)	81 (8,5%)
Undefined	46 (5,9%)	11 (6,4%)	57 (6,0%)
Total	776 (100)	172 (100)	948 (100)
$\chi^2=9,609$; critical value $\chi^2=14,067$ ($p<0,05$); $p>0,05$			

Table 2: Localization of aspirated foreign bodies in the respiratory tract depending on their nature (n=948).

Of the 948 patients with MCG, 914 (96.4%) underwent bronchoscopy, on the basis of which the state and nature of changes in the mucous membrane of the TBT, as well as the prevalence of the inflammatory process caused by the presence of FB in the trachea or bronchi, were studied. With the duration of FB stay for one day, the frequency of bronchopulmonary complications was 77.8% of cases, due to catarrhal forms of endobronchitis - 72.4%. When FBs was in the RT for more than a day, the frequency of complications was 91.8% of cases, purulent forms of endobronchitis predominate here - 66.3%. The frequency of bronchopulmonary complications is mostly due to FB of organic origin - 81.9% of cases. In 6.8% of cases, complications were not observed or bronchoscopy was not performed. According to the classification, V. Lemoine (1971) limited (local) endobronchitis was observed in 414 (43.7%) children, of which unilateral in 401 (42.4%), bilateral - in 13 (1.3%) patients. Diffuse partial endobronchitis was diagnosed in 398 (42.0%) patients, of which unilateral in 359 (37.9%), bilateral - in 39 (4.1%). Diffuse endobronchitis was noted in 20 (2.1%) cases, unilateral - in 7 (0.7%), bilateral - in 13 (1.4%). Bacteriological cultures of bronchial washings for flora were performed in 253 patients (26.7% of cases), flora was found in 132 (52.2%) children, and was not found in 121 (47.8% of cases). The main microorganism was: Staphylococcus Aureus - in 98 children (38.7%). Cytological examination of BALF was carried out using a video microscope equipped with a video camera and a computer. Cytological characterization of BALF was performed in 274 (20.2%) of 1355 patients. Cytologically proven stages and prevalence of endobronchitis caused by the presence of FB in the RT (table 3). In our work, we used two main methods for the removal of FB RT, so MCG patients were divided into two clinical subgroups. From 2000 to 2009 in the thoracic department, 478 children with FB RT were hospitalized, which made up the first subgroup of the MCG of our study. In 44 (9.2%) patients, self-removal of FB was observed.

The degree of change in the walls of the respiratory tract	n=470		n=407	
	abc	%	abc	%
Catarrhal changes (endobronchitis)	129	52,0	11	42,3
Purulent endobronchitis	95	38,3	9	34,6
Purulent-fibrinous endobronchitis	2	0,8	0	0
Without changes	22	8,9	6	23,1
Total	248	100	26	100
The value of the χ^2 criterion is 5.376; The critical value of χ^2 at the significance level $p<0.05$ is 7.815; The relationship between factor and performance characteristics is not statistically significant, significance level $p>0.05$; Significance level $p=0.147$				

Table 3: Conclusion of the cytological study of BALF by groups.

To remove FB RT in children of this subgroup, a respiratory bronchoscope with proximal illumination of the Friedel system (Germany) was used. In 19 (4.0%) patients of the described group, bronchoscopy was not performed, in 459 (96%) patients 649 bronchoscopies were performed. Since 2010, we have begun to use the EndoPik respiratory video bronchoscope (South Korea) to remove FB RT in 470 children of the II subgroup of MCG. In this subgroup, during bronchoscopy, the TBT was washed with ozonized saline, and at the end, an acetylcysteine solution was injected. In 55 (11.7%) of them, self-discharge of FB was noted, bronchoscopy was not performed in 15 (3.2%) children, 455 (96.8) patients underwent 532 bronchoscopy. When assessing the quality of the TBT view when using the Friedel bronchoscope and video bronchoscope, the preference of surgeons was on the side of the latter. So, when considering the quality of the review of the trachea, main bronchus, lobar bronchi and segmental bronchi, the good value of these indicators in the II subgroup of the MCG was 100% for each department of the TBT, while in the I subgroup of the MCG they were 46.2%, 17.9%, and visualization was null in the lobar and segmental bronchi. This means that it was easier, more convenient, and most importantly more informative to perform bronchoscopy using a video bronchoscope. When removing FBs from the TBT, the average value of the “number of attempts to capture FBs” was estimated, when using a video bronchoscope it was 3.46 ± 0.04 points, and when using a Friedel bronchoscope - 1.82 ± 0.04 ($p=0.000000$). Comparative analysis of the “FB traction” indicator revealed a significant difference in favor of the

video bronchoscope, the average score in subgroup I and subgroup II was 2.72 ± 0.02 and 3.96 ± 0.01 , respectively. The average value of the indicator “injury to the walls of the bronchi” when using a video bronchoscope was 3.61 ± 0.03 versus 2.38 ± 0.032 for the Friedel bronchoscope. The average time of manipulation when using the Friedel bronchoscope to remove FB RT was 21.39 ± 0.4 minutes, in the videobronchoscopy subgroup - 14.45 ± 0.1 minutes. The conducted intraoperative comparison of bronchoscopy techniques shows the advantage of the video bronchoscope in all evaluation criteria.

The Friedel respiratory bronchoscope provides not quite adequate visualization and detailing of the surgical field, gives an incomplete idea of the size, shape and structure of FB in the TBT. The introduction of forceps significantly worsens the view and makes it difficult to accurately capture FB. In terms of one-stage removal of a foreign body from the respiratory tract, the advantage was on the side of video bronchoscopy. In all patients, during videobronchoscopy, the airways were completely sanitized and specific indications were set for repeated medical-sanation bronchoscopy. And in the subgroup of patients with the Friedel bronchoscope in 12 (2.5%) children, it was not possible to remove the FB completely or it was not found during the first manipulation. In the II subgroup of the MCG, a single video bronchoscopy was performed in 81.7% of patients, while in the I subgroup of the MCG, this figure was 62.4%. In subgroup I, indications for repeated therapeutic bronchoscopy were made on the basis of clinical data (Table 4).

The frequency of bronchoscopy	II nd Subgroup MCG 470 (455)*	I st MCG 478 (459)*
once	383 (81,7%)	298 (62,4%)
twice	68 (14,5%)	134 (28,0%)
three times	3 (0,6%)	25 (5,2%)
four times	1 (0,2%)	2 (0,4%)
Not carried out	15 (3,0%)	19 (4,0%)
Total bronchoscopies	532	649
$\chi^2=50,722$; critical value χ^2 ($p=0,01$) =13,277; $p<0,001$		

Note: * - in subgroup II MCG, out of 470 patients, bronchoscopy was performed in 455 (15 children with self-terminated FB TR showed no indications for bronchoscopy); ** - in subgroup I MCG, out of 478 patients, bronchoscopy was performed in 459 patients (19 children after self-removal of FB RT did not undergo bronchoscopy due to lack of indications).

Table 4: The frequency of bronchoscopy in one patient in MCG subgroup.

In the subgroup of video bronchoscope use, a decrease in the duration of clinical manifestations in the postoperative period was noted, namely, the duration of the cough period decreased by 2.5 days, the period of recovery of breathing - by 3.5 days, the duration of wheezing by 3 days. In 6 (1.26%) patients of subgroup I of the main clinical group, FB was removed promptly. The postoperative period in these patients was uneventful. No surgeries were performed in subgroup II of the main clinical group. A good immediate result of treatment was stated in 288 (60.3%) patients of subgroup I and in 434 (92.3%) patients of subgroup II MCG, satisfactory in 173 (36.2%) in subgroup I and in 36 (7.7%) - in subgroup II, and unsatisfactory results were 17 (3.5%) and 0 (0.0%) patients in subgroups I and II, respectively. Long-term results of treatment of patients were studied in terms of 2 to 20 years after discharge from the hospital in 1111 (81.2%) patients out of 1355 children, including 307 (75.4%) patients of the clinical comparison group and 804 (84.8 %) from the main clinical group of 400 (83.7%) people from the I subgroup and 404 (86.0%) from the II subgroup of the MCG. The results of treatment in the acute period of the disease in subgroup II of the main clinical group contributed to a significant reduction in complications in the long-term period. So, if in the I subgroup of the MCG 29 (7.3%) out of 400 patients complained of a cough of a periodic nature, frequent treatment of inflammatory diseases on an outpatient basis, then in the II subgroup of 404 people this figure was only 9 (2.2%) ($p < 0.01$). We observed the same ratio with respect to another complication of the long-term period - relapses of chronic bronchitis - 22 (5.5%) and 5 (1.2%), respectively. The use of improved technique in MCG subgroup II made it possible to completely exclude repeated bronchoscopy in the long-term period, while in MCG subgroup I they were performed in 6 (1.75%) cases. Among the patients of subgroup I of the main clinical group 1 (1.0%) called for follow-up examination, the child underwent surgery: Videothoracoscopic pneumonectomy.

Conclusion

- Most of the patients with FB RT are children of early age (1-3 years) of life (60.4%). Male children predominate (63.5%), from rural areas (82.3%), in whom organic foreign bodies got into the respiratory tract (81.9%), of which chewed multiple FBs are more common - 57.7%.
- Clinical signs in children with FB RT depend on the nature, size and location of the aspirated material and vary from asymptomatic to severe respiratory failure. Virtually no distinctive clinical manifestations allow diagnosing or excluding FB RT.

- Video bronchoscopy allows assessing the state, nature and prevalence of the inflammatory process of the walls of the TBT, the degree of obstruction of the lumen of the bronchus, as well as the size, shape and structure of the FB. The sensitivity, specificity and diagnostic accuracy of the method is 100%. MSCT in FB RT showed high sensitivity (90.1%), specificity (96.3%) and diagnostic accuracy (93.9%).

- The frequency of formation of purulent endobronchitis sharply increases with FB of an organic nature on the first day, and with an increase in the prescription of being in the RT, regardless of the nature of the foreign agent. Purulent forms of endobronchitis in the presence of FB up to one day are observed in 5.4% of cases, and with a duration of more than 1 day - in 66.3% of cases, this is confirmed cytologically.

Reference

1. Kajina VA, Kazhina VA, Klochko AI, Serhiyenka VK, Yakubtsevich RE, et al. (2015) Removal of foreign bodies from the tracheobronchial tree in children in Grodno region: 10-year experience of rigid bronchoscopy with video visualisation. *Jurnal Grodnenskogo gosudarstvennogo meditsinskogo universiteta - Journal of Grodno State Medical University* 4: 108-113.
2. Cutrone C, Pedruzzi B, Tava G, Emanuelli E, Barion U, et al. (2011) The complimentary role of diagnostic and therapeutic endoscopy in foreign body aspiration in children. *Int J Pediatr Otorhinolaryngol* 75: 1481-1485.
3. Ding G, Wu B, Vinturache A, Cai C, Lu M, et al. (2020) Tracheobronchial foreign body aspiration in children: A retrospective single-center cross-sectional study. *Medicine* 99.
4. Huankang Z, Kuanlin X, Xiaolin H, Witt D. Comparison between tracheal foreign body and bronchial foreign body: a review of 1,007 cases. *Int J Pediatr Otorhinolaryngol* 76: 1719-1725.
5. Ruseskiy Yu.Yu, Spiranskaya OA, Chernishenko IO, et al. (2015) Foreign bodies of the lower respiratory tract in children: modern diagnostic and therapeutic approach. *Jurnal Pediatriya. - Journal of Pediatrics* 94.
6. Boufersaoui A, Smati L, Benhalla KN, Boukari R, Smail S, et al. (2013) Foreign body aspiration in children: experience from 2624 patients. *Int J Pediatr Otorhinolaryngol* 77: 1683-1688.
7. Gibbons AT, Casar Berazaluze AM, Hanke RE, McNinch NL, Person A, et al. (2020) Avoiding unnecessary bronchoscopy in children with suspected foreign body aspiration using computed tomography. *J Pediatr Surg* 55: 176-181.
8. Kogure Y, Oki M, Saka H (2010) Endobronchial foreign body removed by rigid bronchoscopy after 39 years. *Interact Cardiovasc Thorac Surg* 11: 866-868.