



Case Report

Remission of Normocomplementemic Urticarial Vasculitis with Omalizumab-A Case Report

Kathuria PC*, Manisha Rai

BLK Super Specialty Hospital & National Allergy Centre, New Delhi, India

*Corresponding author: Kathuria PC, BLK Super Specialty Hospital & National Allergy Centre, New Delhi, India

Citation: Kathuria PC, Rai M. (2021) Remission of Normocomplementemic Urticarial Vasculitis with Omalizumab-A Case Report. Arch Surg Clin Case Rep 4: 155. DOI: 10.29011/2689-0526.100155

Received Date: 20 August, 2021; **Accepted Date:** 25 August, 2021; **Published Date:** 30 August, 2021

Abstract

Normocomplementemic urticarial vasculitis (NUV) is a clinicopathological entity often presenting as classic indurated wheals and may occur in association with autoimmune disease, infections, malignancy, drugs etc. We report a case of 22 years old female patient with NUV for the last ten years without improvement with repeated courses of dapsons, Hydroxychloroquine (HCQS) and Oral corticosteroids (OCS). She achieved sustained remission of the disease after two years of treatment with Omalizumab and further follow-up of five-years. In our case, Omalizumab has shown to have a promising role in severe NUV with no adverse effects.

Keywords: Urticarial vasculitis (UV); Normocomplementemic urticarial vasculitis (NUV); Hypocomplementemic urticarial vasculitis (HUV); Hypocomplementemic Urticarial vasculitis Syndrome (HUVS); Omalizumab, Leukocytoclastic vasculitis

Introduction

Urticarial Vasculitis (UV) is a clinicopathological entity due to inflammatory injury of small vessels of the skin or extend systemically affecting various organs including musculoskeletal renal, pulmonary and ocular system. It is an immunological disease characterized by Immune complex mediated type III hypersensitivity reaction with complement activation, increased capillary permeability and upregulation of neutrophil chemotaxis. Histopathological urticarial lesions showing features of leukocytoclastic vasculitis, fibrinoid changes of the vessel walls are also often seen [1]. Some authors reported that eosinophilic predominant infiltrates occurred more often in normocomplementemic patients whereas neutrophilic dominant infiltrates are typical of hypocomplementemic patients. One study conducted in Sweden estimated an annual incidence of 0.7% for urticarial vasculitis with a point prevalence of 9.5 per million as of December 2015 (Sjowall et al., 2018) [2].

UV can be classified into three subtypes: (1) Normocomplementemic Urticarial Vasculitis (NUV)- when a patient has major symptoms of UV combined with normal levels of C1q complement. It is less likely to be associated with any other organ involve-

ment. (2) Hypocomplementemic Urticarial vasculitis (HUV)- it is more severe form of UV, includes symptoms of arthritic joint pain breathing difficulties such as Asthma and stomach pains combined with lower than normal levels of C1q complement and raised levels of anti-C1q antibodies. (3) Hypocomplementemic Urticarial vasculitis Syndrome (HUVS)- HUVS have more extensive complement abnormalities (low circulating third and fourth complement components) combined with symptoms of episcleritis or uveitis, mild glomerulonephritis, pleuritis, angioedema and COPD and myocardial infarction [3].

The cause of UV is often unknown, but there have been numerous reports of cases triggered by drugs (10-15%), infections (20%), autoimmune connective tissue disease (15-20%), myelodysplastic disorders or malignancy (5%). There are no tools for assessing disease activity, impact and control of UV so far. Although not validated, the UV activity score (UVAS) for patient daily self-assessment may be promising tool for assessing UV activity/severity [4]. It includes 5 subscales corresponding to the 5 key symptoms of UV: wheals, burning/pruritis, residual skin pigmentation, joint pain, and general symptoms. UVAS scores range from 0 to 10 per day (0=none; 10=very severe) [5].

Various traditional therapies have been tried in patients with UV like OCS, Hydroxychloroquine (HCQS), methotrexate, dapsons and oral anti-histamines but these treatments have shown unsatisfactory responses or dose-dependent adverse effects. Omalizumab is a humanized anti-IgE monoclonal antibody,

significantly reduces the activity and symptoms of chronic urticaria with a dose of 300 mg s.c. given once every four weeks [6]. The mechanism of action of Omalizumab and its role in the pathogenesis of UV remains uncertain. The maintenance dose of Omalizumab in UV, duration of treatment and tapering protocols are still unclear. We report a case with NUV confirmed by skin biopsy successfully treated with Omalizumab who was unresponsive to immunosuppressive standard treatments.

Case presentation

The patient was a 22-year-old female, over-weight, Body mass Index (BMI) of 33.3 kg/m² who unexpectedly developed severe, painful, burning skin rashes associated with itching on her trunk, proximal upper extremities, and lower extremities, ten years back associated with non-specific joint pains (Figure 1). The rashes consisted of erythematous and violaceous slightly ecchymotic infiltrated annular wheals lasting for more than 24 hours that resolved with residual post inflammatory hyperpigmentation. The patient noticed that the urticarial rashes tend to appear just before her menstrual cycle. The patient had no angioedema and no extracutaneous manifestations such as fever, arthralgia, lymphadenopathy, uveitis, or serositis. A possible diagnosis of Normocomplementemic Urticarial Vasculitis (NUV) was suspected for which laboratory test with skin biopsy was requested. Routine blood tests including Complete blood count (CBC), C-reactive protein (CRP), Thyroid stimulating hormone (TSH), Complement components C3/C4 levels, anti-cytoplasmic antibodies, serum G6PD, anti-nuclear antibodies (ANA) and Anti thyroid antibodies were normal. Erythrocyte sedimentation rate (ESR) was elevated (45 mm/hour). A skin biopsy revealed moderately dense inflammatory infiltrate in and around the walls of small and medium size vessels. The inflammatory infiltrate comprised of eosinophils, lymphocytes and few polymorphs, histopathology was compatible with urticarial vasculitis (Figure 2).

She presented with Urticarial vasculitis activity severity score (UVAS) of ten (10) and poor quality of life with fluctuating pattern of severity of disease. She was initially treated with anti-histamines, low dose oral corticosteroids and HCQS regularly, which led to symptom control but there was recurrence of symptoms on tapering the dose. After three months, the patient experienced relapse of skin rashes and was then treated with dapsone 50 mg twice daily, five days in a week for one month in June 2013 but she developed an adverse reaction and fall in blood hemoglobin level, so dapsone was discontinued. For the next two years she had on going symptoms requiring anti-histamines, oral corticosteroids on & off along with indigenous treatment without any improvement. Then in May 2015, the patient was started on Inj Omalizumab 150 mg s.c. once every four weeks. Compared with the baseline, the value of UVAS decreased to seven (7) after the fourth injection

(16 weeks). She continued taking injections for further eight months because of mild relapse with new wheals. Further, UVAS decreased to five (5) with improved quality of life in one year. We decided to continue omalizumab till remission was achieved over the next twelve months, the disease activity progressively decreased to remission (UVAS=0). She was followed up over the next five years with sustained remission and no apparent adverse effects after 28 injections of Omalizumab 150 mg monthly.

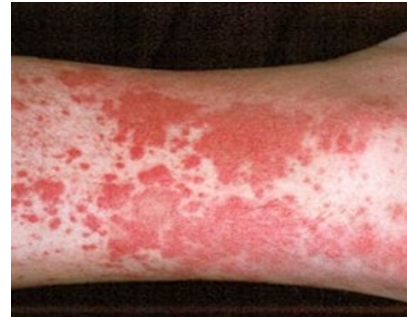

Figure 1: Wheals and erythematous maculae on skin.

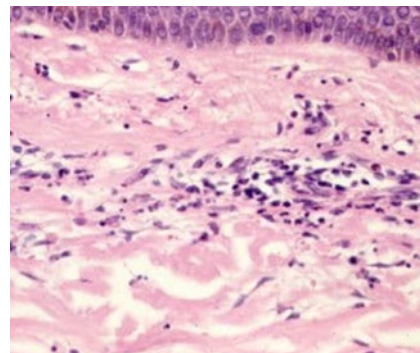


Figure 2: Histopathology of leukocytoclastic vasculitis

Discussion

Skin biopsy is the gold standard test for diagnosing UV, but the optimal time for skin biopsy is less than 48 hours after the appearance of a vasculitis lesion. If the biopsy is poorly timed, the pathological features of vasculitis may be absent. In NUV, the aim is to (a) exclude differential diagnosis, primarily CSU and Lipid Transfer Protein Syndrome (LTPS) with signs & symptoms of Urticaria, angioedema and anaphylaxis, (b) identify the relevant triggers and/or underlying causes, (c) assess the disease actively, impact and control, (d) plan for specific treatment. Clinically, it is difficult to distinguish lesions of UV from Chronic Idiopathic urticaria. In individuals with UV, wheals are often non or only partially blanchable with a central dark red or brown macule with ranges from 0.5 to 5 cm in diameter and last more than 24 hours, often persisting for several days and may leave behind a residual ecchymotic hyperpigmentation. While in chronic idiopathic

urticaria, lesions resolve within 2 to 3 hours and by definition within 24 hours, may coalesce and become very large in size (>10 cm) or serpiginous. In UV, symptoms tend to be more painful or burning as opposed to true urticaria which is most often pruritic (Wisnieski 2000) [2]. CBC, CRP, complement components, ESR, ANA and TSH are useful in differentiating between UV and Chronic spontaneous urticaria (CSU) and further analysis of serum levels of complement components differentiate between NUV and HUV/HUVS. Usually, a higher number of UV patients had elevated antithyroid antibodies as compared to patients with CSU. LTPS can be differentiated from idiopathic urticaria and angioedema by sensitization tests (Skin prick test and Specific IgE) along with Oral provocation test. The authors have published seven cases of LTPS having cross reactivity of tree pollen (*Prosopis juliflora* and *Haloptelea intergrifolia* with foods (Nuts, Lentils and citrus foods) and four cases of cross reactivity of weed pollen (*Artemisia vulgaris*) with foods (wheat and peanut) [7,8].

More than two-thirds of physicians observed wheals (83%), residual hyperpigmentation (70%) and burning of the skin (69%) in the majority i.e., 60-100% of UV patients [5]. Most of the physicians prefer second generation anti-histamines (SgAHs) or corticosteroids as the first line treatment for UV and if poor response then up-dosing of SgAHs and/or corticosteroids are the most common second line therapies, while cyclosporin and Omalizumab are the most common third and fourth line therapy [5]. Even though there are no prospective studies of role of Omalizumab in NUV and how treatment should be followed up in terms of disease activity, many case reports have shown successful response [9-12]. In our case, there was 30% improvement in the UVAS during the first four months and subsequent improvement of 50% over the next eight months. It was decided to continue Omalizumab for the next one year because of mild relapse with new wheals. Patient achieved clinical remission (UVS=0) at 24 months and discontinuation of anti-histamines and other supportive therapy with Omalizumab. However, the mechanism of action of Omalizumab remains unresolved in NUV.

Conclusion

As there are many challenges due to absence of clinical guidelines and treatment algorithms with limited drugs in NUV, we report successful and sustained remission with Omalizumab for NUV without any adverse effects during treatment. Further studies are required to confirm our finding of successful treatment with Omalizumab in the management of NUV in our clinical practice.

Acknowledgement

The authors would like to thank Dr Gagandeep Momi for providing assistance in reviewing this manuscript.

References

1. Rattananukrom T, Svetvilas P, Chanprapaph K. (2020) Successful treatment of normocomplementemic urticarial vasculitis with omalizumab: A report of three cases and literature review. *Asian Pac J Allergy Immunol.* 38: 286-289.
2. Stephanie LGu, Jorizzo JL. (2021) Urticarial Vasculitis. *International Journal of Women's Dermatology* 7: 290–297.
3. Morita TCAB, Trés GFS, Criado RFJ, Sotto MN, Criado PR. (2020) Update on vasculitis: an overview and dermatological clues for clinical and histopathological diagnosis - part I. *An Bras Dermatol.* 95: 355-371.
4. Krause K, Mahamed A, Weller K, Metz M, Zuberbier T, Maurer M. (2013) Efficacy and safety of canakinumab in urticarial vasculitis: an open-label study. *J Allergy Clin Immunol.* 132: 751-4.e5.
5. Kolkhir P, Bonnekoh H, Kocaturk E. (2020) Management of urticarial vasculitis: A worldwide physician perspective. *World Allergy Organ J.* 13:100-107.
6. Liu T, Bai J, Ying S, Li S, Pan Y, et al. (2021) Real-World Experience on Omalizumab Treatment for Patients with Normocomplementemic Urticarial Vasculitis. *J Asthma Allergy.* 14: 433-437.
7. Kathuria PC, Rai M. (2020) Wheat and peanut food allergy in mugwort (*Artemisia vulgaris*) sensitized patients: A case series of four cases. *Indian J Case Reports.* 6: 292-295.
8. Kathuria PC, Rai M. (2021) Case series of seven cases of urticaria, angioedema, and anaphylaxis (LTP Syndrome) due to foods (nuts lentils, and citrus foods) related to tree pollen (*Prosopis juliflora* and *Holoptelea integrifolia*) sensitization. *Indian J Case Reports.*
9. Degirmentepe EN, Kızıltac K, Etikan P, Singer R, Memet B, Kocaturk E. (2019) Omalizumab as a Successful Therapy in Normocomplementemic Urticarial Vasculitis: A Series of Four Patients and Review of the Literature. *Ann Dermatol.* 31: 335-338.
10. Ghazanfar MN, Thomsen SF. (2015) Omalizumab for Urticarial Vasculitis: Case Report and Review of the Literature. *Case Rep Dermatol Med.* 2015: 576893.
11. Cherrez-Ojeda I, Vanegas E, Felix M. (2018) Patient-reported outcomes in urticarial vasculitis treated with omalizumab: case report. *BMC Dermatol* 18: 8.
12. Zandile S, Peter JG, Roberts R, Lehloeny R. (2018) Treatment of Urticarial vasculitis with Omalizumab. *Current Allergy & Clinical Immunology:* December 31: 4.