



Case Report

Recurrent Immune Thrombocytopenia in a 71-Year-Old Woman Following Moderna COVID 19 Vaccination. The Need for Close Clinical and Biological Monitoring

Cyril Derouet, Boubacar Cissé, Komlanvi Kafui Houegnifioh, Nuno Palhais, Alain Kenfak Foguena, James Tataw Ashu*

Department of Internal Medicine, Jura Bernois Hospital, St Imier, (Be) Switzerland

*Corresponding author: James TATAW, Department of Internal Medicine, Jura bernois Hospital, St Imier, (Be) Switzerland.

Citation: Derouet C, Cisse B, Houegnifioh K, Palhais N, Kenfak A, Tataw J (2022) Recurrent Immune Thrombocytopenia in a 71-Year-Old Woman Following Moderna COVID 19 Vaccination. The Need for Close Clinical and Biological Monitoring. Ann Case Report 7: 786. DOI: 10.29011/2574-7754.100786

Received Date: 21 February 2022; **Accepted Date:** 26 February 2022; **Published Date:** 01 March 2022

Abstract

Immune Thrombocytopenia (ITP) is a blood disorder most commonly characterized by autoimmune destruction of platelets, resulting in a low platelet count with a variable risk of bleeding depending on the severity of the thrombocytopenia. SARS-COV2, the causative agent of coronavirus disease 2019 among several viruses has been associated with low platelet counts. Similarly, several cases of ITP after SARS-CoV-2 mRNA vaccines have been reported with treatment involving corticosteroids, intravenous immunoglobulin and in some severe cases requiring thrombopoietin agonists and platelet transfusion.

We report the case of a 71-year-old woman who presented with petechial lesions and severe thrombocytopenia one week after the second dose of Moderna Covid 19 vaccine. After an initial successful improvement in her platelet count after treatment with corticosteroids, we tapered off the steroids. However, she relapsed with severe thrombocytopenia 6 weeks later, which required inpatient adjuvant therapy combining intravenous platelet immunoglobulin transfusion, romiplostim and corticosteroids. It is therefore important to recognise ITP as a potential and recurrent adverse event in these patients and to adapt monitoring appropriately, particularly with the multiple doses (boosters) that will be required.

Introduction

In early February 2021 in the United States, a case of severe bruising and thrombocytopenia was reported in a patient who received the first dose of Moderna COVID-19 vaccine. The same condition resulted in the death of another patient. However, despite these serious adverse events and in the face of the ongoing pandemic, messenger Ribonucleic Acid (mRNA) vaccines such as Pfizer-BioNTech's BNT162b2 and Moderna's mRNA-1273 have shown promising results and are still in widespread use to bend the epidemic curve. Here we report a case of recurrent severe Immune Thrombocytopenia (ITP) after a second dose of Moderna covid-19 vaccine.

Case Report

A 71-year-old female patient with a history optimally controlled hypertension; atrial fibrillation anticoagulated with Rivaroxaban without any prior history of thrombocytopenia was addressed to the emergency department at the St Imier site of the Jura bernois SA hospital with symptoms of dizziness headache and hypotension. She did not have fever, coryza symptoms, abdominal pain, diarrhea, rectal bleeding, dysuria or altered mental state. She claimed no recent illness or contact with anyone who was unwell.

She had received the second of the two doses of Moderna Covid19 vaccine 7 days prior to developing these symptoms for which a full blood count requested by his primary care physician

revealed severe thrombocytopenia of $14 \times 10^9/L$. She was not on any medication, which could have been a culprit.

In the emergency room upon admission, she was afebrile, with a blood pressure of 120/70 mmHg. She had a petechial lesion on the antero-external aspects of his thighs. No petechial lesions were found in the oral and nasal mucosa. There was no hepatomegaly nor splenomegaly as well as no palpable lymph nodes peripherally. The laboratory results confirmed a platelet count of $14 \times 10^9/L$ without anemia nor leucopenia. The rest of the red cell indices were normal. A manual peripheral count confirmed severe thrombocytopenia without evidence of schizocytes and or hemolysis. Viral serologies for hepatitis C, hepatitis B, Human Immunodeficiency Virus (HIV) were negative as well for Cytomegalovirus (CMV), Epstein Bar Virus (EBV) and parvovirus B19. Other laboratory testing that were within normal limits included liver enzymes, bilirubin and C reactive peptides.

Her urine analysis revealed leukocyturia with without nitrites nor blood. A urine culture was not compatible with a urinary tract infection. A CT scan of the thorax and abdomen did not reveal hepatosplenomegaly nor show any evidence of an infection or a tumoral lesion. For Obvious reason a bone marrow biopsy was not performed.

In the absence of preexisting thrombocytopenia, after ruling out infectious causes with a low likelihood of a malignancy, as well as other clinical scenarios suggestive of thrombotic microangiopathy, hemolytic uremic syndrome or drug-induced thrombocytopenia, the diagnosis of COVID-19 vaccine induced Immune thrombocytopenia was retained.

She received 40 mg/day of oral dexamethasone for 4 days. With this regimen, her platelet count improved from $14 \times 10^9/L$ to $100 \times 10^9/L$ in about 5 days. The patient was discharged home with her usual treatment and outpatient hematologic follow-up was scheduled during which her platelet count rose to about $120 \times 10^9/L$. Steroids were gradually tapered off following a normalized platelet count.

Approximately 6 weeks after the initial episode, a recurrence of severe thrombocytopenia ($8 \times 10^9/L$) was noted during laboratory follow-up, prompting the initiation of a second course of corticosteroids as per the initial regimen (40 mg Dexamethasone 1x/d for 4 days). In the absence of response to this treatment, with persistent thrombocytopenia at $8 \times 10^9/L$, the patient was re-hospitalized with the hypothesis of recurrent Covid-19 Vaccine induce immune thrombocytopenia.

On admission, she was in very good general condition, with no clinical signs of a mucosal bleeding syndrome (ecchymosis, bleeding gums, sub conjunctival hemorrhage, epistaxis, hematuria), except for the presence of ecchymosis on the extremities and the trunk. The laboratory work-up confirmed

an isolated thrombocytopenia of $8 \times 10^9/L$ (Figure 1). Given that this thrombocytopenia was refractory to corticosteroid therapy, Intravenous immunoglobulin (1g/kg/) was administered in combination with an injection of 250mcg of Romiplostim (sub cutaneous), 1x/week. Following these therapeutic interventions, there was a rapid improvement of the thrombocytopenia to $28 \times 10^9/L$ two days later. Romiplostim treatment was continued on an outpatient basis with regular monitoring of the platelet count, which normalized 15 days after discharge.

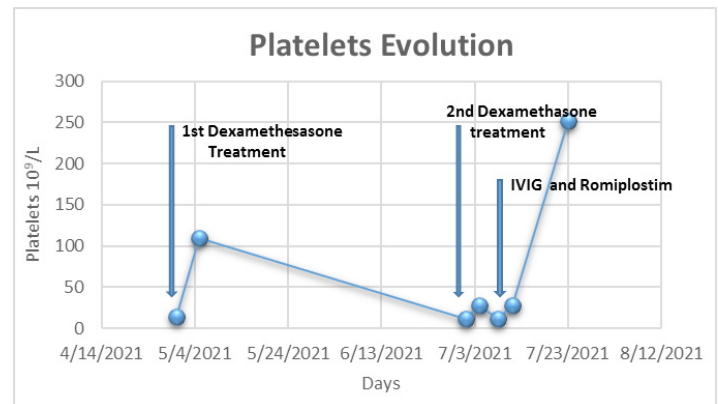


Figure 1: Time course of platelet counts in relation to the initial episode treatment with dexamethasone and the second episode requiring a combination of dexamethasone, Intravenous Immunoglobulin (IVIg) and a thrombopoietin receptor agonist, Romiplostim

Discussion

Our patient presented with an initial episode of severe thrombocytopenia without anaemia, leukopenia and no other apparent aetiology of thrombocytopenia according to the definition based on the existing literature [1] one week after receiving the second dose of Moderna COVID-19 vaccine in a patient without pre-existing thrombocytopenia.

Several cases of de novo thrombocytopenia associated with COVID-19 mRNA vaccination have been reported in the literature [2,3]. According to data from the Vaccine Adverse Effect Reporting System, (VAERS), the estimated reported rate of thrombocytopenia after administration of Moderna and Pfizer vaccines is 0.8 per million doses, which is considerably lower than the incidence of thrombocytopenia in the general population. [4] Although the pathophysiology is not fully understood, it may be explained by cross-reacting antiviral antibodies acting as autoantibodies that tend to bind to platelets and induce their destruction by complement activation or by cellular mechanisms.

According to existing guidelines, the initial treatment of Immune thrombocytopenia is based on the overall risk of bleeding and its severity, with the highest risk in patients with a history

of bleeding, a platelet count of less than $10 \times 10^9/L$ and an age greater than 60 years [5]. However, some patients with minor or no bleeding do not require heavy treatment, as was the case for our patient, so we initiated treatment with corticosteroids only, after which there was a satisfactory progression within a week. However, our patient relapsed with severe thrombocytopenia 6 weeks after the reduction of corticosteroids, requiring treatment with intravenous immunoglobulin, and a thrombopoietin agonist (romiplostim) during the second hospital stay.

Our case contributes to the existing literature to expand the body of evidence to establish a causal relationship as well as to manage this condition with different treatment options. The need for regular assessment and monitoring of platelets is also highlighted in these patients after vaccination. Finally, it should be noted that despite several reported cases of ITP in vaccinated individuals, the incidence of vaccine-related ITP is considerably lower than the incidence of ITP in the general population. To date, vaccines remain the most effective strategy for controlling the current pandemic and should be encouraged despite this side effect profile.

Conclusion

ITP is an increasingly reported complication after mRNA vaccination and treatment should be based on the severity of thrombocytopenia. In addition, the treatment modality should be

adapted on the basis of regular clinical monitoring of the platelet count. Our case adds data and awareness of ITP as a side effect of the COVID 19 mRNA vaccine with possible serious and preventable complications.

References

1. Rodeghiero F, Stasi R, Gernsheimer T, Michel M, Provan D, et al. (2009) Standardization of terminology, definitions and outcome criteria in immune thrombocytopenic purpura of adults and children: report from an international working group. *Blood* 113: 2386-2393.
2. Bennett J, Brown C, Rouse M, Hoffmann M, Ye Z (2020) Immune thrombocytopenia purpura secondary to COVID-19. *Cureus* 12: e9083.
3. Lévesque V, Millaire É, Corsilli D, Rioux-Massé B, Carrier FM (2020) Severe immune thrombocytopenic purpura in critical COVID-19. *Int J Hematol* 112: 746-750.
4. Welsh KJ, Baumblatt J, Chege W, Goud R, Nair N (2021) Thrombocytopenia including immune thrombocytopenia after receipt of mRNA COVID-19 vaccines reported to the Vaccine Adverse Event Reporting System (VAERS). *Vaccine* 39: 3329-3332.
5. Neunert C, Terrell DR, Arnold DM, Buchanan G, Cines DB (2019) American Society of Hematology 2019 guidelines for immune thrombocytopenia *Blood Adv* 3: 3829-3866.