



Case Report

Perineural Cysts at Multiple Spinal Levels Sparing the Sacral Levels in an Adult- A Rare Case Report

Gunjan Jindal*, Aanchal Kataria, Simran Jain, Smriti Khasa

Department of Radiodiagnosis, MMIMSR, Mullana, Haryana, India

*Corresponding author: Gunjan Jindal, Department of Radiodiagnosis, MMIMSR, Mullana, Haryana, India

Citation: Jindal G, Kataria A, Jain S, Khasa S (2022) Perineural Cysts at Multiple Spinal Levels Sparing the Sacral Levels in an Adult- A Rare Case Report. J Surg 7: 1624. DOI: 10.29011/2575-9760.001624

Received Date: 20 September, 2022; Accepted Date: 07 November, 2022; Published Date: 10 November, 2022

Abstract

Perineural cysts are cystic lesions of spinal nerves occurring most commonly in sacral spinal nerves and are mostly asymptomatic. They are routinely detected incidentally on MRI scans. Symptoms are caused by leakage of CSF from the subarachnoid space into the cyst cavity through a ball valve like mechanism and include backache, radiculopathy, sensory dysfunction, bladder/bowel/sexual dysfunction. Till date there is no consensus regarding the definitive treatment of symptomatic PCs, although surgical and microsurgical procedures have good outcome. CT guided percutaneous aspiration, Percutaneous fibrin gel injection under fluoroscopy guidance, lumbo-peritoneal shunts are other treatment options available. We present a case of a 43 year old female who was evaluated for back pain with MRI. . MRI revealed 29 PCs at spinal levels extending from C4-5 to L1-2. She was treated conservatively.

Keywords: Back pain; MRI; Perineural cyst

Introduction

Perineural (Tarlov's) cysts are cystic lesions that occur between perineurium and endoneurium of spinal nerves at the site of posterior root ganglion due to increased cerebrospinal fluid pressure. They were first described in 1938 by Dr. I. M. Tarlov. The most common site of perineural cysts is sacral levels with a female predilection. [1] The estimated prevalence of PCs is between 4.6-9% of population [2]. Some studies have shown that in cases of Fibromyalgia (FM) and Chronic Fatigue Syndrome (CFS) there is high prevalence of perineural cysts. [3] Most cases of PCs are asymptomatic and detected incidentally on MRI scans. Only about 1% of PCs are symptomatic. Symptoms of back pain, paraesthesia, urinary and bladder incontinence, sexual dysfunction occur most often if the location of these cysts is in the sacral region. Till date there is no consensus regarding the definitive treatment of symptomatic PCs, although surgical and microsurgical procedures have good outcome. Asymptomatic PCs or PCs with mild symptoms are treated conservatively [2].

Case Report

A 43-year female presented to orthopaedics OPD with complaints of mid back pain for 2 months. The pain was constant and mild in nature, non-radiating, not associated with change of posture and did not increase on walking. The pain was relieved on rest. Pain did not aggravate on bending forward. No history of numbness, weakness or stiffness was present. No history of any previous surgery or any spinal injection. There was no history of trauma, fever, weight loss or any other significant past medical or family history. No history of any other joint arthritis was present. Bladder and bowel function was normal. No history of any sexual dysfunction.

On examination, no kyphosis was seen, no signs of spina bifida, no focal area of redness was present. No tenderness was elicited. Straight leg raise test was normal and no pain was elicited after extending either leg to more than 60 degrees. The femoral stretch test was also normal. Motor and sensory examination was also normal.

Xray dorso-lumbar spine was normal. Ultrasound

examination was done to rule out any renal stones, which was also normal. MRI dorsal spine was ordered to find the cause of dorsal pain which revealed multiple Tarlov's cysts at all dorsal levels. Visualised sections of cervical and lumbar spine also revealed multiple spinal cysts. Therefore, the examination was extended to cervical and lumbosacral region also. MRI revealed 29 PCs at spinal levels extending from C4-5 to L1-2 i.e., 17 spinal levels. At most of the levels, there were bilateral PCs. Unilateral cysts were present at 5 levels (C5-6, D2-3, D8-9, D11-12 and L1-2 levels). 7 cysts were in cervical spine, 21 in dorsal spine and 1 in lumbar spine. The largest cyst in cervical region was seen at C6-7 level measuring 7X5 mm on right side and 6X6 mm on left side. In dorsal region the largest cyst was seen at D1-2 level measuring 15X10 mm on right side and 15X11 mm on left side. The mean size of PCs was 5.8mm, median was 4 and range was 13. (Figure 1 and 2). As there were multiple PCs in this patient and no significant pathological finding was seen requiring surgical treatment; conservative treatment was given. Analgesics for pain relief were given. Patient was referred to physiotherapy for postural strengthening exercises.

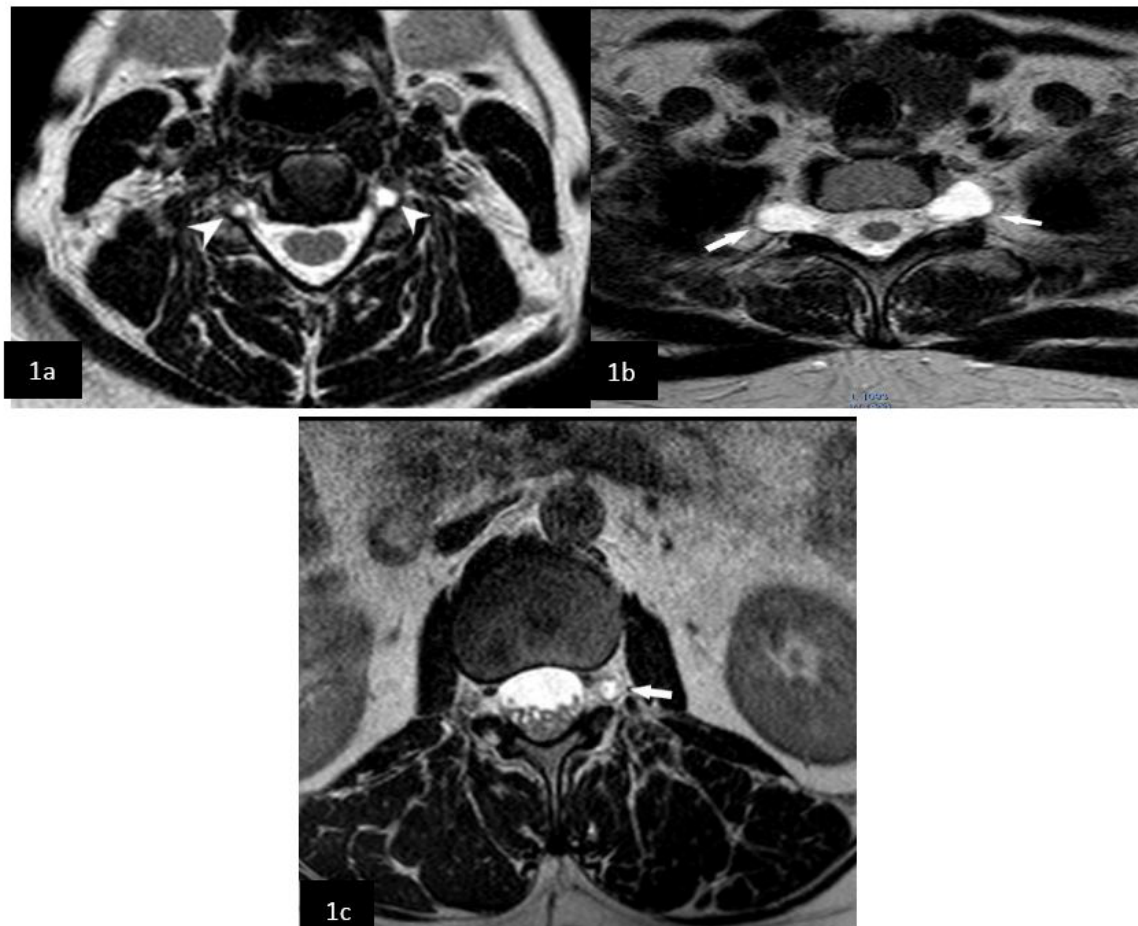


Figure 1: Axial T2W images at cervical, dorsal and lumbar levels. **1a:** Bilateral perineural cysts at cervical level (arrowheads); **1b:** Bilateral perineural cysts at dorsal level (arrows); **1c:** a-Left sided perineural cyst at lumbar level (arrow)

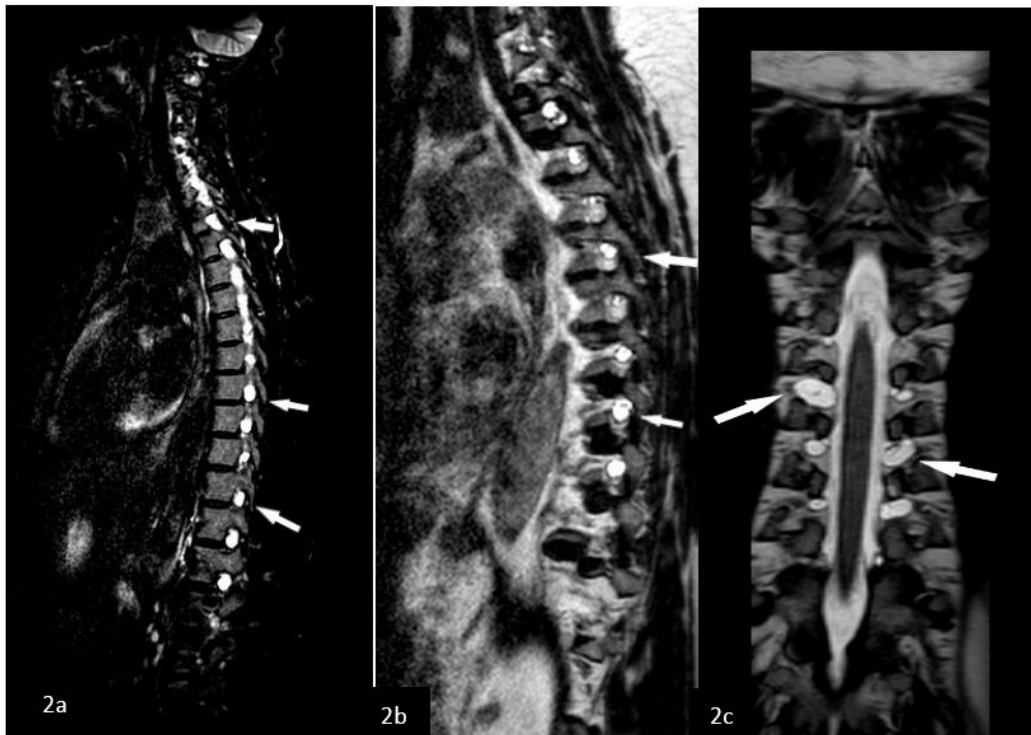


Figure 2: 2a: STIR sagittal image showing multiple perineural cysts at cervical and dorsal levels (arrows)
2b and 2c: VISTA sagittal and coronal images showing multiple perineural cysts at dorsal levels (arrows)

Discussion

Perineural cysts were first described by Dr Tarlov in 1938 during dissection of terminal filum specimens of cadavers. During histopathological analysis, he observed that these cysts were located at the dorsal root ganglion in contrast to meningeal diverticula which are located proximal to dorsal root ganglion. PCs also demonstrated nerve fibres within the cysts. Although these cysts can occur along any spinal nerve, the most common location of PCs is S-2 and S-3 nerve roots. [4] Only about 1% of these cysts are symptomatic and most of the symptomatic PCs are located in the sacral spine. [5] In a retrospective study of MRI of spine done by Kozlowski et al et al, PCs were detected in 9% of patients and the most common location was sacral region. In most patients, a single cyst was documented, and the longest dimension of cyst was 11.72mm. [6,7] Symptoms are caused by leakage of CSF from the subarachnoid space in to the cyst cavity through a ball valve like mechanism. Most of the cysts remain asymptomatic but some can enlarge during the course of time and cause symptoms due to the stretching of nerve roots. We could find only one similar case reported in literature in which there were multiple PCs along entire spine with sparing of sacrum. They reported 39 PCs of varying sizes at 17 spinal levels and patient was treated conservatively. [8] Many non-surgical treatment options are being done to relieve

the symptoms which include CT guided percutaneous aspiration, Percutaneous fibrin gel injection under fluoroscopy guidance, lumbo-peritoneal shunts are other treatment options available. Percutaneous cyst drainage with fibrin glue placement in the cyst can relieve the symptoms, however, one study documented the occurrence of aseptic meningitis in as high as 75% of patients after this treatment, hence this is not a favoured treatment option. [9] Some other non-surgical treatment options include lumbar CSF drainage, however, no consensus regarding the treatment of PCs is present. Surgical treatments include cyst resection, cyst fenestration and imbrication, cyst shrinkage. Surgery is preferred in patients with large cyst diameter, sensory disturbance, bladder/ bowel dysfunction and in those patients who experience increased pain during postural changes and Valsalva manoeuvre.² In our case, there were no such symptoms and hence only conservative treatment was given.

Conclusion

PCs occur most frequently in sacral spinal nerves and can cause symptoms. However, if no cause of pain in dorsal spine is found, then also PCs should be kept in mind as a remote possibility and MRI examination should be done. PCs at this location if associated with mild symptoms can be treated conservatively.

References

1. Burdan F, Mocarska A, Janczarek M (2013) Incidence of spinal perineurial (Tarlov) cysts among East-European patients. *PLoS One* 8: e71514.
2. Acosta FL, Quinones-Hinojosa A, Schmidt MH, Weinstein PR (2003) Diagnosis and management of sacral Tarlov cysts: case report and review of the literature. *Neurosurgical focus* 15: 1-7.
3. Hulens M, Bruyninckx F, Dankaerts W, Rasschaert R (2021) High prevalence of perineural cysts in patients with fibromyalgia and chronic fatigue syndrome. *Pain Medicine* 22: 883-890.
4. Tarlov IM (1938) Perineural cysts of the spinal nerve roots. *Arch Neurol Psychiatry* 40: 1067-1074.
5. Paulsen RD, Call GA, Murtagh FR (1994) Prevalence and percutaneous drainage of cysts of the sacral nerve root sheath (Tarlov cysts). *AJNR Am J Neuroradiol* 15: 293-299.
6. Kozłowski P, Kalinowski P, Kozłowska M (2021) Spinal Perineural Cysts among European Patients. *Journal of Neurological Surgery Part A: Central European Neurosurgery* 2021.
7. Lucantoni C, Than KD, Wang AC (2011) Tarlov cysts: a controversial lesion of the sacral spine. *Neurosurg Focus* 31: E14.
8. Tokgöz MA, Kılıçaslan ÖF, Parlak AE (2021) Multiple perineural cysts in the cervical, thoracic, and lumbar vertebrae of a mature individual. *Joint Diseases and Related Surgery* 32: 262.
9. Voyadzis JM, Bhargava P, Henderson FC (2001) Tarlov cysts: a study of 10 cases with review of the literature. *J Neurosurg* 95: 25-32.