



Case Report

Nonocclusive Mesenteric Ischemia after Introduction of Chemotherapy for Esophageal Cancer: Report of Two Cases and Review of the Literature

Yuki Shin^{1*}, Yuichiro Nakashima¹, Manabu Yamamoto¹, Keiichi Shiokawa¹, Yoshiaki Fujimoto¹, Tomonori Nakanoko¹, Hideo Uehara¹, Masahiko Sugiyama¹, Mitsuhiro Ota¹, Emi Onishi², Yoshihiro Matsumoto², Tomonari Shimagaki², Yohei Mano², Keishi Sugimachi², Masaru Morita¹, Yasushi Toh¹

¹Department of Gastroenterological Surgery, National Hospital Organization Kyushu Cancer Center, Fukuoka, 811-1395, Japan

²Department of Hepatobiliary-Pancreatic Surgery, National Hospital Organization Kyushu Cancer Center, Fukuoka, 811-1395, Japan

*Corresponding author: Yuki Shin, Department of Gastroenterological Surgery, National Hospital Organization Kyushu Cancer Center, 3-1-1 Notame, Minami-ku, 811-1395 Fukuoka, Japan.

Citation: Shin Y, Nakashima Y, Yamamoto M, Shiokawa K, Fujimoto Y, et al. (2021) Nonocclusive Mesenteric Ischemia after Introduction of Chemotherapy for Esophageal Cancer: Report of Two Cases and Review of the Literature. Ann Case Report 6: 699. DOI: 10.29011/2574-7754.100699

Received Date: 16 September, 2021; **Accepted Date:** 21 September, 2021; **Published Date:** 25 September, 2021

Abstract

Background: Non-occlusive mesenteric ischemia (NOMI) causes intestinal necrosis due to irreversible ischemia of the intestinal tract despite the absence of organic obstruction in the mesenteric blood vessels. It has an extremely poor prognosis. We report two cases of NOMI following chemotherapy for esophageal squamous cell carcinoma.

Case presentation: Case 1 was a 74-year-old man who received 5-fluorouracil (5-FU) and cisplatin (CDDP) for esophageal squamous cell carcinoma. On day seven of administration, the patient complained of abdominal pain with diarrhea. Dynamic computed tomography (CT) showed mesenteric ischemia and massive hepatic portal venous gas, and he was diagnosed with NOMI. Case 2 was a 65-year-old man with diabetes who received chemoradiotherapy (41.4 Gy/23 Fr, 5-FU + CDDP) for hypopharyngeal and esophageal squamous cell carcinoma. On day nine of administration, the patient complained of abdominal pain with diarrhea. Dynamic CT showed mesenteric ischemia and massive hepatic portal venous gas, and he was diagnosed with NOMI.

In both cases, the patients were deemed ineligible for surgery due to their poor general condition, and they died the same day as they were diagnosed.

Conclusions: In both cases, 5-FU and CDDP were given before the onset of NOMI, and an association between the onset of NOMI and the chemotherapy was suspected. In general, mesenteric ischemia after administration of anticancer therapy is rare, and only a few cases have been reported.

Keywords: Nonocclusive Mesenteric Ischemia; Esophageal Cancer; Chemotherapy; Cisplatin; 5-Fluorouracil

Introduction

Non-occlusive mesenteric ischemia (NOMI) causes intestinal necrosis due to irreversible ischemia of the intestinal tract despite the absence of organic obstruction in the mesenteric blood vessels. It has an extremely poor prognosis, with a mortality rate

of approximately 50% [1]. The main risk factors for NOMI include advanced age, dialysis, heart failure, use of certain drugs (digitalis, diuretics, catecholamines), arrhythmia, diabetes, and dehydration [2]. A few cases of NOMI that developed in patients with cancer after administration of chemotherapy have been reported [3-7]. Development of NOMI after administration of chemotherapy for esophageal cancer has not been reported to our knowledge. We herein report our experience with two patients who developed NOMI following chemotherapy for esophageal cancer.

Case presentation

Case 1

A 74-year-old man presented with caloric intake difficulty and weight loss of 5 kg over 2 months. Upper gastrointestinal endoscopy revealed esophageal cancer in the middle thoracic esophagus (Figure 1A). Computed tomography (CT) showed a bulky primary lesion of esophageal cancer infiltrating the left main bronchus (Figure 1B), multiple pulmonary metastases (Figure 1C), and multiple nodal metastases in the neck, mediastinum, and abdomen. Based on these findings, he was diagnosed with esophageal squamous cell carcinoma (cStage IVB, T4bN4M1) according to the Union for International Cancer Control (UICC) 8th edition [8]. To improve his poor nutritional status (albumin, 2.7 g/dL; total cholesterol, 175 mg/dL; BMI, 19.9 kg/m²), gastropexy was performed, and enteral nutrition was introduced ten days prior to chemotherapy. On the three days after introduction of chemotherapy with cisplatin (CDDP) (80 mg/m², day 1) and 5-fluorouracil (5-FU) (800 mg/m², day 1-5), diarrhea was observed. Symptomatic treatment was performed by prescribing *Clostridium butyricum* and slowing the administration rate of enteral nutritional supplements. Seven days after administration of chemotherapy, the patient developed acute abdominal pain with a fever of 37.2°C. His blood pressure was 151/82 mmHg, his pulse rate was 155/min, and his respiratory rate was 23/min, with an O₂ saturation of 89% on 3 L of oxygen. His abdomen was distended with diffuse tenderness with guarding and rigidity. Laboratory evaluation revealed an elevated white blood cell count, C-reactive protein level, and renal dysfunction level (BUN, Cr) of 8.2×10⁹/L, 96.6 mg/L, and 40.6 mg/dL (BUN), 0.86 mg/dL (Cr), respectively. Dynamic CT showed a massive amount of hepatic portal venous gas extending to the superior mesenteric vein, a dilated gastrointestinal tract with pneumatosis intestinalis, and segmental poor enhancement of the bowel wall, with no thrombi in the superior mesenteric artery (Figure 2). These findings led to the diagnosis of NOMI. The patient was deemed ineligible for surgery due to his poor general condition, and he died six hours after the onset of symptoms.

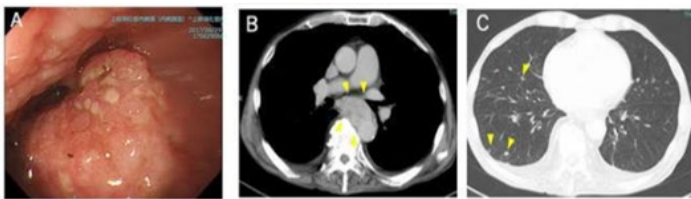


Figure 1: **A:** Upper gastrointestinal endoscopy revealed esophageal cancer in the middle thoracic esophagus. **B:** Computed Tomography (CT) revealed a bulky primary lesion of esophageal cancer infiltrating the left main bronchus (arrows). **C:** Computed Tomography (CT) revealed multiple pulmonary metastases (arrows).

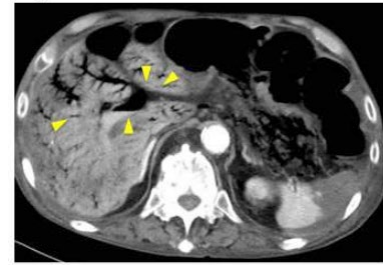


Figure 2: Axial section of abdominal computed tomography (CT) showed a massive amount of hepatic portal venous gas (arrows) and extensive intestinal ischemia.

Case 2

A 65-year-old man with diabetes presented with dysphagia and weight loss of 7 kg in one month. Upper gastrointestinal endoscopy revealed esophageal cancer in the lower thoracic esophagus with all circumferences-related stenosis (Figure 3A), and the neoplastic lesion spread from the hypopharynx to the larynx broadly (Figure 3B). CT showed multiple swollen lymph nodes in the neck, mediastinum, and abdomen (Figure 3C). Thus, he was diagnosed with hypopharyngeal squamous cell carcinoma (cStage IVA, cT4aN2M0) and esophageal squamous cell carcinoma (cStage III, cT3N3M0) according to the UICC 8th edition [3]. His nutritional status was poor (albumin, 2.9 g/dL; Tc, 195 mg/dL; BMI, 14.2 kg/m²). His right vocal cord was completely paralyzed, accompanied by aspiration pneumonitis. Tracheotomy and enteral feeding with a nasogastric tube were performed. Two weeks after introduction of enteral feeding, preoperative chemoradiotherapy (41.4 Gy/23 Fr) with CDDP (80 mg/m², day 1) and 5-FU (800 mg/m², day 1-5) was introduced. On treatment day 1, he had diarrhea with no stomachache, and intestinal medicine (*Clostridium butyricum*) was prescribed. On the morning of treatment day 9, he experienced three episodes of diarrhea and two episodes of vomiting followed by acute abdominal pain. On examination, his body temperature was 36.2 °C, his blood pressure was 80/50 mmHg, his pulse rate was 150 /min, and his respiratory rate was 23/min, with an O₂ saturation of 95% on room air. His abdomen was distended, with diffuse tenderness with guarding and rigidity. Laboratory evaluation revealed an elevated white blood cell count, C-reactive protein level and renal dysfunction level of 9.3×10⁹/L, 84 mg/L, and 24.3 mg/dL (BUN), 1.33 mg/dL (Cr), respectively. Dynamic CT showed emphysema in a wide range of intestinal tract regions ranging from the esophagus to the colon, and a massive amount of hepatic portal venous gas extending to the superior mesenteric vein (Figure 4), without thrombosis in the superior mesenteric artery. These findings led to the diagnosis of NOMI. The patient was deemed ineligible for surgery due to his poor general condition, and he died five hours after the onset of symptoms.

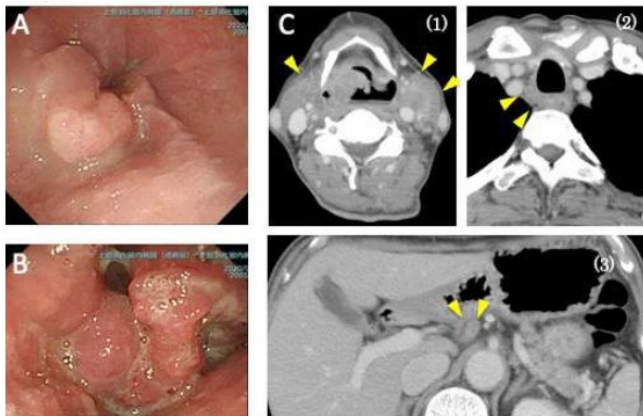


Figure 3: **A:** Upper gastrointestinal endoscopy revealed that the esophageal lumen was filled with necrotic components from the primary esophageal cancer. **B:** Upper gastrointestinal endoscopy revealed that the neoplastic lesion spread from the hypopharynx to the larynx broadly. **C:** Computed tomography (CT) showed multiple swollen lymph nodes in the neck (1), mediastinum (2), and abdomen (3).

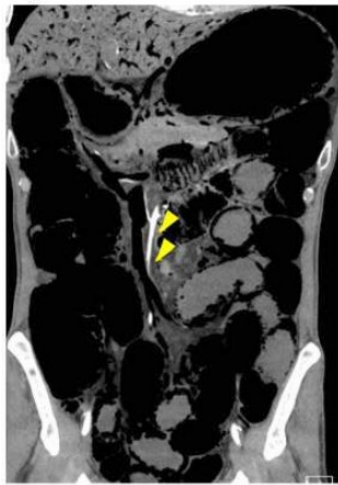

Figure 4: Coronal section of abdominal Computed Tomography (CT) showed a massive amount of hepatic portal venous gas and extensive intestinal ischemia, and blood flow of the superior mesenteric artery was maintained (arrows).

Discussion

We experienced two cases of NOMI that developed early after the introduction of chemotherapy for esophageal cancer.

Both patients were relatively old and had poor nutritional status with severe esophageal obstruction due to esophageal cancer, and enteral feeding was introduced prior to 5-FU/CDDP combination chemotherapy. In both cases, diarrhea developed a few days after the introduction of chemotherapy, and after a few more days, these abdominal symptoms rapidly worsened to an acute abdomen, resulting in a diagnosis of NOMI and deterioration.

NOMI was reported for the first time in 1958 as an intestinal necrosis in three patients with heart failure [9]. The pathogenesis of NOMI can be explained as a non-occlusive reduction in arterial blood flow, most commonly due to primary splanchnic vasoconstriction [10]. Furthermore, the known risk factors for NOMI include cardiovascular disease (heart failure, aortic insufficiency, arrhythmia, and arteriosclerosis), hypovolemic dynamics (dehydration and bleeding), sepsis, dialysis, and administration of vasoconstrictive medications [11, 12]. To date (2020), only seven cases of NOMI during chemotherapy have been reported. (Table 1) [3-7]. Seven of the now nine reported cases (including the current cases) were elderly individuals over 70 years of age (median age, 74 years; range, 63–80 years), with no specific commonality in their medical history. Six cases had aerodigestive tract cancer, two cases had esophageal cancer (current cases), two cases had oropharyngeal cancer, one case had maxillary cancer, and one case had laryngeal cancer. With regard to the chemotherapy regimen administered, a platinum-based regimen was adopted in 7 cases, and 5-FU was included in 6 cases. In all cases, NOMI developed after initial chemotherapy, and seven of nine cases developed NOMI within ten days after chemotherapy initiation (median, 6 days; range, 2–19 days). The initial symptom in eight of nine cases was stomachache, and enhanced CT was performed for the diagnosis of NOMI. Surgery was performed in seven patients, and one patient who underwent surgery died. Diarrhea and stomachache are relatively common, and they are not specific adverse events of 5-FU/CDDP combination chemotherapy for advanced esophageal cancer (grade 3 or higher 2% [13]). The alimentary canal mucosal disorder associated with 5-FU results from a direct mucosal epithelium cell disorder accompanied with the suppression of cell division and an infection accompanied with the immunologic inhibition [14]. In addition, hydration with cisplatin may result in a body fluid imbalance and a rapid osmolar change, which may affect the intestinal mucosa. These mucosal disturbances and impaired blood flow in the gastrointestinal tract due to the 5-FU/CDDP regimen may have contributed to the pathogenesis of NOMI in the two current cases.

Author	Age/Sex	Cancer region	Cancer type	Comorbidity	Chemotherapy regimen	Initial chemotherapy	The days after the chemotherapy initiation	Side effect	Symptoms of NOMI	Diagnosis Method	Surgery	Outcome	Enteral nutrition	Alb (g/dl)	Year reported
[8]	80/F	Lung cancer	Adenocarcinoma	Sderoderma	Gefitinib	No	※34	Liver dysfunction	Stomachache	CT	Yes	Survival	No	NR	2013
[9]	74/F	Malignant melanoma	Melanoma	None	Paditaxel (Carboplatin)	Yes	2	None	Stomachache	CT	Yes	Survival	No	NR	2015
[10]	79/M	Prostate cancer	NR	Prostatectomy	DOC	Yes	19	Neutropenia	Stomachache, Fever	CT	Yes	Survival	No	NR	2017
[10]	74/M	Oropharyngeal cancer	NR	None	CDDP, 5-FU, DOC	Yes	6	Neutropenia	Stomachache, Fever	CT	Yes	Death (3 weeks pneumonia)	No	NR	2017
[11]	74/M	Oropharyngeal cancer	Squamous cell carcinoma	Pneumonia	CDDP, 5-FU, DOC	Yes	9	Neutropenia, diarrhea	Abdominal distension, Fever	CT	Yes	Survive	No	NR	2018
[12]	63/F	Maxillary cancer	Undifferentiated cancer	Schizophrenia	CDDP, 5-FU, DOC	No	6	Neutropenia	Stomachache, Syncope	CT	Yes	Survive	No	3	2020
[12]	71/M	Laryngeal cancer	Squamous cell carcinoma	Alcoholic hepatitis	CDDP, 5-FU, DOC	Yes	5	Neutropenia	Stomachache, Vomiting	CT	Yes	Survive	No	3	2020
Our-date 1	74/M	Esophageal cancer	Squamous cell carcinoma	None	CDDP, 5-FU	Yes	7	Diarrhea	Stomachache	CT	No	Death (same day)	Yes, 17 days	2.7	2020
Our-date2	66/M	Hypopharyngeal cancer	Squamous cell carcinoma	Diabetes	CDDP, 5-FU	Yes	9	Diarrhea, Drug eruption	Stomachache	CT	No	Death (same day)	Yes, 19 days	2.9	2020

DOC: Docetaxel; **CDDP:** Cisplatin; **NR:** Not Reported; ※Days after chemotherapy was discontinued.

Table 1: Seven cases of NOMI during chemotherapy have been reported.

In contrast, some cases of NOMI attributable to transluminal enteral feeding have been reported [15]. Previous reports have suggested that the mechanism of feeding-related NOMI is as follows: First, enteral feeding causes intravascular dehydration for an osmolar principle. In the presence of hypoperfusion, the intestinal tract suffers from ischemia without obtaining the oxygen to meet the increased demand that results from enteral feeding. Second, enteral nutrition administered on the background of ileus allows bacterial overgrowth, causing accumulation of intraluminal gas and toxins that injure the mucosa [16]. In the two current cases, these adverse effects of enteral nutrition on the mucosa of the gastrointestinal tract may have further increased the risk of developing NOMI.

Conclusion

We experienced two cases of NOMI immediately after the introduction of chemotherapy with 5-FU and cisplatin for esophageal squamous cell carcinoma. There are few reports of NOMI as an adverse event associated with chemotherapy, but the development of NOMI in patients with advanced cancer undergoing chemotherapy could be fatal. The 5-FU/CDDP regimen is the standard primary treatment for advanced esophageal cancer and is often combined with enteral nutrition, which may be a risk factor for the development of NOMI. A review of previously reported cases of NOMI during chemotherapy, including the two current cases, suggests that vigilant follow-up against progression to NOMI should be carried out for patients who develop abdominal symptoms at the time of initial introduction of 5-FU/CDDP chemotherapy.

Acknowledgements

This work was not supported by any grant or funding.

Disclosures

The authors report no conflicts of interest.

References

- Trompeter M, Brazda T, Remy CT, Vestring T, Reimer P. (2002) Non-occlusive mesenteric ischemia: etiology, diagnosis, and interventional therapy. *Eur Radiol.* 12: 1179-1187.
- Suzuki O, Kondo H, Furukawa A, Kawai K, Yamamoto M, Hirata K. (2015) The Treatment and Diagnosis of Non-occlusive Mesenteric Ischemia (NOMI). *J Abdom Emerg Med.* 35: 177-185.
- Awano N, Kondoh K, Andoh T, Ikushima S, Kumasaka T, Takemura T. (2013) Three cases of lung carcinoma complicated by gastrointestinal necrosis and perforation. *The Japan Lung Cancer Society.* 53: 809-814.
- Matsuzawa M, Harada K, Hosomura N, Amemiya H, Ando N, Inozume T, et al. (2015) Non-occlusive mesenteric ischemia after chemotherapy for metastatic melanoma. *The Journal of Dermatology.* 42: 105-106.
- Wada T, Katsumata K, Kuwahara H, Matsudo T, Murakoshi Y, Shigoka M, et al. (2017) Two cases of non-occlusive mesenteric ischemia that developed after chemotherapy. *Jpn J Cancer Chemother.* 44: 1396-1398.
- Tanaka H, Tsukahara K, Okamoto I, Kojima R, Hirasawa K, Sato H. (2018) A case of septicemia due to nonocclusive mesenteric ischemia occurring in induction chemotherapy. *Case Rep Otolaryngol.* 2018: 7426819.
- Yoshida M, Kobayashi T, Hyodo M. (2020) Two cases of non-occlusive mesenteric ischemia after chemotherapy for head and neck cancer. *Pract. otol. (Kyoto).* 113: 175-181.
- Brierley JD, Gospodarowicz MK & Wittekind C. (2017) *TNM Classification of Malignant Tumours*, 8th ed.
- Ende N. (1958) Infarction of the bowel in cardiac failure. *N Engl J Med.* 258: 879-881.
- Clair DG, Beach JM. (2016) Mesenteric Ischemia. *N Engl J Med.* 374: 959-968.
- Lawlor DK, Inculet RI, Malthaner RA. (1998) Small-bowel necrosis associated with jejunal tube feeding. *Can J Surg.* 41: 459-62.
- Jorba R, Fabregat J, Borobia FG, Torras J, Poves I, Jaurrieta E. (2000) Small bowel necrosis in association with early postoperative enteral feeding after pancreatic resection. *Surgery.* 128: 111-112.
- Hisatomi K, Kagawa M, Higure I, Sugiura T, Nagahuti Y, Kuroda Y, et al. (1993) Severe enteritis associated with MTX/5FU therapy. Report of 2 cases. *Japanese Journal of Cancer Clinics.* 39: 638-642.
- Bleiberg H, Conroy T, Paillot B, Lacave A J, Blijham G, Jacob J H, et al. (1997) Randomised phase II study of cisplatin and 5-fluorouracil (5-FU) versus cisplatin alone in advanced squamous cell oesophageal cancer. *Eur J Cancer.* 33: 1216-1220.
- Kurita D, Fujita T, Horikiri Y, Sato T, Fujiwara H, Daiko H. (2019) Non-occlusive mesenteric ischemia associated with enteral feeding after esophagectomy for esophageal cancer: report of two cases and review of the literature. *Surgical Case Reports.* 5: 1-9.
- Marvin RG, McKinley BA, McQuiggan M, Cocanour CS, Moore FA. (2000) Nonocclusive bowel necrosis occurring in critically ill trauma patients receiving enteral nutrition manifests no reliable clinical signs for early detection. *Am J Surg.* 179: 7-12.