



Case Report

Laparoscopic Resumption of Gastrointestinal Continuity of Unused Short Bowel Syndrome after Complicated RYGB Internal Hernia: A Case Report of the Unexpected Outcome

Mohammed Alnaami¹, Taghreed Albalawi^{2*}, Khayal Alkhayal³, Hussam Alamri³, Rafif Matter⁴

¹Professor of Surgery, Upper GI Surgery Unit, General Surgery Division, Department of Surgery, King Saud University, Riyadh, Kingdom of Saudi Arabia

²Minimally Invasive and Bariatric Surgery Fellow, Upper GI Surgery Unit, General Surgery Division, Department of Surgery, King Saud University, Riyadh, Kingdom of Saudi Arabia

³Professor of Surgery, Colorectal Surgery Unit, Department of Surgery, King Saud University, Riyadh, Kingdom of Saudi Arabia

⁴Assistant Professor and Head of the Upper GI Surgery Unit, Department of Surgery, King Saud University, Riyadh, Kingdom of Saudi Arabia

⁵General Surgery Senior Resident, Upper GI Surgery Unit, Department of Surgery, King Saud University, Riyadh, Kingdom of Saudi Arabia

***Corresponding author:** Taghreed Albalawi, Minimally Invasive and Bariatric Surgery Fellow, Department of Surgery, King Saud University, Riyadh, Saudi Arabia

Citation: Alnaami M, Albalawi T, Alkhayal K, Alamri H, Matter R (2022) Laparoscopic Resumption of Gastrointestinal Continuity of Unused Short Bowel Syndrome after Complicated RYGB Internal Hernia: A Case Report of the Unexpected Outcome. Ann Case Report. 7: 1023. DOI: 10.29011/2574-7754.101023

Received Date: 31 October 2022; **Accepted Date:** 03 November 2022; **Published Date:** 07 November 2022

Abstract

Internal hernia (IH) has been recognized as a potential complication of RYGB, with an incidence of 1- 4.7%. Delayed diagnosis of IH results in a higher rate of complications. We present a complicated case of a complicated case of Short Bowel Syndrome (SBS) after massive small bowel resection resulting from a delayed diagnosis of IH post-RYGB. We performed laparoscopic resumption of bowel continuity after the patient was precluded from the intestinal transplantation (ITx) program. This procedure aimed to allow a normal digestion process, maximum absorption of nutrients, and better quality of life. However, after the resumption of the bowel continuity of the unused SBS, the patient has an unexpected and efficient enteral caloric consumption to a degree that parenteral nutrition (PN) is partially used now, hoping also to be stopped in the very near future.

Keywords: Internal hernia (IH), Roux-en-Y gastric bypass (RYGB), short bowel syndrome (SBS), intestinal transplantation (ITx).

Introduction

Bariatric surgery has emerged as the most reliable method for weight loss and remission of associated comorbid diseases in individuals living with obesity [1]. While different operations exist to achieve this goal, Roux-en-Y gastric bypass (RYGB) provides substantial weight loss [2] and significant improvement of medical comorbidities [3,4]. However, compared to other bariatric procedures, internal hernia (IH) has been recognized as a potential complication of RYGB, with an incidence of 1- 4.7% [5,6]. This complication can present sub-acutely with recurrent abdominal pain, or as an acute intestinal obstruction with or without small bowel necrosis, especially when diagnosis and surgical intervention are delayed [7,8]. Diagnosis of IH constitutes a particular challenge because it can only be disclosed in symptomatic patients. Furthermore, clinical, biological, and radiological findings of IH are not specific except in the case of acute obstruction, which often requires a high index of suspicion and the expertise of the radiologist and bariatric surgeon for accurate interpretation. Unfortunately, delayed diagnosis results in a higher rate of conversion from laparoscopic to open interventions, and massive small bowel resection, with short bowel syndrome (SBS) as a consequence [9]. Here, we are reporting a complicated case of SBS after massive small bowel resection resulting from a delayed diagnosis of IH post-RYGB. We performed laparoscopic resumption of bowel continuity after the patient was precluded from the intestinal transplantation (ITx) program. This procedure aimed to allow a normal digestion process, maximum absorption of nutrients, and better quality of life. However, after the resumption of the bowel continuity of the unused SBS, the patient has an unexpected and efficient enteral caloric consumption to a degree that parenteral nutrition (PN) is partially used now, hoping also to be stopped in the very near future.

Case Presentation

A 35-year-old lady, known living with obesity since the age of 14 years. In March 2013, her BMI was 51 kg/m² associated with type 2 diabetes mellitus when she underwent laparoscopic RYGB. She had an uneventful postoperative period until August 2017, when she experienced recurrent abdominal pain, which importance was overlooked by some medical centers. After a few days of her initial symptoms, she presented again to a local hospital emergency room (ER) with severe and constant epigastric abdominal pain that was cramping in nature, radiating to the back, and associated with hematemesis and absolute constipation. At the time of the presentation, she was looking very sick and collapsed

in ER due to septic shock. She was resuscitated and transferred immediately to the operating room (OR) for exploratory laparotomy. Operative findings revealed small bowel gangrene, twisting of the mesentery with herniation of the small bowel into the space behind the jejunostomy distal anastomosis. After resecting the diseased small bowel, the duodenum and a small segment (~20 cm) of the upper part of the jejunum were looking healthy and preserved. The jejunal end was brought out with a Foley catheter as a jejunostomy-cutaneous fistula through the left flank. The gastric pouch looked healthy and was exteriorized as a gastro-cutaneous fistula through the epigastrium. The remaining terminal ileum (~10 cm) also persevered as a closed-ended segment (Figure 1). The patient was then stabilized and managed in the intensive care unit (ICU). Later, her condition gradually improved, ambulated out of bed, and discharged from ICU to the ward with one-to-one nursing care. The jejunostomy output averaged ~1000 ml/day, replaced with intravenous fluids, and 2600 calories/day of PN. Her stay was uneventful until October 2018, she was transferred to our hospital as a case of SBS for further management. We continued a conservative management approach with regular visits to a higher organ transplant center to consider her for intestinal transplantation (ITx). Later, she became a candidate for ITx, conditioned that she loses more weight, as her BMI was 31kg/m² at that time. Despite her long waiting time to find a matching donor, and not considering any further surgery to rejoin the small bowel as per the ITx surgeon, she was precluded from the ITx program due to persistent high antibody titers. At this moment, we decided to operate on her to resume the bowel continuity to use it for enteral digestion and absorption and regain a better quality of life. Therefore, in December 2021 she consented to diagnostic laparoscopy and proceeded with what surgeons found appropriate, explaining risks and possible conversion to open surgery. Laparoscopic extensive adhesiolysis was done through sequential port insertions until almost the whole abdominal cavity was visualized. The gastric pouch fistula was taken down and gastro-gastric anastomosis was performed successfully using endo-linear stapling and double layer handsewn repair, which was also confirmed by negative gas leak testing using the gastroscope. Then the terminal ileum (TI) segment was identified and mobilized carefully. Afterward, the jejunostomy-cutaneous fistula was taken down using the endo-linear stapler at its exit on the abdominal wall. The two ends of the jejunum and ileum were joined as end-to-end double layer handsewn anastomosis. The patency of this distal anastomosis was also confirmed by the free passage of the intraoperative gastrointestinal scope with negative gas leak testing (Figure 2). Two Jackson Pratt (JP) drains were inserted near both anastomoses respectively. The postoperative course was uneventful as she started to drink and eat slowly along with PN supplementation every other day. She experienced a single episode of transient hepatic encephalopathy resulting from a high serum

ammonia level, due to a rapid increase of caloric intake orally (refeeding syndrome). This was managed by adjusting the amino acids in the PN and adding arginine. Eventually, she was discharged home in good condition on home PN service with regular multidisciplinary outpatient follow-ups. Teduglutide, a glucagon-like peptide-2, was ordered to improve intestinal absorptive functions with time, hoping to discontinue PN when adequate absorption is achieved.

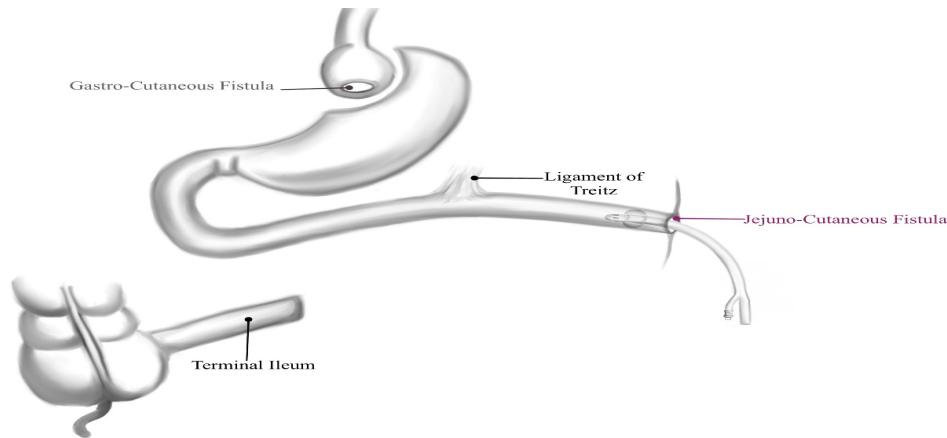


Figure 1: Small bowel configuration after resection of necrotic segments due to complicated IH.

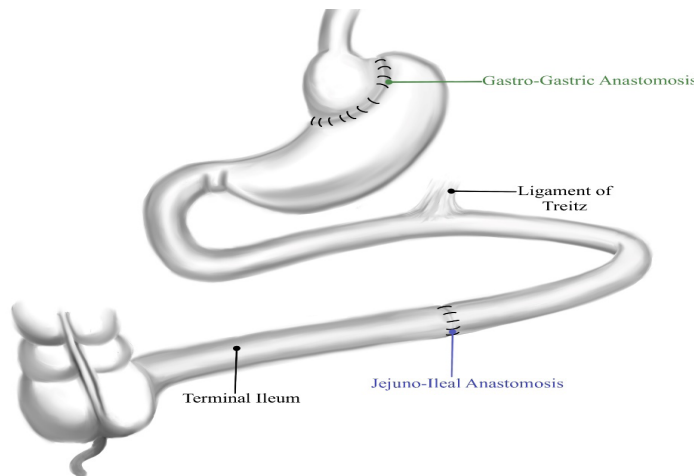


Figure 2: Small bowel configuration after resuming the bowel continuity.

Discussion

Despite the advent of newer bariatric surgical procedures over the last few decades with excellent outcomes, RYGB still holds its place as one of the oldest and most important restrictive and malabsorptive metabolic bariatric procedures, especially for patients who are suffering from gastroesophageal reflux disease (GERD) and/or metabolic syndrome [10]. However, IH is a peculiar complication of this procedure with an incidence rate ranging from 0.2% to 8%, with variability related to the chosen surgical technique [11-12].

The diagnosis of IH still represents a challenge for physicians who do not have specific knowledge of bariatric techniques. Moreover, this diagnosis is often difficult because the clinical presentation can be vague and not easy to recognize. Diagnosis of IH is usually disclosed by the Computerized Tomography of the Abdomen (CTA), preferably with both intravenous and oral contrasts, or more accurately using 3D CTA images [13]. Meticulous interpretation of the CTA by both the radiologist and bariatric surgeon is very crucial to establish the diagnosis of IH, and for making an appropriate and timely decision on the treatment plan. Delayed diagnosis may lead

to extensive intestinal resections due to advanced ischemia, as happened in our case, or even mortality [14].

There are two sites where an IH can occur after a Roux-en-Y limb fashioned in an ante-colic way: 1) Petersen's defect, the space created between the mesentery of the alimentary limb and the transverse colon mesentery; 2) The mesojejunal defect, due to the interruption of the mesentery at the site of the jejuno-jejunal anastomosis. A third possible site of IH is through; 3) the transverse mesocolon, in the case of transmesocolic passage of the alimentary limb (Figure 3).

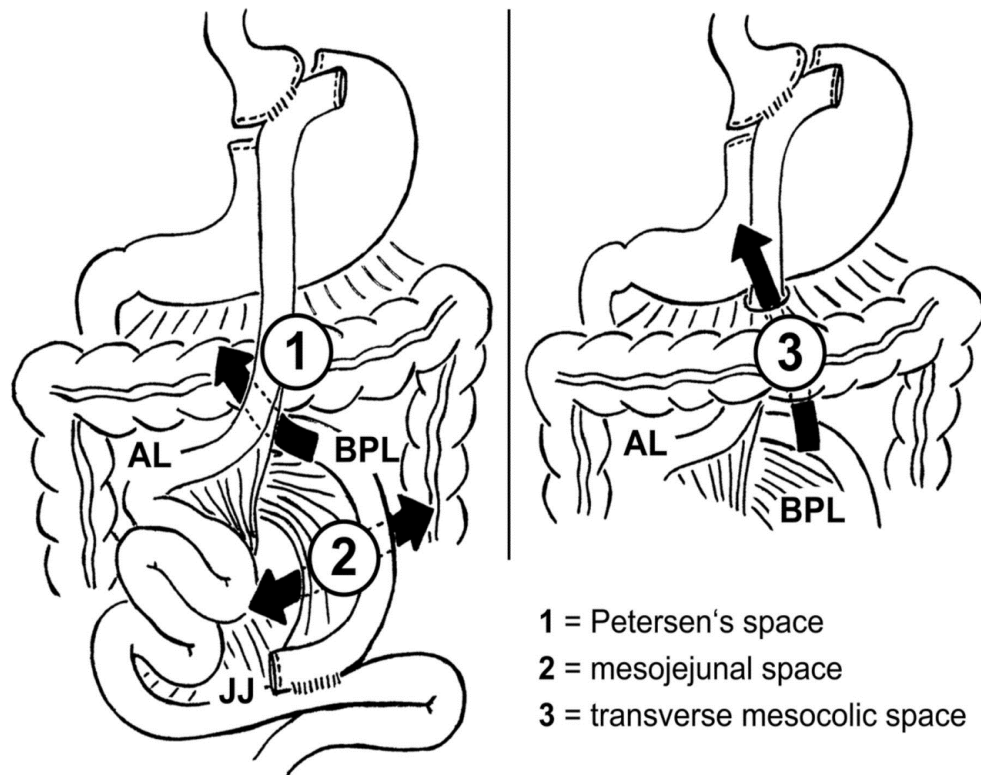


Figure 3: Potential internal hernia spaces after Laparoscopic Roux-en-Y Gastric Bypass procedure. (Adopted from Däster S. et al. [12] with permission).

According to the operative report of the emergency surgery, this patient experienced IH through the mesojejunal defect with massive small bowel gangrene that required resection resulting in SBS. Unfortunately, potential IH defects were not closed during her original LRYGB. However, a continuous debate still exists among bariatric surgeons with regard to the importance and necessity for closure versus the non-closure of mesenteric defects during LRYGB. A recently published systematic review and meta-analysis have shown moderate evidence in favor of closing mesenteric defects of potential IH spaces during LRYGB [15]. Another more recent RCT showed a significant reduction in the IH occurrence after 5 years from the closure of the mesenteric defects of the LRYGB [16]. Short bowel syndrome (SBS) occurs as a complication of emergency abdominal surgical procedures in approximately 25% of cases [17]. In that series, operations for the treatment of morbid obesity were the third most common surgical procedure that resulted in SBS.

When faced with patient's post-RYGB who has lost a significant portion of the small intestine, reconstruction of the gastrointestinal tract represents its own unique issues and challenges. First; at the level of the stomach, restoration of gastric anatomy with gastro-gastrostomy can be done to increase the quantity of food for digestion and therefore calories and nutrients for the patient to consume. This procedure can be facilitated by having a sizable gastric pouch; however, if the gastric pouch is too small, one has to do esophagogastric anastomosis. Second; if the alimentary limb remains viable, it can be taken off the gastric pouch and re-connected to the end of the biliopancreatic limb to increase the length of the functional bowel for better absorption. With the advent of newer medications that increase the functional absorption of the remaining small intestine of SBS, resuming bowel continuity as much as possible will give the patient a better chance of survival and independence from the PN. This is the hope for our patient who suffered from being NPO for several years while waiting for intestinal transplantation (ITx).

Data from the intestinal transplant registry (ITR) published in 2003 revealed an almost 52.5% survival rate of the 923 patients after isolated intestine and combined liver and intestine transplantation, with graft rejection rates of 57% for isolated intestinal grafts, 30% for combined intestine and liver grafts, and 48% for multivesicular graft [18]. Current recommendations for ITx include early referral of patients with intestinal failure to experienced ITx centers, intestinal failure-associated liver disease evolving to liver failure, invasive intra-abdominal desmoids, acute diffuse intestinal infarction with hepatic failure, re-transplant, and children with loss of at least three of the four upper central venous access sites or with high morbidity from intestinal failure [19]. Listing of ITx for other candidates without an increased risk of death who are managing on PN without liver impairment is still a controversial matter. Other factors of importance should be considered depending on weighing risks versus benefits of ITx, quality of life, and expected future development in the sciences of SBS treatments and ITx.

Our patient had significant SBS. At the beginning of her illness, she was very sick with fear of high morbidity and mortality from liver failure, PN dependence, and poor quality of life sequences. Therefore, she was referred earlier to a higher center for ITx, where she was screened and listed for ITx once matched with a donor. However, after a long waiting period to find a matching donor and the development of high antibodies, she was precluded from the list. At that time, she was still managing well on PN without liver compromise. At that point, we decided to revisit her condition and resume the bowel continuity with a reconstruction of the gastrointestinal tract as described above. The patient has improved and the requirement for PN was reduced to alternate days. We hope that she will be off PN in the near future once bowel adaptation and absorption increase upon using Teduglutide [18]. Furthermore, developments in the science of ITx and immunosuppression therapy are still a future hope for such patients with severe SBS.

In conclusion, making use of the stomach and whatever remaining length of small intestine for digestion and absorption in SBS cases will facilitate good recovery, improve their quality of life, and perhaps prepare them well for either medical therapy and/or ITx.

Authors' Contribution: Taghreed Albalawi: literature review, manuscript writing, and editing. Mohammed Alnaami: literature review, manuscript writing and final editing. Khayal Alkhayal: Assistant and advisor. Hussam Alamri: Assistant and advisor. Rafif Matter: Assistant and advisor.

Acknowledgment Statements: We would like to thank Dr. Najd Alzahrani for drawing the pictures of Figures 1&2.

Ethical statement: Written informed consent was obtained from the patient to publish her case.

Declaration of interest: None.

Funding Sources: No funding.

Data availability statement: All data related to the article are available upon request.

References

1. Tice JA, Karliner L, Walsh J, Petersen AJ, Feldman MD (2008) Gastric banding or bypass? A systematic review comparing the two most popular bariatric procedures. *Am J Med*.10: 885-93.
2. Buchwald H, Avidor Y, Braunwald E, Jensen MD, Pories W, et al. (2004) Bariatric surgery: a systematic review and meta-analysis. *JAMA*; 292: 1724-37.
3. Fobi MA, Lee H, Holness R, Cabinda D (1998) Gastric bypass operation for obesity. *World J Surg*; 22: 925-35.
4. Podnos YD, Jimenez JC, Wilson SE, Stevens CM, Nguyen NT (2003) Complications After Laparoscopic Gastric Bypass: A Review of 3464 Cases. *Arch Surg*; 138: 957-961.
5. Higa KD, Ho T, Boone KB (2003) Internal hernias after laparoscopic Roux-en-Y gastric bypass: incidence, treatment and prevention. *Obes Surg*; 13: 350-4.
6. Champion JK, Williams M (2003) Small bowel obstruction and internal hernias after laparoscopic Roux-en-Y gastric bypass. *Obes Surg*; 13: 596-600.
7. McBride CL, Petersen A, Sudan D, Thompson J (2006) Short bowel syndrome following bariatric surgical procedures. *Am J Surg*; 192: 828-32.
8. Han Y, Jia Y, Wang H, Cao L, Zhao Y (2020) Comparative analysis of weight loss and resolution of comorbidities between laparoscopic sleeve gastrectomy and Roux-en-Y gastric bypass: A systematic review and meta-analysis based on 18 studies. *Int J Surg*; 76: 101-110.
9. Cho M, Pinto D, Carrodeguas L, Lascano C, Soto F, et al. (2006) Frequency and management of internal hernias after laparoscopic antecolic antegastric Roux-en-Y gastric bypass without division of the small bowel mesentery or closure of mesenteric defects: review of 1400 consecutive cases. *Surg Obes Relat Dis*; 2: 87-91.
10. Rodríguez A, Mosti M, Sierra M, Pérez-Johnson R, Flores Set al. (2010) Small bowel obstruction after antecolic and antegastric laparoscopic Roux-en-Y gastric bypass: could the incidence be reduced? *Obes Surg*; 20: 1380-4.
11. Klop C, Deden LN, Aarts EO, Janssen IMC, Pijl MEJ, et al. (2018) Diagnosing Internal Herniation After Roux-en-Y Gastric Bypass Surgery: Literature Overview, Cadaver Study and the Added Value of 3D CT Angiography. *Obes Surg*; 28: 1822-1830.

12. Däster S, Droeser RA, Delko T, et al. (2013) Two similar cases of internal hernia after laparoscopic Roux-en-Y gastric bypass surgery. *BMJ Case Reports*; 2013.
13. Hajibandeh S, Hajibandeh S, Abdelkarim M, et al. (2020). Closure versus non-closure of mesenteric defects in laparoscopic Roux-en-Y gastric bypass: a systematic review and meta-analysis. *Surgical Endoscopy*. 34.
14. Kristensen SD, Gormsen J, Naver L, Helgstrand F, Floyd AK (2021) Randomized clinical trial on closure versus non-closure of mesenteric defects during laparoscopic gastric bypass surgery, *British Journal of Surgery*, 108.
15. Iannelli A, Facchiano E, Gugenheim J (2006) Internal hernia after laparoscopic Roux-en-Y gastric bypass for morbid obesity. *Obes Surg*; 16: 1265-71.
16. Jeppesen PB, Gilroy R, Pertkiewicz M, et al. (2011) Randomised placebo-controlled trial of teduglutide in reducing parenteral nutrition and/or intravenous fluid requirements in patients with short bowel syndrome *Gut*; 60: 902-914.
17. Kim ES, Keam SJ. Teduglutide: A Review in Short Bowel Syndrome. *Drugs*; 77: 345-352.
18. Grant D, Abu-Elmagd K, Reyes J, Tzakis A, Langnas A, et al. (2005) 2003 report of the intestine transplant registry: A new era has dawned. *Ann Surg*. 241: 607-13.
19. Kaufman SS, Avitzur Y, Beath SV, Ceulemans LJ, Gondolesi GE, et al. (2019) New Insights Into the Indications for Intestinal Transplantation: Consensus in the Year 2019. *Transplantation*; 104: 937-946.