



Case Report

# Improvement of Scotopic Electroretinogram (ERG) in the Setting of CNGA3 Homozygous Recessive Gene Variant

Melissa A Trudrung<sup>1</sup>, Elizabeth R Kellom<sup>1,2</sup>, James N Verhoeve<sup>1,3</sup>, Bikash R Pattnaik<sup>1,3,4\*</sup>, Melanie Schmitt<sup>1\*</sup>

<sup>1</sup>Department of Ophthalmology and Visual Sciences, University of Wisconsin-Madison School of Medicine and Public Health, Madison, Wisconsin, USA

<sup>2</sup>Genetics, University of Wisconsin Madison - Waisman Center, Madison, Wisconsin, USA

<sup>3</sup>McPherson Eye Research Institute, University of Wisconsin, Madison, Wisconsin, USA

<sup>4</sup>Department of Pediatrics, University of Wisconsin-Madison School of Medicine and Public Health, Madison, Wisconsin, USA

\*Corresponding author: Melanie Schmitt and Bikash Pattnaik, Department of Ophthalmology and Visual Sciences, University of Wisconsin-Madison School of Medicine and Public Health, Madison, Wisconsin, USA

**Citation:** Trudrung MA, Kellom ER, Verhoeve JN, Pattnaik BR, Schmitt M (2024) Improvement of Scotopic Electroretinogram (ERG) in the Setting of CNGA3 Homozygous Recessive Gene Variant. Ann Case Report. 9: 1845. DOI:10.29011/2574-7754.101845

**Received:** 07 June 2024, **Accepted:** 11 June 2024, **Published:** 13 June 2024

## Abstract

**Introduction:** CNGA3 is one of the most common genetic causes of autosomal recessive achromatopsia. This report describes the case of a 6-month-old patient of Mennonite background with a CNGA3 homozygous recessive gene variant presenting with an extinguished full-field electroretinogram (ffERG) consistent with an initial clinical diagnosis of Leber congenital amaurosis (LCA). However, scotopic response on repeat ffERG showed improvement with age and features consistent with the expected genetic phenotype of achromatopsia. This case highlights the need for serial ffERG for appropriate clinical prognosis and diagnosis, mainly when genetic results are inconsistent with clinical presentation.

**Case Presentation:** A 6-month-old male patient from a Mennonite community presenting with nystagmus, intermittent eye-tracking difficulty, and poor eye contact was evaluated for vision concerns. Cycloplegic refraction yielded visual acuity of +5.00D OD and +4.50D OS. Fundoscopy showed macular pigment changes, and ffERG was initially extinguished. Two subsequent ffERG at 3- and 4-year follow-ups showed non-recordable photopic ERG but scotopic ERG within expected limits. Genetic testing was significant for a pathogenic variant CNGA3 c.1126G>A, p.(Glu376Lys) in a homozygous state. Family history was significant for high myopia in his mother and achromatopsia in his maternal first cousin once removed. Management included corrective lenses and eye protection from sunlight.

**Conclusion:** This case report describes the clinical presentation and ffERG of a Mennonite patient with a CNGA3 variant initially diagnosed with LCA, demonstrating improved scotopic ERG most consistent with achromatopsia, thus adding to our knowledge of the developmental changes in ERG in this inherited retinal disorder.

**Keywords:** CNGA3; Leber congenital amaurosis; Achromatopsia; Electroretinogram;

## Introduction

Achromatopsia refers to reduced visual acuity, photophobia, hyperopia, nystagmus, and impaired color vision resulting from dysfunction of cone photoreceptors inherited in an autosomal manner [1]. Typically, all three cone types are involved (complete type), but rarely, dysfunction is restricted to one or more types (incomplete type). Light-adapted (LA) full-field electroretinograms (ffERGs) that isolate cone-mediated function are non-recordable, while dark-adapted (DA) rod responses are normal or slightly abnormal [1,2]. Anatomically, retinal appearance is mostly normal, although mild foveal variants, absent foveal reflex, or a normal macula on funduscopy have been reported [1,2]. Complete achromatopsia has an estimated prevalence of about 1 in 30,000 people [3]. Variants in ATF6, CNGA3, CNGB3, GNAT2, PDE6C, or PDE6H have been associated with diagnosis [1,4]. Current treatment strategies include dark or tinted lenses to alleviate photo-aversion [1,5]. Establishing variant-specific strategies to identify retinal dystrophies through medical history, physical examination, laboratory and genetic testing, and family history can aid in prognosis, genetic counseling, and disease management.

Variants in the CNGA3 gene have exclusively been associated with achromatopsia [1,4], with only one clear report of Leber congenital amaurosis (LCA) in literature [6]. LCA is a severe retinal dystrophy diagnosed at birth or within the first year of life [7,8]. Clinical features of LCA include severe vision impairment or blindness, nystagmus, poor pupillary light responses, roving eye movements, oculodigital sign (eye poking, rubbing, or applying pressure), and an extinguished or irregular ffERG under both DA and LA conditions [7,8]. Funduscopy may reveal pigmentary retinopathy, pallor of the optic disc, and vascular attenuation [7,8]. Disease prevalence in the literature is between 1 in 30,000 to 1 in 81,000 people [7,9]. LCA is predominantly autosomal recessive and genetically heterogeneous, and variants in over twenty genes are known to be associated with disease [8], though up to 30% of cases will go undiagnosed molecularly [10].

Herein, we describe the medical history, clinical manifestations, and clinical course of a 6-month-old male patient with a homozygous pathogenic variant in the CNGA3 gene with an initial ffERG presentation indistinguishable from LCA. Subsequent improvement in the rod-mediated DA ffERG led to the patient's diagnosis of achromatopsia. We present this case to document early developmental changes that can present as LCA in young patients with achromatopsia.

## Case Presentation

A male infant of Mennonite background was initially evaluated at age 6 months after his parents noted nystagmus, lack of eye contact,

and his eyes intermittently not tracking together. His parents also had concerns about his distance vision. His evaluation was completed at a genetic eye disease clinic in Lafarge, Wisconsin, by an ophthalmologist specializing in inherited retinal degeneration (MAS). Visual acuity was central, unsteady, and maintained bilaterally. Cycloplegic refraction yielded acuity of +5.00D OD and +4.50D OS. The patient also shook his head with a fixed target, especially with a near target. On exam, pigmentary changes in the macula and a blunted foveal reflex were seen bilaterally. The ISCEV standard DA ffERGs were nondetectable using the RetEval™ ERG system and small-size sensor strips skin electrodes (LKC Technologies, Inc, Gaithersburg, MD). The rod ERG was recorded following a 20-minute dark adaptation to capture responses from each eye. Scotopic ERG showed a nondetectable response for both eyes at low flash intensity (DA 0.05). At higher flash intensities, severely reduced ERG responses were observed for both eyes (Figure 1. Upper panel) compared to normal scotopic and photopic ERG waveforms obtained for a 6-month-old healthy patient in our recording conditions (Figure 1. Lower panel). The patient was prescribed glasses to correct refractive errors at the end of the initial evaluation.

The patient's family history was significant for high myopia in his mother and hearing loss at age 25 in his father, who worked in construction. The patient also has a maternal first cousin, once removed, with achromatopsia and a paternal great-uncle and great-grandmother with possible retinitis pigmentosa. Follow-up genetic testing revealed a homozygous variant of CNGA3 c.1126G>A, p.(Glu376Lys). At the time, there is one individual heterozygous for this variant in the Genome Aggregation Database (gnomAD, n>120,000 exomes and >15,000 genomes) [11]. No homozygotes were observed in the dataset. The affected amino acid is well conserved in mammals, which suggests that this position may not tolerate variation. In silico modeling predicted toleration of the amino acid change.

Koeppe et al. reported a patient with achromatopsia homozygous for the same p.(Glu376Lys) variant [12]. Cell culture studies showed macroscopic currents for cyclic nucleotide-gated channels carrying variant p.(Glu376Lys) were absent when the variant was expressed alone and significantly reduced when the variant was co-expressed with the wild-type, similar to other tested missense alterations, suggesting that this variant affects the channel function. We realized this is a known variant within the Mennonite community associated with achromatopsia with a mean allele frequency in that population of 2.84% (Dr. Erik Puffenberger, personal correspondence). A total of 266 nuclear genes were evaluated, and additional findings included heterozygous variants of uncertain significance in autosomal recessive genes, CNGB3 c.1513A>G, p.(Thr505Ala) and IFT172 c.3674G>A, p.(Arg1225Gln) and deemed unlikely to be relevant to the case.

Four months after the initial evaluation, his parents reported his vision had improved when wearing lenses and noted less nystagmus. On exam, horizontal nystagmus alternated with lateral head bobbing, and there was a new rotary component of the nystagmus. Ten months after our initial evaluation, his parents reported increased light sensitivity with improved vision on cloudy days. On exam, horizontal nystagmus was noted without previously noted rotary component or head bobbing. A blunted foveal reflex with increased macular pigmentation was noted bilaterally on the exam. Two years after the presentation, the pen light exam noted no head bobbing or nystagmus. The blunted foveal reflex present bilaterally was unchanged. The patient consistently wore sunglasses outside three years after the presentation, and his vision appeared stable, per his mother. Fundus examination revealed unchanged blunted foveal reflexes bilaterally (Figure 2). No nystagmus or head bobbing was noted. Follow-up fERG performed at three years of age showed significant changes from previous tests. The previously undetectable DA ERG improved and were outside the expected 2.5th and 97.5th percentile limits for the b-wave in DA 0.01, and both a- and b-wave in DA 3.0 and DA 10.0 flash strengths established for the RETeval device with no response to LA 3.0 and LA 28 Hz conditions (Figure 1, 2nd row compared to control shown in Figure 1, lower panel). Management of the patient's retinal dystrophy consisted of a corrective lens and avoidance of sunlight.

Four years after the initial presentation, his mother reported no further changes in vision and that he consistently wore his glasses. Unsteady fixation and blunted foveal reflex remained unchanged bilaterally. The rod-mediated DA fERG showed improvement compared with the fERG at three years of age, with scotopic response outside the normal adult limits. Still, photopic ERGs remained undetectable (Figure 1, 3rd row compared to control shown in Figure 1, lower panel).

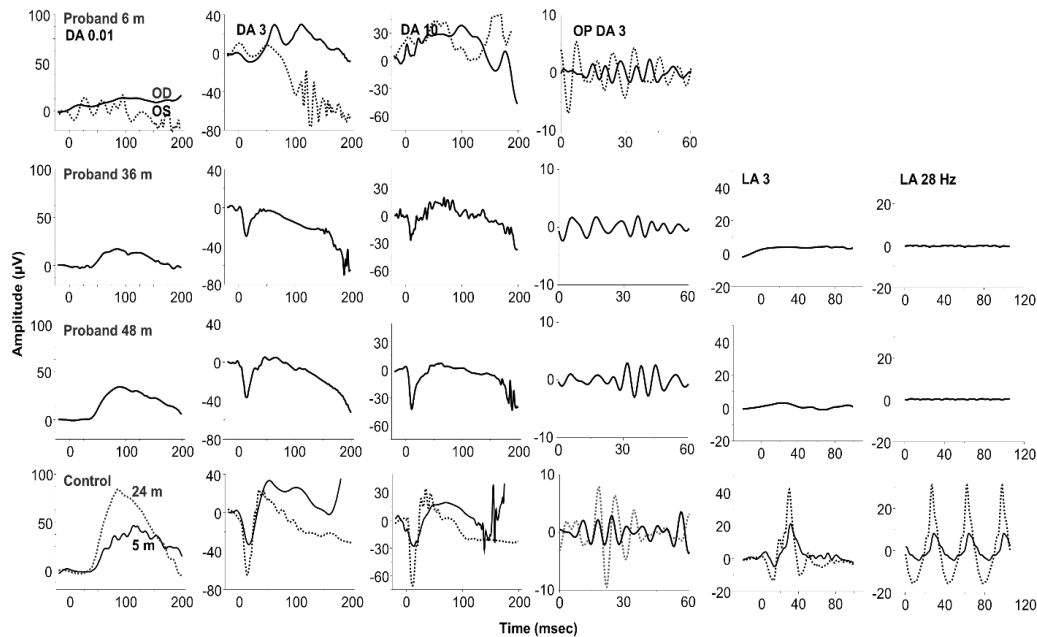
## Discussion

Mutations in genes associated with retinal dystrophies can have different and overlapping phenotypes [13]. Therefore, it is important to understand the structural and functional variations associated with specific mutations. An infant with nystagmus, reduced vision, and a flat ERG is typically diagnosed with LCA [14,15], although there may be considerable overlap with congenital stationary night blindness (CSNB) and achromatopsia. With the advent of gene and other therapies for these disorders, it will be critical to understand variations in the developmental history of these disorders in very young patients, who may be the best candidates for intervention. Recently, a Phase I retinal gene therapy trial for CNGA3-mutated achromatopsia showed functional improvement and no adverse

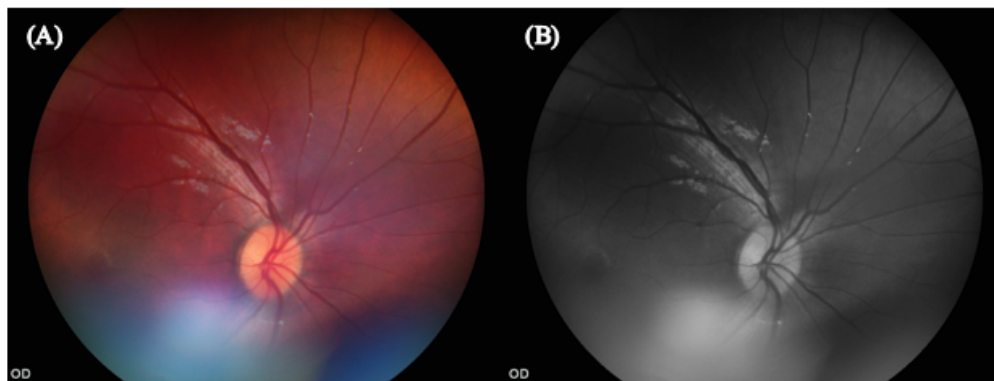
effects three years after participants received subretinal AAV8. CNGA3 gene therapy [16].

Achromatopsia is an autosomal recessive retinal dystrophy, and variants of it have been found in six genes [1,4]. CNGA3 is a gene associated almost exclusively with achromatopsia [1,4]. Solaki et al. compiled an overview of the CNGA3 variant spectrum [17]. They gathered data from 889 independent families with achromatopsia. In this, they commented on the clinical and diagnostic aspects of achromatopsia. Usually, the diagnosis is given in the first months or years of age via confirmation with molecular genetic testing, as children may have poor cooperation on clinical exams. The fERG is a tool for diagnosing scotopic recordings within normal limits, while photopic responses are unmeasurable. Imaging of the retina usually shows a normal fundus. Differential diagnoses can include early onset cone dystrophy, blue cone monochromacy, bradyopsia, or other diseases that may present with nystagmus or photophobia. The course of achromatopsia has historically been considered stationary, but retinal imaging has revealed progressive changes in cone cells [17].

A previous report found the CNGA3 variant in a 10-month-old with congenital nystagmus, sluggish pupils, and a flat scotopic and photopic ERG consistent with LCA6. No serial fERGs were reported, but there was no visual response at 2 years of age. The variant reported in that case was a homozygous unique missense variant in a consanguineous family. ACMG variant classification guidelines suggest a likely pathogenic classification for the reported variant due to other pathogenic variants affecting the same codon, the rarity of the variant in the general population, and agreement across in silico modeling tools that this variation would lead to disrupted protein function. This case of a 6-month-old male from a Mennonite background with a CNGA3 variant is consistent with the existing literature on a relationship between this CNGA3 variant and achromatopsia [1,4]. Additionally, approximately six Mennonite individuals have been documented to have achromatopsia due to the homozygosity of this variant (Dr. Erik Puffenberger, personal correspondence). Although reduced in amplitude relative to adults, rod-mediated ERGs are usually evident in the first weeks of life [18]. The marked developmental delay in the appearance of rod-mediated ERGs in this cone dystrophy may be a feature of this CNGA3 variant and some CACNA1F variants of CSNB [15]. Thus far, the patient has been managed with corrective lenses and sunlight avoidance. Four years post-diagnosis, fERG revealed flat photopic and scotopic responses within normal limits. This late improvement in DA ERG response has not been previously reported. The fact this report is based on a single subject over a relatively short period of observation represents significant limitations to the case study.



**Figure 1:** ERG waveforms were recorded under scotopic and photopic conditions. Six ISCEV standard recording traces during three developmental time points (6, 36, and 48 months) using a skin electrode for the patient (upper three rows) compared to the control (lower row). At six months, developmental time point recordings from both left and right eyes are measured for scotopic conditions only. For the normal subject, ERG traces at 5 months and 24 months are presented to indicate the normal range and typical waveform in our recording protocol.



**Figure 2:** (A) Fundus photograph at 3 years old. (B) Autofluorescence photograph at 3 years old.

## Conclusion

In summary, we describe an autosomal recessive CNGA3 variant in a male Mennonite child initially presenting at 6 months of age with nystagmus, poor visual responses, and non-recordable LA and DA ERGs, typically associated with LCA. Photopic ERGs remained non-recordable, but scotopic ERG response markedly improved across a four-year follow-up period. At three years of age, the ERG pattern was typical achromatopsia. This report highlights the importance of serial fERG testing in very young infants to understand the natural history of rod and cone functional development in inherited retinal disorders.

**Acknowledgments:** Erik Puffenberger, PhD, for his insights on the variant in the Mennonite community.

**Ethical Guidelines:** Informed consent was obtained from the patient's legal guardian for publication of the medical case and any accompanying images.

**Conflict of Interest:** The authors report no conflicts of interest.

**Funding:** This work was partly supported by an Unrestricted Grant from Research to Prevent Blindness, Inc. to the UW-Madison Department of Ophthalmology and Visual Sciences, the John W. Doolittle Professorship, and the Retina Research Foundation M.D. Matthews Research Professorship.

## References

1. Kohl S, Jägle H, Wissinger B, Zobor D, Adam MP, et al. (2004) Achromatopsia. 2004 Jun 24 [Updated 2018 Sep 20]. In: Adam MP, Feldman J, Mirzaa GM, et al., editors. *GeneReviews®* [Internet]. Seattle (WA): University of Washington, Seattle; 1993-2024.
2. Yang P, Michaels K V, Courtney RJ, Wen Y, Greninger DA, et al. (2014) Retinal morphology of patients with achromatopsia during early childhood: implications for gene therapy. *JAMA Ophthalmol*. 132:823-831.
3. Aboshiha J, Dubis AM, Carroll J, Hardcastle AJ, Michaelides M. (2016) The cone dysfunction syndromes. *Br J Ophthalmol*. 100:115-121.
4. Kohl S, Marx T, Giddings I, Jagle H, Jacobson SG, et al. (1998) Total colourblindness is caused by mutations in the gene encoding the alpha-subunit of the cone photoreceptor cGMP-gated cation channel. *Nat Genet*. 19:257-259.
5. Schornack MM, Brown WL, Siemsen DW. (2007) The use of tinted contact lenses in the management of achromatopsia. *Optometry*. 78:17-22.
6. Wang X, Wang H, Cao M, Li Z, Chen X, et al. (2011) Whole-exome sequencing identifies ALMS1, IQCB1, CNGA3, and MYO7A mutations in patients with leber congenital amaurosis. *Hum Mutat*. 32:1450-1459.
7. Koenekoop RK. (2004) An overview of Leber congenital amaurosis: a model to understand human retinal development. *Surv Ophthalmol*. 49:379-398.
8. Kumaran N, Pennesi ME, Yang P, Trzuek KM, Schlechter C, et al. (2018) Leber Congenital Amaurosis / Early-Onset Severe Retinal Dystrophy Overview. 2018 Oct 4 [Updated 2023 Mar 23]. In: Adam MP, Feldman J, Mirzaa GM, et al., editors. *GeneReviews®* [Internet]. Seattle (WA): University of Washington, Seattle; 1993-2024.
9. Stone EM. (2007) Leber Congenital Amaurosis—A Model for Efficient Genetic Testing of Heterogeneous Disorders: LXIV Edward Jackson Memorial Lecture. *Am J Ophthalmol*. 144:791-811.e6.
10. den Hollander AI, Roepman R, Koenekoop RK, Cremers FPM. (2008) Leber congenital amaurosis: genes, proteins and disease mechanisms. *Prog Retin Eye Res*. 27:391-419.
11. Genome Aggregation Database (gnomAD) was accessed on 28 February 2024.
12. Koeppen K, Reuter P, Ladewig T, Kohl S, Baumann B, et al. (2010) Dissecting the pathogenic mechanisms of mutations in the pore region of the human cone photoreceptor cyclic nucleotide-gated channel. *Hum Mutat*. 31:830-839.
13. Bravo-Gil N, Méndez-Vidal C, Romero-Pérez L, Pozo M, Rua ER, et al. (2016) Improving the management of Inherited Retinal Dystrophies by targeted sequencing of a population-specific gene panel. *Sci Rep*. 6:23910.
14. Lambert SR, Kriss A, Taylor D, Coffey R, Pembrey M. (1989) Follow-up and diagnostic reappraisal of 75 patients with Leber's congenital amaurosis. *Am J Ophthalmol*. 107:624-631.
15. Men CJ, Bujakowska KM, Comander J, Place E, Bedoukian EC, et al. (2017) The importance of genetic testing as demonstrated by two cases of CACNA1F-associated retinal generation misdiagnosed as LCA. *Mol Vis*. 23:695-706.
16. Reichel FF, Michalakis S, Wilhelm B, Zobor D, Muehlfriedel R, et al. (2022) Three-year results of phase I retinal gene therapy trial for CNGA3-mutated achromatopsia: results of a non randomised controlled trial. *Br J Ophthalmol*. 106:1567-1572.
17. Solaki M, Baumann B, Reuter P, Andreason S, Audo I, et al. (2022) Comprehensive variant spectrum of the CNGA3 gene in patients affected by achromatopsia. *Hum Mutat*. 43:832-858.
18. Hansen RM, Fulton AB. (2005) Development of the cone ERG in infants. *Invest Ophthalmol Vis Sci*. 46:3458-3462.