



Case Report

Identification of the Cause of Death of a Corpse in Water through Immersion Time Combined with Tide Mark on Neck and Material Mechanic Measurement for Suspicious Rope of Strangulation

YingLin Zhu¹, ZeYu Chen¹, Xiao Jun Yu^{1*}, Bo Li², YanHui Mao³

¹Department of Forensic Medicine, Shantou University Medical College, Shantou, Guangdong Province, China

²Qiushi Judicial Appraisal Center, Nanchang, Jiangxi Province, China

³Weishi Judicial Appraisal Center, Zhengzhou, Henan Province, China

***Corresponding author:** Xiao Jun Yu, Department of Forensic Medicine, Shantou University Medical College Shantou, Guangdong Province, China

Citation: Zhu YL, Chen ZY, Yu XJ, Li B, Mao YH (2022) Identification of the Cause of Death of a Corpse in Water through Immersion Time Combined with Tide Mark on Neck and Material Mechanic Measurement for Suspicious Rope of Strangulation. Ann Case Report. 7: 1037. DOI: 10.29011/2574-7754.101037

Received Date: 10 November 2022; **Accepted Date:** 14 November 2022; **Published Date:** 16 November 2022

Abstract

In some cases, the cause of cadavers in water are not drowning. Medical examiners need to identify whether he died caused by drowning or was dumped into water after death caused by other factors. This paper analyzes a related case where the cause of death was reported by medical examiner who performed the anatomy “*unidentified*” since he thought the victim’s body had become highly decomposed and other experts believed that the victim unconsciously fell into the sea due to the drug he had taken into the sea and this was an accident. Family members did not satisfy with the above opinions and entrusted us to give our advice. After comparing the putrefaction signs on cadaver from scene and anatomy photos, we deemed that the time of death, time of body immersion and the time reported missing were not consistent, combined with the wound on neck and the material mechanical analysis results of broken earphone found in scene, we confirmed this was a murder, the victim suffered strangulation by others with earphone and then was thrown into the sea.

In this case none of persons i.e. victims and experts involved providing their advice are going to be named.

Keywords: Corpse in water; Tide mark; Strangulation; Material mechanic measurement; Forensic pathology

Introduction

Strangulation means the death caused by wrapping a rope object around the neck and pressing it on the neck with external force. When in strangulation, the face will be obviously bruised and swollen due to the jugular venous reflux disorder and the incomplete occlusion of the carotid arteries and the vertebral arteries [1]. Therefore, the distinct sign that above the ligature mark congestion could be seen while below the ligature mark relative anemia could be seen is called “*tide mark*” [2]. Any material will become deformed after the force. To a certain extent, the deformation will lead to the fracture. The deformation and fracture under the external force which are determined by the inside material structure are the inherent properties of the material [3]. Stretch test is one of the most commonly used test methods for measuring mechanical nature. In forensic daily practice, measuring the mechanical properties of the suspicious instrument-causing trauma helps to infer the true cause of death.

Summary of the Case

At 19:00 on July 28, 2012, a 16-year-old male was taking drugs with his friends, in the meantime another friend called him to a warehouse by the sea to pay him back the money. On the way to warehouse, he still contacted with his family. 22:30, he lost contact. At 0:45 on July 29, his mother reported missing. At about 20:30 on July 30, his body was found floating in sea near the warehouse about 46h after going missing.

Forensic autopsy

On August 1st local forensic autopsy: the body showed moderate decomposition changes with generalized greenish discoloration and putrefactive networks and blisters formation and slippage of skin, bloating of facial features, protruding eyeballs and tongue, mild abdominal distension, scrotal swelling. Signs of prolonged immersion with wrinkling and whitening of hands and legs. A laceration above the neck was about 6cm long, only the superficial muscle layer was damaged and no injuries in deep neck muscle or neck structures. There was no evidence to suggest that whether the wound was antemortem or postmortem in nature. Partial loss of soft tissues around eyes, ears and wound on neck and the inner side of right knee probably due to postmortem marine animal activities. No identifiable abnormality or injury in scalp, skull, dura mater, brain and heart. Left and right chest cavities respectively contained about 50ml and 550ml of dark reddish decomposition fluid. Trachea contained some frothy secretion.

Lungs appeared somewhat hyperinflated and waterlogged, with abundant fluid flowing out from cut surface. Brain, liver, spleen and kidneys were decomposing. Stomach and Urinary bladder were empty. The cause of death was given as “*uncertainty due to decomposition*”. The inferred time of death was 22:20 on July 28, which was consistent with the time of disappearance.

Toxicological Examination

On August 3 quantitative results of toxicological analyses from blood: ketamine and fluoxetine were respectively 3.0µg/mL and 1.4µg/mL; both acetaminophen and pethidine were at therapeutic concentrations.

Opinions of the Different Experts

Local toxicologists believed that “the cause of death was taking a lot of ketamine and he was unconscious and drowned in the sea.” Local associate professor of pathology said that “could not determine the time when the deceased fell into the water and the wound on front neck may be caused by a sharp weapon”. A foreign professor of forensic pathology claimed, “there was no evidence that the deceased had suffered head trauma; the anterior neck injury was caused by marine life biting after death; and the effect of ketamine caused the deceased to fall into the sea”.

Re-Analysis

In 2014, we were entrusted to give relevant forensic medical opinions on this case. We analyzed the case, photos of the scene and autopsy, toxicological results, expert opinions, etc.

Photos of the scene where the corpse was found showed: There was a broken headphone wire in the deceased’s pocket and the coins inside it were not lost. The face, neck and upper limbs of the decedent were congested, and the color of face was especially dark (Figure 1A). The left forehead, left eyelid and lip were largely covered with dark purplish-red ecchymoses caused by contusion.

On the middle upper part of the front neck there was a transverse laceration; the two sides of the wound extended transversely, forming an annular ligature mark; congestion was serious at the upper part of the wound, gradually being shallow from forward to backward; subcutaneous tissue around the wound and in the wound were covered with blood. In short, above the ligature mark congestion was discovered, and below it anemia was seen (Figure 1B). There was a dark red bruise on the back of the right hand; the chest, upper abdomen were peeled over a large area; hands and feet palm skin were gray white and wrinkled like “*Washerwoman skin*” (Figure 1C). Livor mortis on the back were not obvious (Figure 1D). No any significant abnormality was seen in the rest.

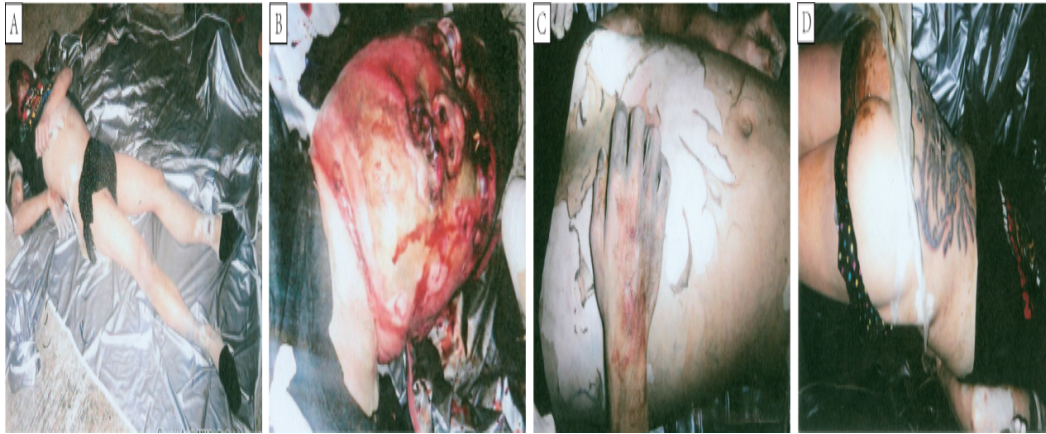


Figure 1: Photos of the scene where the corpse was found.

Compared it to the photos taken on July 30, autopsy photos taken on August 1st showed: the signs of putrefaction in the deceased was significantly aggravated; the face, neck, chest, upper abdominal, shoulders and arms were covered with obvious putrefactive networks (Figure 2A); the back were covered by pink lividity extensively (Figure 2B). The face was not congested anymore. Middle forehead, left eyelid, nasal arch, and right clavicle were covered by ecchymoses. There was a transverse bruised laceration in the middle of the front neck and the epidermis around it was desquamative and the edge of it was regular. Its cavity was shallow and curved along the superficial fascia; its angle was obtuse, the ligature mark outside the angle disappeared; its bottom stopped in the pretracheal fascia, covering with a large black-brown immersion pattern which liked bleeding diffusion, and transverse hemorrhagic ecchymoses caused by contusion were found in the periosteum below the larynx (Figure 2C, D, E). Bleeding caused by contusion could be seen at the top of the left temple and the petrous pyramid of the left middle cranial fossa were congested extensively (Figure 2F).

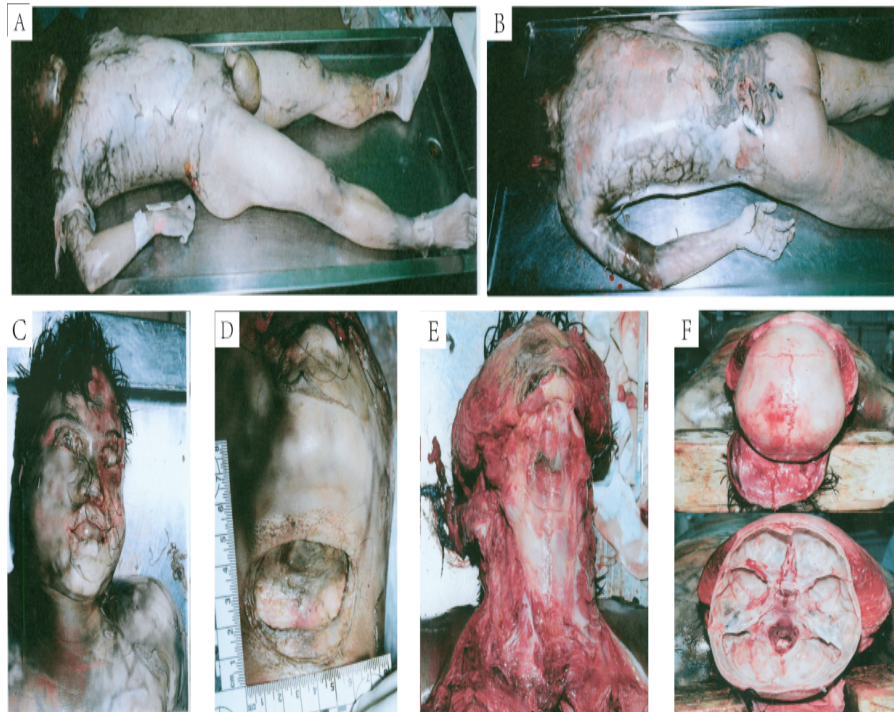


Figure 2: Pictures of the autopsy.

Material mechanical testing of the earphone wire: the deceased's family provided a newly purchased earphone as the same type as the one found in his pocket. We used Electronic material testing machine (Shenzhen Kaiqiangli Testing Instruments Co. Ltd.) to perform the stretching experiments on earphone wire. Plastic foam bound into cylindrical shape to simulate the general adult neck thickness, then hold the lower part of foam with the thick section of earphone wire, the maximum load force measured at 500 mm/s was 232.47N(about 23kg); the maximum load force measured at 300 mm/s with the thin section of earphone wire was 21.67N(about 2kg).

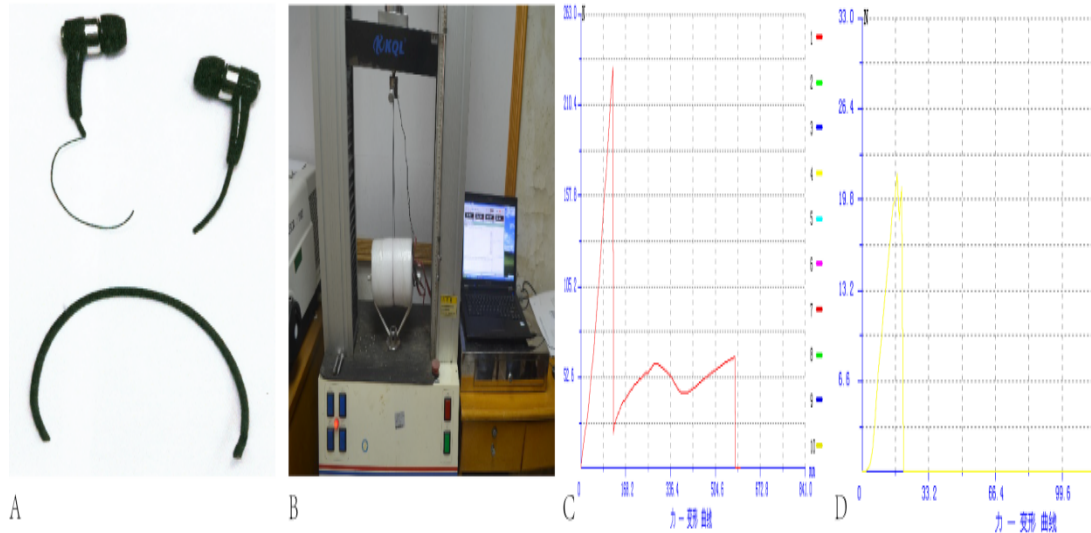


Figure 3: Mechanical analysis experiment of headphone. (A-the broken earphone wire in the deceased's pocket; B-process of material mechanical experiment; C-force deformation curve from thick segment of earphone; D-force deformation curve from thin segment of earphone).

Discussion

According to the local average water temperature in summer is generally around 24°C, the corpse gotten out of sea could only be seen that the chest was peeled over a large area and the skin of the palm of the hands and feet was white and wrinkled, indicating that the corpse was soaked in water within 24h [1,4]. There was no obvious lividity on the dorsum when the victim was found, when in dissection, the discovery of lividity on the back, which meant the shift of lividity indicated that the time of death was within 6-12 hours before being found. Above the ligature mark, congestion and swelling on face and neck was extensive and serious, and below it, lower neck was pale and anemic. This distinct difference was consistent with the typical tide mark [2] caused by antemortem pressure on jugular vein. The putrefaction networks and bloated cadaver seen in the photos from autopsy performed two days after the discovery of the corpse were in line with the accelerated corruption process after the submersion cadavers came ashore. Ecchymosis and bleeding of the left middle forehead, left eyelid, back of right hand on the surface body, combined with the blood shade on the left temporal-top scalp and the pyramis of the left temporal bone in the autopsy, suggested that when the deceased was alive he suffered the corresponding blunt object damage to

the head. General pressure required to clamp down the human jugular vein, carotid artery, vertebral artery, and tracheal is 2, 3.5, 16.6 and 15kg respectively [5]. Combined with the mechanical measurement results of the same type of earphone wire, it was confirmed that the thick and thin segments of the headphone wire in the deceased pocket were enough to close the jugular vein, prompting that ligature mark on neck was caused by his own earphone wire.

Ketamine [6], fluoxetine [7], piperidine [8] and paracetamol [9] detected in the blood of the deceased fitted the case that he had taken drugs with friends before his death. The blood concentrations of these drugs can act alone or jointly on the central nervous system, which could not be excluded to affect the brain's tolerance against ischemia and hypoxia.

Conclusion

We believe that in this case the decedent was hit by others and mechanical asphyxia through compression on jugular vein caused by strangulation before death, then the body was thrown into the sea. Combined with the time of missing, the immersion time did not exceed 24h, and the survival time after missing on land was about 22h. In 2017, the local authorities opened a death

court hearing on the case, and the jury finally ruled that “the cause of death was in doubt” and suggested that the police department continue its investigation. From the lessons of this case, relevant experts may be affected by drug case and toxicological results, with some degree of preconceived thinking and they did not comprehensively analyze all related evidence, especially tide mark and injuries on head and hand. Moreover, they ignored the association of ligature mark around the neck and its features and the broken earphone wire.

More attention should be paid to the three points of forensic daily work [10]: evidence search, evidence-based practice, demonstration. We should build a comprehensive and systematic causal evidence chain and identification opinions throughout the case.

References

1. Cong B (2016) *Forensic Pathology*, 5th edition.
2. James JP, Hu Zhao's (2017) *Forensic Medicine*, 1st edition.
3. Sharma PK (2010) *Mechanics of materials*. *Technol Health Care*; 18: 49-61.
4. Heaton V, Lagden A, Moffatt C, Simmons T (2010) Predicting the postmortem submersion interval for human remains recovered from U.K. waterways. *J Forensic Sci* 55: 302-307.
5. Bao-Jie Wang, Ying-Ping Hou's (2013) *Forensic Medicine*, 7th edition.
6. Jing Zou, Fan Chen, Xue-Yan Wang (2022) Effects of ketamine abuse on AMP, ADP and ATP content in multiple brain regions of rats. *Chinese Journal of Forensic Medicine* 37: 246-250.
7. Ting-Ting Guo, Jie Zhou, Jian Guo (2022) Fluoxetine pre-treatment exacerbates bleeding in a mouse model of intracerebral hemorrhage. *West China Medical Journal* 37: 431-436.
8. Guo-Hua Zhang, Bao-Jie Wang, Xu Wu, Yi-Geng Hu (2004) The changes of Bax in neurons of brain during chronic pethidine dependence and spontaneous withdrawal in rats. *Chinese Journal of Forensic Medicine* 1: 22-25.
9. Min Shen, Ping Xiang's (2012) *Forensic Toxicology Handbook*, 1st edition.
10. Lin-Chuan Liao's (2021) *Forensic Medicine*, 4th edition.