



Case Report

Desflurane in Patient with Pulmonary Arterio Venous Malformation for Fracture Humerus A Case Report

Karthik Sundareshan^{1*}, Hany Fawzi Greiss², Altaf Hussein Syedkazmi³, Navin Kumar Manickam⁴

¹Specialist registrar, Department of Anesthesia & Intensive Care, Rashid Hospital and Trauma centre, Dubai Health Authority, Dubai, UAE

²Consultant & Head of Anesthesia Section, Rashid Hospital and Trauma centre, Dubai Health Authority, Dubai, UAE

³Specialist Senior Registrar, Department of Anesthesia & Intensive Care, Rashid Hospital and Trauma centre, Dubai Health Authority, Dubai, UAE

⁴Specialist Senior Registrar, Department of Radiology Rashid Hospital and Trauma centre, Dubai Health Authority, Dubai, UAE

***Corresponding author:** Karthik Sundareshan, Specialist registrar, Department of Anesthesia & Intensive Care, Rashid Hospital and Trauma centre, Dubai Health Authority, Dubai, UAE

Citation: Sundareshan K, Greiss HF, Syedkazmi AH, Manickam NK (2022) Desflurane in Patient with Pulmonary Arterio Venous Malformation for Fracture Humerus A Case Report. Ann Case Report. 7: 1049. DOI: 10.29011/2574-7754.101049

Received Date: 01 November, 2022; **Accepted Date:** 09 November, 2022; **Published Date:** 14 November, 2022

Abstract

Pulmonary Arteriovenous Malformations (AVMs) are caused by abnormal vascular communication between the pulmonary arteries and veins. Our patient was diagnosed with pulmonary AVM six months prior to surgery as an incidental finding. The patient presented with a humerus fracture. General anesthesia was administered according to the surgical condition, need for sitting position and duration of surgery. Desflurane was used to maintain anesthesia in view of its pharmacological characteristics of early recovery. Even though regional anesthesia preferred in these patients, when properly managed, general anesthesia can be safe in these patients.

Keywords: Desflurane; Hypoxemia; Pulmonary AVM (Arteriovenous malformation)

Introduction

Pulmonary Arteriovenous Malformations (AVMs) are caused by abnormal vascular communication between the pulmonary arteries and pulmonary veins, which lead to blood bypassing the normal pulmonary capillary beds. AVMs result in right-to-left shunts which subsequently cause hypoxemia¹. Pulmonary AVMs vary in size from 1 to 5 cm [1,2]. Generally, pulmonary AVMs <2 cm in size do not produce clinical symptoms [1,2]. Many patients are diagnosed when they visit a hospital for other reasons. Treatment option vary from surgical resection to

transcatheter embolization which is the treatment of choice [3] for pulmonary AVMs. A challenging situation is when a untreated patient undergoes other surgical procedure [4].

Patient Information

A 47 years old male, an electrician by occupation, presented with a fall from a height of 1 meter, no head injury, and was scheduled for right midshaft humerus fixation. No previous surgery. The patient was diagnosed with pulmonary AVM six months prior as an incidental finding and was not receiving any treatment due to financial issues. Non-smoker, no history of epistaxis or bleeding tendency, no history of chest pain, palpitations, or breathing difficulties.

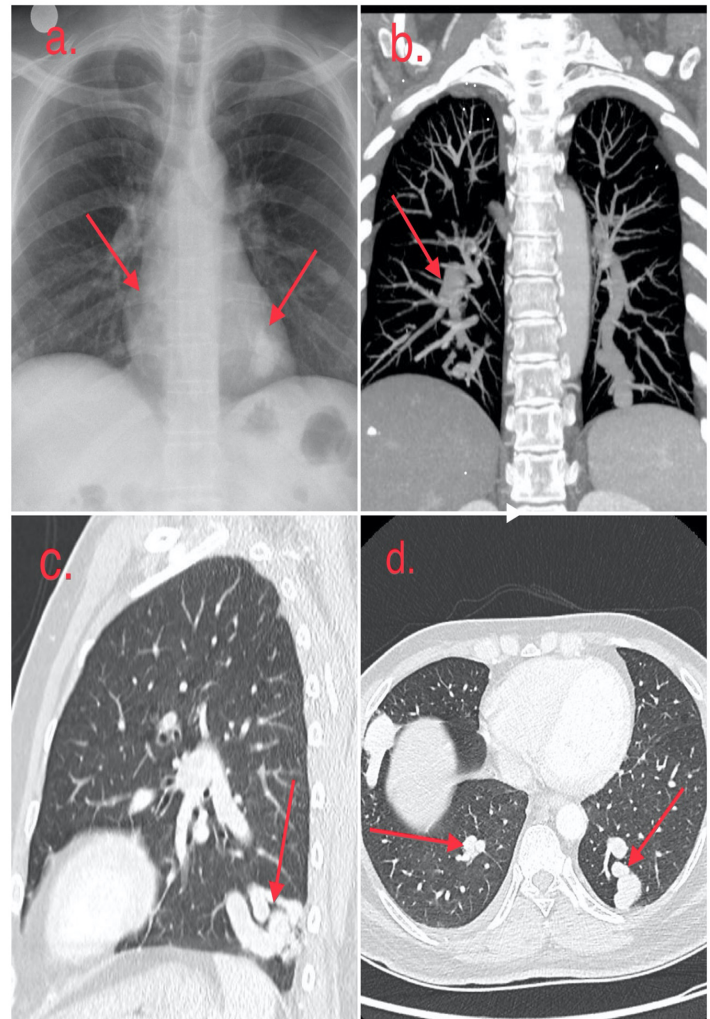
Clinical Findings and Diagnostic Assessment

On examination the patient is conscious, no respiratory distress, Saturation of 92% on venturi mask fio2 35%, ABG Ph 7.433, Pco2 30.5, Po2 57, Hco3 20, normal cardiovascular and CNS examination, Abdomen - no organomegaly. Laboratory values showed hemoglobin 19.9, hematocrit 58.5, computed tomography chest-AVMs seen in the right medial and lateral basal segments of the right lower lobe and posterior basal segment of the left lower lobe, as well as the superior lingula. Largest AVM is seen at the left lower lobe measuring about 2 x 2.5 cm and it is seen communicating by draining vein to the right inferior pulmonary vein and by feeding the artery to the segmental branch of the right lower lobar artery, measuring 6 mm. Patent pulmonary trunk and main branches. Electrocardiography and echo cardiography findings were normal with an ejection fraction of 65%. As per institutional policy patient was evaluated by multidisciplinary team. Seen by Pulmonologist, recommended saturation of 90 – 94% is acceptable in view of the shunt. Assessed by medical and hematology for polycythemia, advised for Venesection and ruled out other causes of polycythemia. Venesection was performed twice, and a day earlier for surgery, the hemoglobin level was 17. Cardiology assessment was also performed.

Therapeutic Intervention

Pre operatively, the patient was made aware of his condition, need for surgery, necessity of general anesthesia, as the surgical team decided to perform the procedure in the beach chair position. Premedication was not administered. The patient received supplemental oxygen via a nasal cannula maintaining oxygen saturation at 90 - 92%. After adequate pre-oxygenation, anesthesia was induced with fentanyl (2 mcg/kg), propofol (2 mg/kg) and cis-atracurium (0.1 mg/kg). Cefuroxime antibiotic were administered to the patient. A leur lock syringe was used to administer all medications, taking care not to inject air bubbles. An arterial line was inserted to monitor serial blood gas. The patient was maintained on desflurane in oxygen, targeting an oxygen saturation of 90 – 92%. Surgery took 3 h and blood loss was 500 ml. Adequate hydration was maintained intraoperatively. After the patient was placed in the supine from beach chair surgical

position, desflurane was turned off and extubation was performed after the criteria were met. For post operative pain control, the patient received patient-controlled analgesia (PCA) morphine as there was intraoperative manipulation of radial nerve, which was discontinued on 2 nd post-operative day. On 7 th post-operative day, the patient was discharged with instructions about the disease and regular follow-up with the pulmonology department (Figure 1).



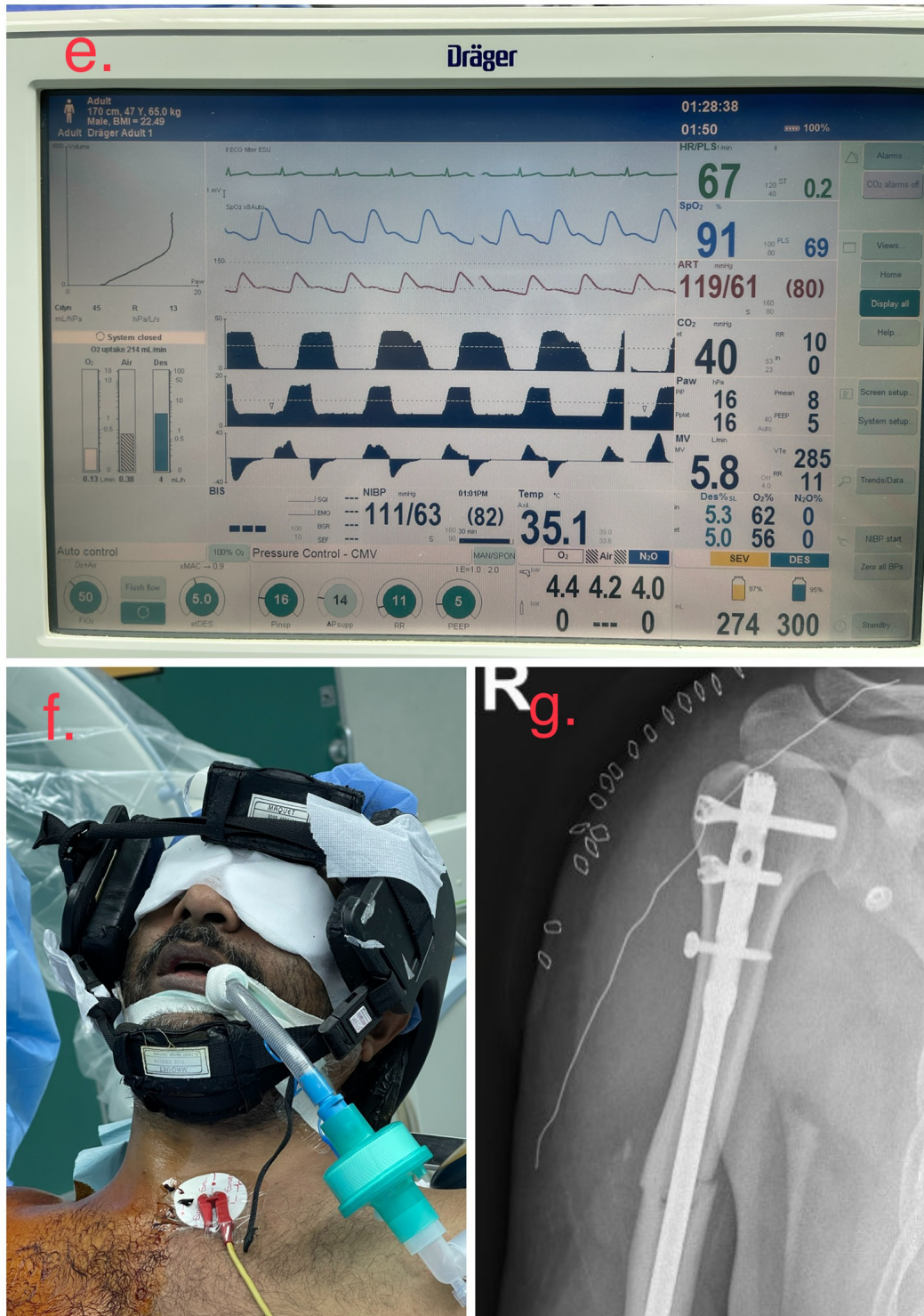


Figure 1: a) Chest X ray PA view showing pulmonary AVM. b-d) CT Chest red arrow indicating multiple pulmonary AVM. e) Intraoperative vitals, f) Patient position – beach chair with head support, g) Shoulder X Ray showing fracture with nail in situ.

Discussion

Management of patients with pulmonary AVM is challenging for the anesthesiologists. Preoperatively, patients need to be educated regarding the conditions and challenges associated with surgery. The risk of AVM rupture results in hemothorax and hemoptysis, which can be massive and life threatening [5]. A right to left shunt resulting in hypoxemia, overload of heart failure and embolism across the shunt can cause stroke and brain abscess [6,7]. Preoperatively, patients may need venesection, as in our patient, and adequate hydration, as polycythemia can be harmful in the perioperative period. Care should be taken to avoid injection of minute air bubbles during intravenous injection, as it might result in paradoxical embolism, use of Leur lock syringe, stoppers and intravenous tubing's with air trapping compartments. Antibiotic prophylaxis as coverage for the surgery and to avoid septic emboli.

When it comes to choosing anesthesia, regional anesthesia is preferred as spontaneous breathing is maintained, avoiding the need for positive pressure ventilation, which may exacerbate shunting in pulmonary AVM and worsening hypoxia. TIVA [8] (Total intravenous anesthesia) might be another option because it avoids the need for positive pressure ventilation and Hypoxic Pulmonary Vasoconstriction (HPV) [9] induced by an inhalational agent that worsens shunting. Our patient might have been operated under interscalene brachial plexus block, but considering the complexity of the fracture, the duration of surgery, and the need for beach chair position made us to go for general anesthesia with a secured airway. Care should be taken to avoid a pressor response during intubation, which is equally important during extubation, as hypertension can result in AVM rupture. Use of low tidal volume and fraction of inspired oxygen (FiO₂)/end-tidal carbon dioxide (EtCO₂) monitoring to achieve a saturation of 90-92%. Maintaining normotension during surgery is paramount as a general anesthesia induced decrease in systemic vascular resistance can aggravate right to left shunt. Our choice of inhalation agent was desflurane considering its faster recovery profile, even though there is insufficient evidence to support the use of other inhalation agents as there is no significant difference between the modern volatile anaesthetics isoflurane, sevoflurane, and desflurane in their inhibition of HPV at equi-MAC doses [10,11].

References

1. Khurshid I, Downie GH (2002) Pulmonary arteriovenous malformation. *Postgrad Med J* 78: 191-197.
2. Cartin-Ceba R, Swanson KL, Krowka MJ (2013) Pulmonary arteriovenous malformations. *Chest* 144: 1033-1044.
3. Shovlin CL (2014) Pulmonary arteriovenous malformations. *Am J Respir Crit Care Med* 190: 1217-1228.
4. Lakshmi B, Dsouza S, Kulkarni A, Kamble J, Garasia M (2019) Pulmonary arterio venous malformations □ What the anesthesiologist must know, *Journal of Anaesthesiology Clinical Pharmacology* 35.
5. Xu Ma, Bing Jie, Dong Yu, Ling-Ling Li, Sen Jiang (2021) Massive haemorrhagic complications of ruptured pulmonary arteriovenous malformations: outcomes from a 12 years' retrospective study *BMC Pulmonary Medicine* 21: 230.
6. Ference BA, Shannon TM, White RI Jr, Zawin M, Burdige CM (1994) Life threatening pulmonary hemorrhage with pulmonary arteriovenous malformations and hereditary hemorrhagic telangiectasia. *Chest* 106: 1387-1390.
7. Shovlin CL, Jackson JE, Bamford KB, Jenkins IH, Benjamin AR, et al. (2008) Primary determinants of ischaemic stroke/ brain abscess risks are independent of severity of pulmonary arteriovenous malformations in hereditary haemorrhagic telangiectasia. *Thorax* 63: 259-266.
8. Kim JC, Lee KC, Choi JL, Lee HD, Kwak HJ (2009) Anaesthetic management of a patient with pulmonary arteriovenous malformation under total intravenous anaesthesia: A case report. *Korean J Anesthesiol* 56: 713-716.
9. D Tarry, M Powell (2017) Hypoxic pulmonary vasoconstriction. *BJA Education* 17: 208-213.
10. Pagel PS, Fu JL, Damask MC (1998) Desflurane and isoflurane produce similar alterations in systemic and pulmonary hemodynamics and arterial oxygenation in patients undergoing one-lung ventilation during thoracotomy. *Anesth Analg* 87: 800-807.
11. Kerbaul F, Guidon C, Stephanazzi J, Bellezza M, Le Dantec P, et al. (2001) Sub-MAC concentrations of desflurane do not inhibit hypoxic pulmonary vasoconstriction in anesthetized piglets *Canadian Journal of Anesthesia* 48: 760-767.