



Case Report

A Practical Approach to Acute Vertigo Using the HINTS Exam in Emergency Department: A Case Report

Helena Kons¹, Chinmay Patel^{1,2}, Chandler Winters³, Andrew Shedd^{1,2}, Jennifer A Walker^{1,2}, Eric H Chou^{1,2*}

¹Burnett School of Medicine at TCU, Fort Worth, TX, USA

²Department of Emergency Medicine, Baylor Scott and White All Saints Medical Center, Fort Worth, TX, USA

³School of Biomedical Sciences at UNT Health Science Center, Fort Worth, TX, USA.

***Corresponding author:** Eric H Chou, Department of Emergency Medicine, Baylor Scott and White All Saints Medical Center, Fort Worth, Texas, USA

Citation: Kons H, Patel C, Winters C, Shedd A, Walker J, et al (2023) A Practical Approach to Acute Vertigo Using the HINTS Exam in Emergency Department: A Case Report. Ann Case Report. 8: 1356. DOI:10.29011/2574-7754.101356

Received: 26 June 2023, **Accepted:** 30 June 2023, **Published:** 03 July 2023

Abstract

Acute vertigo represents a common chief complaint in the emergency department (ED). Its etiology is broad and warrants special consideration as it may represent more benign causes originating from a peripheral cause or may be indicative of central causes such as a posterior circulation infarct. Due to the limitations of neuroimaging during the acute phase of posterior circulation stroke presentation, the rate of misdiagnosis among these patients remains high, with some studies showing evidence of misdiagnosis rates of up to 59% [1]. Despite high rates of sensitivity and specificity of the Head Impulse, Nystagmus, and Test of Skew (HINTS) exam in distinguishing central from peripheral vertigo, its utilization in the emergency department remains low, often resulting in unnecessary workup and potentially missed diagnoses. With this case report, we aim to discuss the appropriate use of the HINTS exam as a diagnostic tool in determining the need for imaging in patients presenting to the emergency department with vertigo.

Keywords: Vertigo; Emergency Department; Diagnosis; Nystagmus

advanced imaging to highlight the utility of the HINTS exam when used in the appropriate patient population.

Introduction

Dizziness, or vertigo, is a common chief complaint in the emergency department (ED), comprising 2.5% of all emergency room visits [2]. Vertigo may represent benign etiologies such as Benign Paroxysmal Positional Vertigo (BPPV) or vestibular neuronitis/neuritis or may be indicative of life-threatening and time-sensitive etiologies such as posterior circulation stroke. Although imaging studies such as MRI can be used to aid in the differentiation of these diagnoses, it is time and resource intensive, and furthermore imaging alone is insufficient in ruling out posterior circulation infarcts as many are often undetectable on imaging at symptom onset [1]. We present this case of vestibular neuritis diagnosed with the HINTS exam and without the use of

Case Presentation

A previously healthy 52-year-old female with no significant past medical history presented to the ED with a two-week history of constant vertigo and unsteady gait, causing her to trip and fall. The patient denied any recent head trauma or inciting event and had never experienced these symptoms before. She denied vision changes, headache, loss of consciousness, recent fevers or chills, chest pain, abdominal pain, vomiting, or bowel or bladder dysfunction. The patient is a current daily smoker and smokes two packs of cigarettes per day. She drinks alcohol socially and denies any illicit drug use. All vital signs were within normal limits. Her neurological exam was negative for focal neurologic deficits or cranial nerve deficits, sensory deficits, truncal ataxia, or dysmetria.

The HINTS exam revealed horizontal unidirectional nystagmus and corrective saccade (See Video) <https://www.gavinpublishers.com/assets/videos/ACRT-1356.mp4>. Complete blood count revealed macrocytic polycythemia, which can likely be attributed to chronic tobacco usage. All other cell counts were normal. Serum glucose, troponin, sodium, potassium, BUN and creatinine were all within normal range. A non-contrast CT scan and CT angiography of the head and neck were all without intracranial abnormality. A diagnosis of peripheral vertigo was made, and this patient was discharged from the ED with prednisone and meclizine. From the follow up, a diagnosis of vestibular neuritis was made, and her symptoms resolved spontaneously shortly after her ED visit.

Discussion

Vertigo is often described by patients as the sensation of motion when one is standing still, usually as a sensation of spinning. Despite its commonplace in the emergency department, the evaluation of vertigo continues to present a diagnostic challenge for emergency physicians. The differential diagnosis of vertigo is large and complex, ranging from more benign peripheral etiologies such as BPPV or an acute peripheral vestibulopathy, or life-threatening central etiologies such as posterior circulation infarct or mass. The workup for suspected posterior circulation stroke in the ED typically comprises a thorough evaluation with history and physical exam, followed by a complete blood count, metabolic panel, finger stick blood glucose, coagulation panel, electrocardiogram, and imaging. Initial imaging is done using a non-contrast CT scan of the head, often followed by CT angiography of the head and neck, and diffusion-weighted MRI [3]. Although CT and MRI scans are helpful in the diagnosis of posterior circulation infarct, they alone cannot be used to rule out the presence of disease, thus complicating the disposition of patients presenting with vertigo. Furthermore, the sensitivity of diffusion-weighted MRI in the diagnosis of posterior circulation stroke during the acute phase is limited, with some studies revealing that at 4 days post symptom onset, up to one third of patients do not exhibit findings of stroke on diffusion-weighted MRI [4]. This is especially true in the case of smaller posterior circulation infarcts, which have shown to be negative for over 50% of patients within 48 hours of symptom onset [5]. In ED, the diagnostic challenge for acute vertigo to exclude acute intracranial etiology such as posterior circulation stroke results in multiple imaging studies, diagnostic testing, prolonged ED stay, and admissions. These additional tests increase both hospital and

patient costs of care and increase the radiation burden of patients presenting with benign forms of dizziness. Moreover, due to the high mortality associated with posterior circulation strokes, time to diagnosis is critical. Such trends indicate the need for a more reliable diagnostic tool of differentiating central versus peripheral vertigo. When performed appropriately, the HINTS exam has been reported to have a greater sensitivity in the diagnosis of stroke in patients with acute vestibular syndrome [6]. The HINTS exam is a neurologic bedside examination involving head impulse, nystagmus, and test of skew that is used to differentiate between central and peripheral causes of vertigo. In initial studies of the HINTS exam in patients presenting with vertigo, nystagmus, nausea/vomiting, head-motion intolerance, unsteady gait, the HINTS exam revealed a 100% sensitivity and 96% specificity for the presence of a central lesion in patients with dangerous findings on HINTS examination [6]. However, the HINTS exam remains a controversial diagnostic tool among emergency medicine physicians. Despite evidence suggesting that, the HINTS exam has a sensitivity of 96.7% and a specificity of 94.8% when performed by neurologists, subsequent studies have demonstrated a marked decrease in sensitivity and specificity of the HINTS exam when used in the emergency department [7]. Recent studies indicated that the decreased diagnostic utility of the HINTS exam in the emergency department may be the result of screening patients who do not meet criteria for the HINTS exam, rather than difference in exam administration or technique [8]. Despite widespread usage of the HINTS exam on patients presenting with dizziness, the utility of the HINTS exam is most optimal when performed on patients with acute onset, persistent vertigo [9]. In addition, due to the extremely high sensitivity of the HINTS exam in this subset of patients, we propose that it may be used as a screening tool that, combined with the evaluation of other risk factors, may aid in determining the need for imaging in patients presenting with acute onset, persistent vertigo. We propose a risk stratification to help identify patients at minimal risk of posterior circulation stroke, for whom a HINTS exam consistent with a peripheral lesion would support a plan for discharge and outpatient treatment (Figure 1). Certain characteristics such as male sex, increased age, dyslipidemia, peripheral vascular disease, atrial fibrillation, hypertension, renal dysfunction, oral contraception usage, obesity, smoking and alcohol use have been identified as significant risk factors for posterior circulation stroke [4]. The presence or absence of these risk factors may be used to aid clinical decision making when evaluating patients with acute, consistent vertigo.

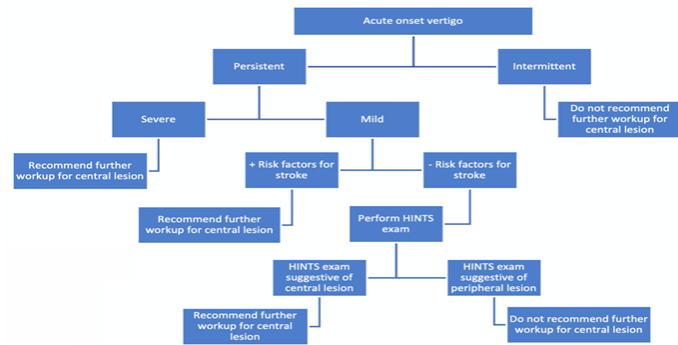


Figure 1: HINTS exam on Patients Presenting with Dizziness.

In ED, this approach can guide emergency physicians in determining which patients warrant further evaluation for a possible central lesion. Patients with acute onset, consistent vertigo that is mild in nature (i.e., the patient is ambulatory, can complete basic activities of daily living such as eating and drinking), without identified risk factors for stroke (i.e., cardiovascular disease, hypertension, age >60 years, positive smoking status, or prior history of stroke) who have findings on the head impulse test that are suggestive of a peripheral lesion (i.e., abnormal head impulse test) do not require further workup for evaluation of a possible central lesion. This algorithm would use the clinical value of the HINTS exam, and in particular the head impulse test, to allow for less radiation burden and a lower cost of care for patients with consistent vertigo with a low pretest probability of a central lesion being the primary etiology of their symptoms. However, more research is needed to develop a structured algorithm to incorporate the HINTS exam into clinical practice in the ED.

Conclusion

With this case report, a practical approach using the HINTS exam as a diagnostic tool is feasible in determining the need for imaging in patients presenting to the ED with acute undifferentiated vertigo.

References

1. Gurley KL, Edlow JA (2019) Avoiding misdiagnosis in patients with posterior circulation ischemia: A narrative review. *Academic Emergency Medicine*. 26: 1273-1284.
2. Kerber KA, Meurer WJ, West BT, Mark Fendrick A (2008) Dizziness presentations in U.S. emergency departments, 1995-2004. *Academic Emergency Medicine*. 15: 744-750.
3. Welsh L (2016) *Emra Em Fundamentals: The Essential Handbook for Emergency Medicine Residents*. EMRA.
4. Makin SDJ, Doubal FN, Dennis MS, Wardlaw JM (2015) Clinically confirmed stroke with negative diffusion-weighted imaging magnetic resonance imaging. *Stroke*. 46: 3142-3148.
5. Saber Tehrani AS, Kattah JC, Mantokoudis G, Pula JH, Nair D, et al (2014) Small strokes causing severe vertigo: frequency of false-negative MRIs and nonlacunar mechanisms. *Neurology*. 83: 169-173.
6. Kattah JC, Talkad AV, Wang DZ, Hsieh Y-H, Newman-Toker DE (2009) Hints to diagnose stroke in the acute vestibular syndrome. *Stroke*. 40: 3504-3510.
7. Ohle R, Montpellier RA, Marchadier V, et al (2020) CAN emergency physicians accurately rule out a central cause of vertigo using the hints examination? A systematic review and meta-analysis. *Academic Emergency Medicine*. 27: 887-896.
8. Dmitriew C, Regis A, Bodunde O, Lepage R, Turgeon Z, et al (2020) Diagnostic accuracy of the hints exam in an emergency department: A Retrospective Chart Review. *Academic Emergency Medicine*. 28: 387-393.
9. Kattah JC (2018) Use of hints in the acute vestibular syndrome. an overview. *Stroke and Vascular Neurology*. 3: 190-196.