



## Research Article

# Synchronous Breast and Thyroid Cancer: Correlation Between two Pathologies and Management Challenges

**Aliya Ishaq\*, Muhammad Jamshaid Husain khan, Warda Siddiqi, Deemah Al Abrach, Marwah Al Shamnee, Shaikha Alahjeri, Hafsa Areen, Maryam Hashi, Arfan Al Awa and Zaid Abdulaziz**

Dubai Hospital, Deira, Dubai, UAE

\*Corresponding author: Aliya Ishaq, Dubai Hospital, Deira, Dubai, UAE

**Citation:** Ishaq A, Khan MJH, Siddiqi W, Al Abrach D, Al Shamnee M, et al. (2023) Synchronous Breast and Thyroid Cancer: Correlation Between two Pathologies and Management Challenges. Arch Surg 3: 117 DOI: 10.29011/ AOS-116.000017

**Received Date:** 19 October, 2023; **Accepted Date:** 23 October, 2023; **Published Date:** 25 October, 2023

## Introduction

Co-occurrence of breast and thyroid cancer is reported in many case reports and case series, it is evident from literature that women diagnosed with breast cancer are two folds increased risk of developing thyroid cancer as compare to general population. On the other hand women diagnosed to have thyroid cancer have 67 % greater chance of developing breast cancer as compared to general population. Radiation therapy which is used in adjuvant treatment of breast cancer is likely to increase the incidence of thyroid cancer as well. There is some correlation between the two malignancies and common genetic, hormonal as well as environmental factors are attributed to be the reason for this co-relation. Thus, it is prudent to investigate patients diagnosed with breast cancer for thyroid malignancy and vice versa. If physical examination is negative for the second malignancy when one is diagnosed radiological investigations should be conducted to rule out concomitant disease [1]. Not only that the two malignancies are seen synchronously but metachronous involvement of both malignancies is also reported whether that is attributable to lack of initial evaluation of second malignancy when first was found or just a co-relation is not clear. Thyroid cancer was also seen more commonly when initial breast cancer was HER2-positive. This concomitant dual pathology is not gender specific and is even greater in men. Men with a previous history of breast malignancy are 19 times more likely to develop thyroid cancer and on the other hand men diagnosed with thyroid cancer are 29 times more likely to develop breast cancer when compared to general population [2].

Thyroid Receptors (TR) are encoded by two genes, TR $\alpha$  and TR $\beta$ , which are located on human chromosomes 17 and 3, respectively. Accordingly to one study performed among Chinese people, aberrant expression and mutations of the TR $\beta$ 1 gene were found to be associated with the development of breast cancer. Thus, it is said that thyroid hormone receptors play some role in breast cancer development. The most common thyroid cancer type found to be associated with breast cancer is papillary thyroid cancer (85.9%), follicular cancer (11%) is also found to be increased in frequency. Surprisingly, it is also found that Thyroglobulin gene polymorphism and autoimmune thyroid disease have high prevalence among breast cancer patients [3]. Survivors of Thyroid cancer have also been found to develop breast cancer earlier than general population and have more estrogen and progesterone receptor positive tumors, and a greater incidence of mixed invasive cancer. Estrogen receptors are present in thyroid tissue and estrogen is found to have an influence on thyroid glands. The histology of the breast cancer that develops after thyroid cancer is different than the general population [4]. Possible factors responsible for co-relation of these two malignancies are briefly discussed below.

## Genetic Factors Linking Both Malignancies

Both thyroid and breast cancers are seen in Cowden Syndrome which is an already recognized genetic disorder, arising from mutations to the tumor suppressor PTEN, which not only increases the risk of breast and thyroid malignancy but also increases the risk of both breast and thyroid cancers but also

endometrial and gastrointestinal cancers. In addition, germline mutations in PARP4 were identified in women treated for both these cancers [5].

### **Treatment Modalities for One Cancer are Risk Factor for Development of Other Cancer**

Radiation therapy used as adjuvant treatment for some breast cancers has poses increased risk for development of thyroid cancer on the other hand radioiodine <sup>131</sup>I used for treatment of thyroid cancer selectively targets the tumor via the sodium-iodide symporter (NIS) to destroy the diseased thyroid tissue. However, breast tissue expresses NIS to transport iodide into milk and so could be impacted by radioactive <sup>131</sup>I. There is also evidence that dietary iodide intake is protective against the development of breast cancer [6].

### **Impact of Thyroid Disease and Disruptions of Thyroid Hormone Signaling**

A small clinical study utilizing the patients with advanced cancers, including breast tumors showed that ablation of de novo thyroid hormone synthesis with supplemental T3 prolongs survival in these patient. It is also reported that use of tyrosine kinase inhibitors have an impact on patients out come with positive predictive value and patients with cancers other than thyroid cancer rendered hypothyroid after treatment with tyrosine kinase inhibitor have a more favorable prognosis. Another large meta-analysis including patients from both Western- and non-Western countries have demonstrated an increased risk of thyroid cancer as a secondary malignancy following breast cancer [OR=1.55; 95% confidence interval (CI), 1.44-1.67] and an increased risk of breast as a secondary malignancy following thyroid cancer (Odds ratio (OR)=1.18; 95% CI, 1.09-1.26) [7].

### **Treatment Challenges**

If found to be concomitantly present then treating both entities poses challenge for both physicians and surgeons weather to treat them simultaneously or one before the other and weather treating one before the other has any effects on survival of the other. Its more challenging for surgeons as simultaneous surgery for both malignancies specially if radical lymph node dissection is needed can really prolong time for surgery. This is specially true when both pathologies need surgery and both surgeries are major for example modified radical mastectomy with total thyroidectomy and neck dissection. As performing both surgeries together increases operative times as well as morbidity and mortality related to prolonged surgery. Performing mastectomy first and then thyroidectomy in the follow-up period may result in delay of the chemotherapy and radiotherapy.

### **Time Limit for Delaying Surgery**

Initially it was thought that delay to curative surgery greater than 12 weeks is associated with increased mortality in patents with colorectal and breast cancer but not lung or thyroid cancer so if taken in to consideration it was easy to first finish with treatment of breast cancer followed by thyroid cancer once patient recovers from breast cancer treatment But now it is evident that delay in surgery for thyroid cancer for more than 180 days decrease disease free survival and over all survival four times. In patients with T2 disease all cause mortality increases double the normal if surgery id delayed beyond 180 days [8]. Two surgeries can be performed simultaneously safely provided operative time is not prolonged enough to increase morbidities related to surgery [9].

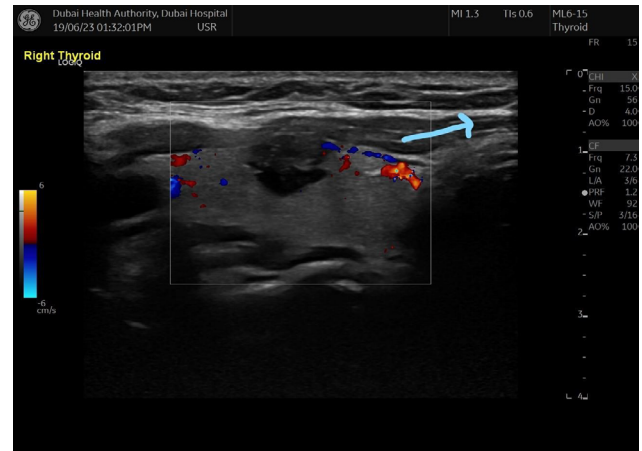
### **Our Experience**

Recently we came across with Three cases of synchronous breast and thyroid cancers. All four patients were diagnosed with breast cancer first and while doing metastatic work up were found to have suspicious thyroid nodule and fine needle aspiration cytology of these nodules in all cases showed papillary thyroid cancer.

#### **Case 1**

A 38 years old four months pregnant lady presented with 4 x 5 cm left breast mass with clinically and radiologically negative axilla ,triple assessment showed infiltrating ductal carcinoma Triple negative. She had positive family history of breast cancer sister diagnosed at age of 45 years. Metastatic work up done and CT SCAN chest showed right sided thyroid nodule for which us was done and showed 9 x 7 mm suspicious right thyroid nodule with calcifications and perilesional vascularity. Fine needle aspiration cytology showed papillary thyroid cancer. Case was discussed in breast and thyroid tumor board meeting including the option of active surveillance for thyroid cancer as it was less than 1 cm and active surveillance is an option for such tumors. It was decided to start her on neoadjuvant chemotherapy followed by delivery and reassessment of mass and then to accomplish surgical management for both breast and thyroid. She showed complete clinical response to neoadjuvant chemotherapy. At 36 weeks baby was delivered normally. After delivery she continued and completed neoadjuvant chemotherapy. She showed complete clinical and radiological response. It was a challenge to take decision weather to go-ahead for breast surgery and deal with thyroid later. But what op she will require post of adjuvant chemo and radiotherapy ?, how long will it take ? and will there will be any effect on disease free and over all survival for thyroid cancer in case of delay ?, further more completing breast treatment will render her immunocompromised and thyroid surgery and healing will be effected if done after completing breast surgery. On the

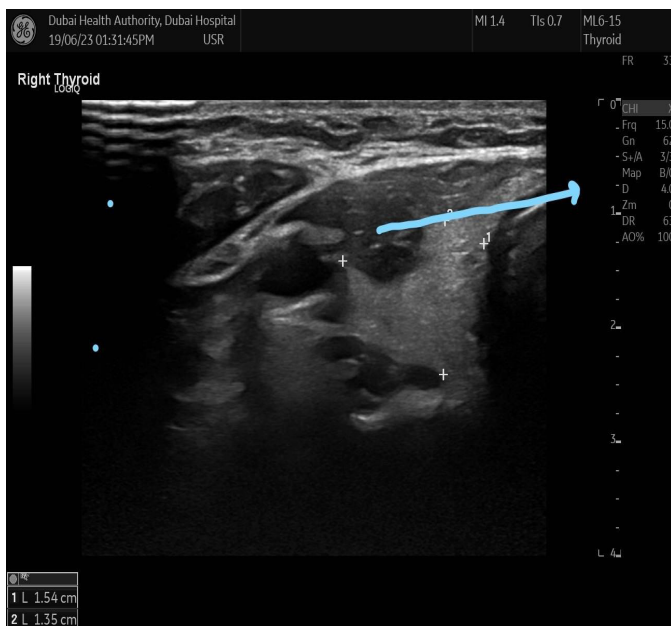
other hand performing both surgeries was associated with increase timing of surgery in this case because she needed guide wire localization where specimen is sent for Mammographic detection after excision and also she needed sentinel lymph node where one has to wait for histopathology and if positive to goaded with axillary clearance. It was a challenging decision for MDT and after discussion it was decided to go for both surgeries together starting with breast first and regarding thyroid it was decided to go for right hemithyroidectomy as tumor was less than 1 cm and no nodal dissection as there was no evidence of nodal involvement. In our institute we follow American thyroid association guide lines and we do hemithyroidectomy for all thyroid cancers 4 cm or less unless there is evidence of locally advanced disease with small tumors and for lymph node dissection we don't do prophylactic neck dissections all patients are scanned for lymph node mapping and any suspicious lymph nodes are biopsied ,only biopsy proven case go for neck dissection unless there is advanced local disease where prophylactic central neck dissection is indicated. Surgery was done, It took 180 minutes for both procedures. First breast surgery was done and sentinel lymph node came negative so no axillary dissection was done. Patient's neck was positioned for thyroidectomy only after finishing breast surgery. Post operative recovery was uneventful and final histology for breast showed complete pathological response and for thyroid it was PT1a,papillary thyroid cancer. She was started on adjuvant chemo with radiotherapy and completed treatment successfully as she had more than 4 cm breast cancer and was triple negative with young age and family history (Figures 1,2).



**Figure 2:** Us thyroid showing increased perilesional vascularity.

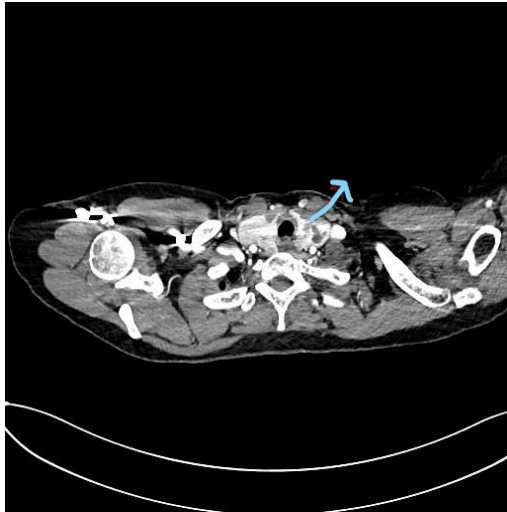
**Case 2**

A 57 years old female patient presented with Left breast 2 x 2 cm mass ,triple assessment showed infiltrating ductal carcinoma ER/PR positive and Her 2 negative with no axillary Mets. On metastatic work up she was found to have right thyroid nodule 2.4 x 1.7 cm at mid pole and FNAC showed papillary thyroid cancer with no lymph node involvement. Her case was discussed in Breast and Thyroid MDT and it was decided to discuss the option of total thyroidectomy (with out lymph node dissection as there are no suspicious lymph nodes on ultrasound mapping) with patient as she has bilateral multiple nodules and if hemithyroidectomy is opted she has to be on life long surveillance for for nodules on contralateral side and regarding breast it was decided to go for mastectomy and sentinel lymph node biopsy as size of breast was very small. Patient opted for hemithyroidectomy and agreed for life long surveillance for contralateral thyroid lobe. She underwent Left mastectomy and sentinel lymph node biopsy ,sentinel lymph node was negative so she did not require axillary clearance. After completing breast surgery position and preparation was done for thyroidectomy and she underwent right hemithyroidectomy.Total time for surgery was 220 minutes and breast surgery was done first followed by positioning for thyroid surgery. Her post operative course was uneventful. Breast histopathology showed IDC G2 2.5cm unifocal, with DCIS , no LVI, no microcalcifications, margins free for invasive and DCIS 0/3 lymph nodes pT2N0(sentinel lymph node)M0-and thyroid H/P showed PT1b ,papillary thyroid cancer. However ,it was a multifocal papillary thyroid cancer(total of 3 foci 1.5 mm ,2 mm ,3 mm ) ,no capsular or lymph vascular invasion and clear margins. Post operative discussion in thyroid and breast Tumor MDT was done and she underwent oncotype DX for breast which came as score of 15% and it was decided not to give her chemotherapy and to keep her on hormonal treatment only for breast cancer. For

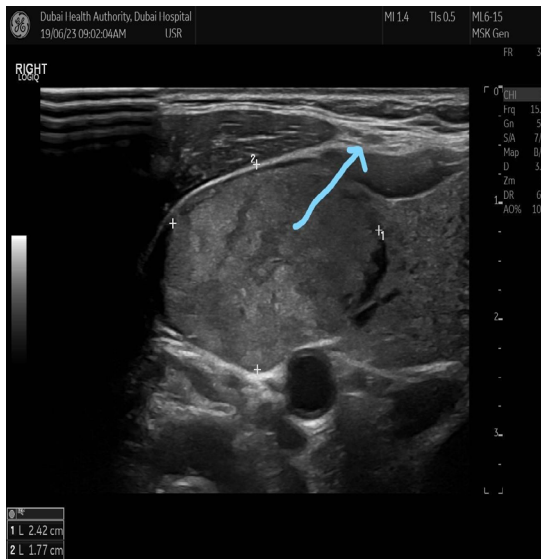


**Figure 1:** Us showing suspicious thyroid nodule.

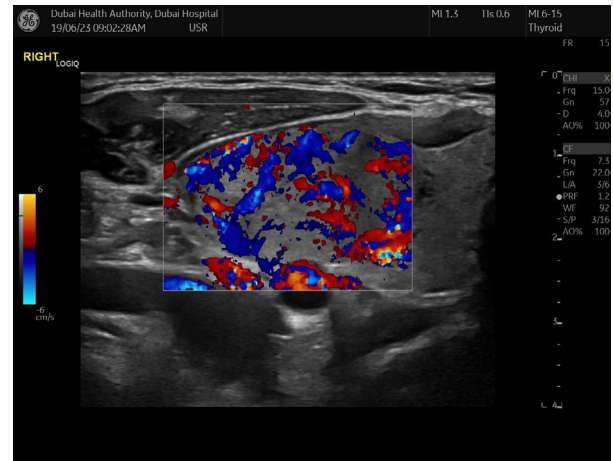
thyroid it was decided to keep her on active surveillance and no further surgery. She was started on hormone therapy and completed the course with out any complications. Repeat thyroid scan and work up did not show any disease progression (Figures 3-5).



**Figure 3:** CT SCAN done for breast metastatic work up showing suspicious left thyroid nodule.



**Figure 4:** Us neck showing left thyroid suspicious nodule.



**Figure 5:** Us neck showing left thyroid suspicious nodule.

### Case 3

72 Years old female with hypertension ,DM ,CCF ,osteoporosis ,cervical spondylosis and renal impairment with ASA classification IV diagnosed by triple assessment as having infiltrating breast cancer ER/PR positive Her 2 negative with lymph node metastasis ,Tumor size was 4 x 5 cm. Metastatic work up showed left thyroid sub centimetric nodule with FNAC showing papillary thyroid cancer. Because of her and comorbidities MDT decided mutually with family agreement to go for Modified Radical Mastectomy followed by hormonal treatment and regarding papillary thyroid cancer it was decided to observe and do active surveillance as she is high risk surgical candidate and her cervical spondylosis will post a risk as well for neck extension. Histopathology for breast showed Stage IIB (T2, N1, cM0). She completed surgery and is on hormonal therapy ,her us thyroid was done twice with an interval of 6 months and up till now there is no evidence for disease progression.

### Discussion

Management of synchronous and metachronous breast and thyroid malignancies really poses challenges and needs multidisciplinary approach with involvement of surgeon ,oncologist ,endocrinologist ,histopathologist ,radiation oncologist as well as radiologist , patient and family in decision making. As far as surgery is concerned both can be operated simultaneously provided



operative time is kept in reasonable limits. Exact operating time is an individualized entity and varies from case to case depending on size of both tumors as well as lymph node involvement and technical difficulties and morbidities associated with patient. All our patients had localized disease and none required neck dissection, which led to reasonable operative time ( between 120 – 220 minutes ) and good recovery. Active surveillance is also an option for low risk thyroid cancers. Active surveillance needs high quality ultrasound examination every 6 months, surgery is recommended when the cancer exhibits an increase in size as defined by (a) a 3 mm increase in axial dimension or (b) a >50% increase in tumor volume with a short doubling time or in tumors located immediately adjacent to the thyroid capsule [10].

Our operating time was mainly due to breast cancers as two patients required sentinel lymph node biopsy which takes long because of technical and logistic issues and also one patient required guide wire localization biopsy and although small procedure in itself but time consumed was more as specimen was sent to radiology for mammogram and transportation and receiving and handling and sending back all contributed to delay which is expected and can not be avoided.

## Conclusion

Delay in surgery in patients with papillary thyroid cancer up to 12 weeks does not increase DSS and OS when compared to breast and colonic cancer however if time to surgery increases to more than 90 days DSS and OS is decreased and specially increasing time to surgery for more than 180 days decrease DSS and OS to four times and also doubles all cause mortality [11] therefore, simultaneous surgical management of synchronous breast and thyroid cancers is a safe option provided expertise are available and is associated with good results [12]. However, it becomes challenging for T3, T4 lesions specially if associated with involved lymph nodes requiring radical nodal dissection for both the malignancy simultaneously as it can significantly increase operative time and morbidity related to prolonged surgery, anesthesia and patient's positioning.

## References

1. Arer İM, Yabanoğlu H, Kuş M, Akdur A, Avcı T (2018) Retrospective Analysis of Patients with Synchronous Primary Breast and Thyroid Carcinoma. *Eur J Breast Health* 14: 80-84.
2. Shin DW, Cho J, Kim SY, Guallar E, Hwang SS, et al. (2013) Delay to curative surgery greater than 12 weeks is associated with increased mortality in patients with colorectal and breast cancer but not lung or thyroid cancer. *Ann Surg Oncol* 20: 2468-2476.
3. Ling Y, Ling X, Fan L, Wang Y, Li Q (2015) Mutation analysis underlying the downregulation of the thyroid hormone receptor  $\beta$ 1 gene in the Chinese breast cancer population. *Onco Targets Ther* 8: 2967-2972.
4. Nielsen SM, White MG, Hong S, Aschebrook-Kilfoy B, Kaplan EL, et al. (2016) The Breast-Thyroid Cancer Link: A Systematic Review and Meta-analysis. *Cancer Epidemiol Biomarkers Prev* 25: 231-238.
5. Gammon A, Jaspersen K, Champine M (2016) Genetic basis of Cowden syndrome and its implications for clinical practice and risk management. *Appl Clin Genet* 9: 83-92.
6. De la Vieja A, Riesco-Eizaguirre G (2021) Radio-Iodide Treatment: From Molecular Aspects to the Clinical View. *Cancers (Basel)* 13: 995.
7. Liu Y-C, Yeh C-T, Lin K-H (2019) Molecular Functions of Thyroid Hormone Signaling in Regulation of Cancer Progression and Anti-Apoptosis. *Int. J. Mol. Sci* 20: 4986.
8. Tjoe JA, Heslin K, Perez Moreno AC, Thomas S, Kram JJF (2022) Factors Associated With Breast Cancer Surgery Delay Within a Coordinated Multihospital Community Health System: When Does Surgical Delay Impact Outcome? *Clin Breast Cancer* 22: e91-e100.
9. Kuo JH, Chabot JA, Lee JA (2016) Breast cancer in thyroid cancer survivors: An analysis of the Surveillance, Epidemiology, and End Results-9 database. *Surgery* 159: 23-29.
10. Haugen BR, Alexander EK, Bible KC, Doherty GM, Mandel SJ, et al. (2015) American Thyroid Association Management Guidelines for Adult Patients with Thyroid Nodules and Differentiated Thyroid Cancer: The American Thyroid Association Guidelines Task Force on Thyroid Nodules and Differentiated Thyroid Cancer. *Thyroid* 26: 1-133.
11. Chaves N, Broekhuis JM, Fligor SC, Collins RA, Modest AM, et al. (2023) Delay in Surgery and Papillary Thyroid Cancer Survival in the United States: a SEER-Medicare Analysis. *J Clin Endocrinol Metab* 2023.
12. Pontius LN, Oyekunle TO, Thomas SM, Stang MT, Scheri RP, et al. (2017) Projecting Survival in Papillary Thyroid Cancer: A Comparison of the Seventh and Eighth Editions of the American Joint Commission on Cancer/Union for International Cancer Control Staging Systems in Two Contemporary National Patient Cohorts. *Thyroid* 27: 1408-1416.