



Case Report

Live-Born with a Trisomy 22 Mosaic: A Case Report

Barbara Baur Cavegn*, Julia Popelka, Suekrue Arioglu, Monya Todesco Bernasconi

Women's Department, Kantonsspital Aarau, Switzerland Tellstrasse, Switzerland

***Corresponding author:** Barbara Baur Cavegn, Women's Department, Kantonsspital Aarau, Switzerland Tellstrasse, Switzerland

Citation: Baur Cavegn B, Popelka J, Arioglu S, Todesco Bernasconi M (2023) Live-Born with a Trisomy 22 Mosaic: A Case Report. Ann Case Report 8: 1405. DOI: 10.29011/2574-7754.101405

Received Date: 08 August 2023; **Accepted Date:** 12 August 2023; **Published Date:** 15 August 2023

Abstract

Trisomy 22 mosaic is compatible with life with different degrees of neurological impairment. Diagnosis is often established in the second trimester due to malformations detected by ultrasound and subsequent amniocentesis. We report a case of a 36-year-old GIII, where the diagnosis was already established in the first trimester due to an abnormal combined first-trimester test and an abnormal result in a non-invasive prenatal test (NIPT) showing an increased signal for chromosome 22. Ultrasound examination revealed cardiac malformations and an abnormal fetal profile. Additionally, there was the suspicion of a situs inversus abdominis. We performed amniocentesis at 18 weeks of gestation which confirmed the diagnosis of trisomy 22 mosaic. The couple decided to continue the pregnancy. At 29 weeks the patient was admitted due to vaginal bleeding and uterine contractions. The ultrasound on admission showed intrauterine growth restriction. A cesarean section was performed at 30 weeks due to recurrent vaginal bleeding and worsening of fetal hemodynamics. A premature female with a birth weight of 670g (< 3rd percentile) and an APGAR score of 5/7/7 was delivered. Postnatally heterotaxy syndrome and azygos continuation with additional vascular anomalies and multiple ventricular septal defects (VSD) were confirmed. Postnatal FISH was considered compatible with a low-grade trisomy 22 mosaic. The girl is now nearly 4 years old and shows severe neurological and sensory-motor deficits. Counseling of parents with a fetus with trisomy 22 mosaic is extremely difficult since there is no correlation between the degree of mosaicism and neurological impairment.

Introduction

Trisomy 22 is a common cause for spontaneous abortions in the first trimester [1]. The incidence of intrauterine death is very high and children born with a full trisomy 22 have a short life expectancy of only a couple of days [2,3]. Trisomy 22 mosaic on the other hand is compatible with life but is a rare condition [4]. Abdelgadir, [5] et al have previously summarized the most common clinical features. A lot of them can already be identified prenatally in the hands of a skilled sonographer. High maternal age seems to be a risk factor. Affected fetuses are more often female with a ratio of 1:1.6. Intrauterine growth restriction is present in up to 80% and postnatally failure to grow is seen in 70% of the affected children. In most cases, facial dysmorphism is detectable and about 75% show a congenital heart disease, most often ventricular septal defect (VSD), or atrial septal defect (ASD). Other clinical features

include genitourinary tract abnormalities, hearing loss, hypotonia, and body asymmetry

Case Report

A 36-year-old GIII PI (1 healthy 6-year-old son and one early miscarriage) was first referred to our clinic at 16 2/7 weeks of gestation. The combined first-trimester screening had shown an increased risk of 1:139 for trisomy 21 despite a normal neck translucency and therefore a cell-free DNA test was performed. This test showed an increased signal for chromosome 22 and the patient was referred for counseling and invasive testing. During the first consultation, a detailed ultrasound examination was performed, which showed a female fetus with biometry in the normal range.

The profile showed a prominent forehead and mild retrognathia (figure 1).

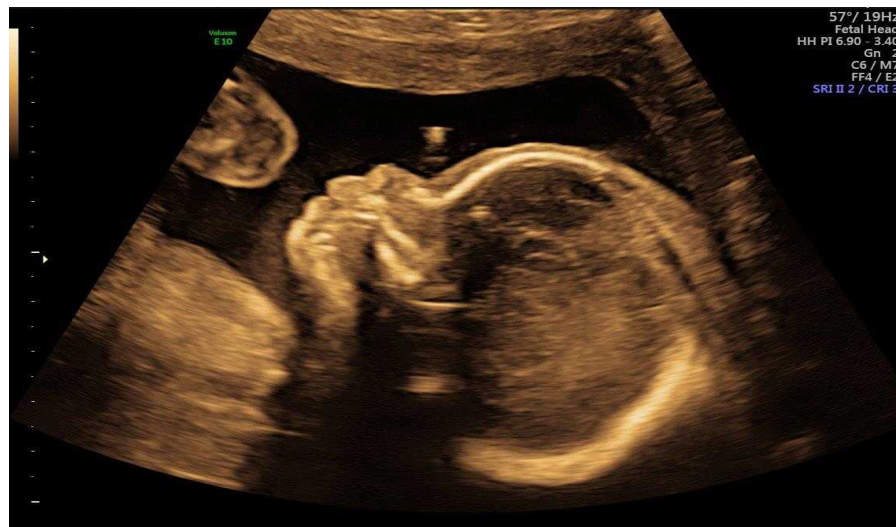

Figure 1: Midsagittal scan of the fetal profile (B mode).

Neurosonography was unremarkable as far as assessable at early gestational age. The stomach could not be visualized in the left upper abdomen. In the right upper abdomen, a cystic structure was visible and therefore a situs inversus abdominalis could not be excluded. Fetal echocardiography revealed abnormal atrioventricular (AV) valves, and an atrioventricular septal defect (AVSD) or an atrioventricular canal defect was suspected. There was also reversed flow in the ductus venosus (DV). The couple was informed in detail about the findings and genetic investigation by amniocentesis was recommended. After a reflection period, amniocentesis was performed without any complications at 17 3/7 weeks gestation. 5 out of 7 cell clones showed a free trisomy 22, revealing a trisomy 22 mosaicism.)

Another detailed ultrasound examination was performed at 20 weeks of gestation and showed a perimembranous VSD and a suspected ASD. The forehead was still prominent and there was no stomach in the left upper abdomen. In addition, we found a cystic structure in the cerebellar region (figure 2).

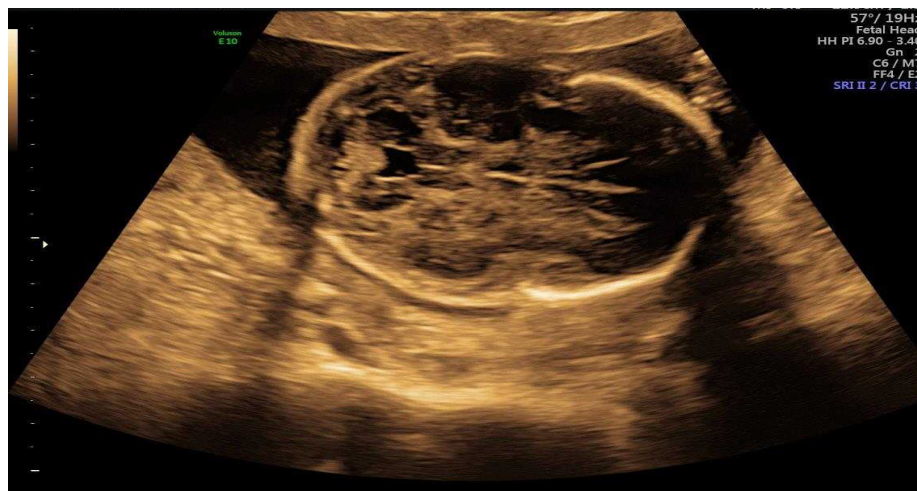

Figure 2: transverse scan of the cystic lesion in the cerebellum (B mode).

The couple decided to continue the pregnancy after receiving extensive genetic counseling by a human geneticist. At 29 weeks of gestation, the patient presented at our clinic with vaginal bleeding and uterine contractions. The patient was admitted and received respiratory distress syndrome prophylaxis with betamethasone and tocolysis with betamimetics. Subsequently, the bleeding decreased.

Ultrasound on admission showed an intrauterine growth restriction with an estimated fetal weight below the 3rd percentile. Fetal echocardiography by a pediatric cardiologist confirmed the findings of a subaortic VSD and an ASD. In addition, azygos continuation with drainage into the left atrium was evident (figure 3).

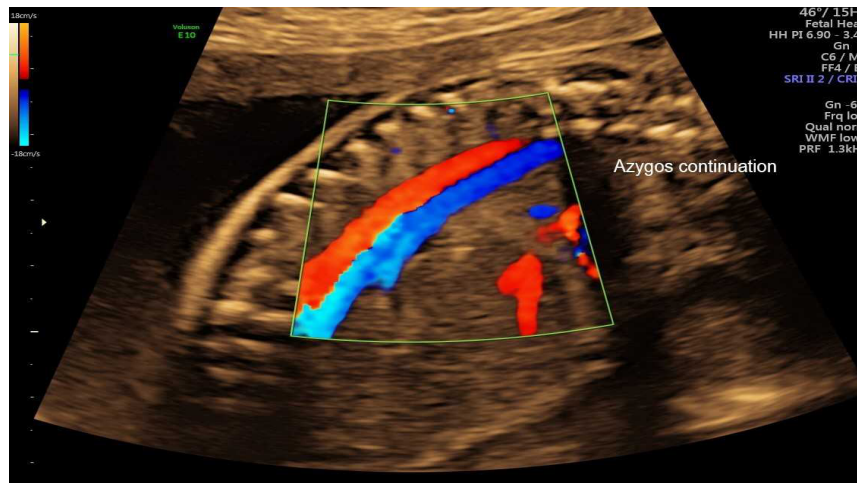


Figure 3: Longitudinal scan of Azygos continuation (color flow)

Because of the recurrence of vaginal bleeding, abnormal fetal heartbeats, and worsening of fetal hemodynamics an emergency cesarean section was performed at 29 2/7 weeks of gestation. A female fetus was born with a birth weight of 670g (< 3rd percentile) with an APGAR score of 5/7/7 and an arterial pH of 7.29.

The newborn was primarily transferred to neonatology. Initially, conventional ventilation was used, and later the child was switched to CPAP. Postnatal echocardiography confirmed a perimembranous VSD. There was no evidence of ASD, but there was an absent inferior vena cava with azygos continuation and persistent left superior vena cava. Neurosonography initially showed multiple patchy hyperechogenic lesions with cystic transformation. Ischemic damage due to intrauterine hypoxia was postulated. A cystic structure was identified in the area of the 4th ventricle. In the course, the cystic changes were regressive and bilateral dilatation of the lateral ventricles were seen. Neurologic examination revealed trunk hypotonia with increased lower extremity muscle tone and uncoordinated spontaneous motor activity.

An abdominal ultrasound showed a heterotaxy syndrome with situs ambiguous abdominalis with midline liver, dextroponed stomach and polysplenia. The baby was discharged after 15 weeks with no major complications. The girl is currently 3 years and 4 months old and lives at home with her parents. She is able to roll from belly to back but is not able to walk, despite wearing leg braces, or sit independently. She has no ability to speak and is fed through a jejunal tube. She also suffers from massive gastroesophageal reflux.

Her cardiac situation has been stable so far.

Discussion

Trisomy 22 mosaic is a rare condition and is most often diagnosed in the 2nd trimester through an abnormal ultrasound and subsequent amniocentesis. In our case, the combined first-trimester screening and the NIPT already showed an abnormal result leading to an early diagnosis through amniocentesis. Previous studies on rare autosomal aneuploidies (RAAs) at NIPT showed that these results might suggest an increased risk of confined placental mosaicism (CPM) or fetal mosaic aneuploidy [6]. In our case, the fetus showed many of the previously described typical features of a trisomy 22 mosaic: being female, congenital heart disease, and intrauterine growth restriction [5]. In addition, we also diagnosed heterotaxy syndrome which seems to be a rarity. To our knowledge, there is no case described in the literature with trisomy 22 mosaic and heterotaxy syndrome. Another feature of our case - polysplenia - has been previously reported [7]. The prenatal counseling of parents having a baby with trisomy 22 mosaic is very difficult since there is no correlation between the degree of affected cells and the severity of the development delay [8]. There also seems to be a tissue specificity in trisomy 22 mosaicism with a discrepancy between affected lymphocytes in the peripheral blood and skin fibroblasts. Therefore, fetal blood examination to confirm a trisomy 22 mosaic, can be misleading [9,10].

In our case, the rate of cells with trisomy 22 mosaic in the cord blood was only 10%. In the literature, there are reports of affected children with normal neurological development although no child was older than 5 years at evaluation [5,8,11-13].

Our case shows severely impaired neurological development. In addition to her trisomy 22 mosaic, the child was also born extremely premature which might have contributed to her neurological impairment. Signs of intrauterine hypoxia found on the postnatally performed neurosonography strengthen this hypothesis. In summary, we detected a very rare genetic condition early in pregnancy through first-trimester tests, NIPT, and subsequent amniocentesis. The case is special because in addition to the usual findings of trisomy 22 mosaics, our fetus also showed a heterotaxia which so far has not been described in the literature.

Data availability: Data supporting this case report are available from the corresponding author on reasonable request.

Consent: Written informed consent was obtained from the patient for the publication of this case report.

Conflict of Interest: The authors declare that they have no conflicts of interest.

References

1. Hassold TJ (1980) A cytogenetic study of repeated spontaneous abortions. *Am J Hum Genet* 32: 723-730.
2. Stressig R, Kortge-Jung S, Hickmann G, Kozlowski P (2005) Prenatal sonographic findings in trisomy 22: five case reports and review of the literature. *J Ultrasound Med* 24: 1547-1553.
3. Kehinde FI, Anderson CE, McGowan JE, Jethva RN, Wahab AM, et al. (2014) Co-occurrence of non-mosaic trisomy 22 and inherited balanced t(4;6)(q33;q23.3) in a liveborn female: case report and review of the literature. *Am J Med Genet A* 164A: 3187-3193
4. Chen CP, Huang MC, Chern SR, Wu PS, Chen SW, et al. (2019) Mosaic trisomy 22 at amniocentesis: Prenatal diagnosis and literature review. *Taiwan J Obstet Gynecol* 58: 692-697.
5. Abdelgadir D, Nowaczyk MJ, Li C (2013) Trisomy 22 mosaicism and normal developmental outcome: report of two patients and review of the literature. *Am J Med Genet A* 161A: 1126-1131
6. Gou L, Fang Y, Wang N, Zhang M, Liu T, et al. (2020) Clinical management of pregnancies with positive screening results for rare autosomal aneuploidies at a single center. *J Int Med Res*.
7. Allotey J, Lacaille F, Lees MM, Strautnieks S, Thompson RJ, et al. (2008) Congenital bile duct anomalies (biliary atresia) and chromosome 22 aneuploidy. *J Pediatr Surg* 43: 1736-1740
8. Florez L, Lacassie Y (2005) Mosaic trisomy 22: report of a patient with normal intelligence. *Am J Med Genet A* 132A: 223-225.
9. Mazza V, Latella S, Fenu V, Ferrari P, Bonilauri C, et al. (2010) Prenatal diagnosis and postnatal follow-up of a child with mosaic trisomy 22 with several levels of mosaicism in different tissues. *J Obstet Gynaecol Res* 36: 1116-1120.
10. Covington JD, Campbell C, Burke LW, Gardner JA (2018) Tissue Specificity in Trisomy 22 Mosaicism: A Tale of Caution for Interpretation of Chromosomal Microarray Results. *J Assoc Genet Technol* 44: 137-140.
11. Leclercq S, Baron X, Jacquemont ML, Cuillier F, Cartault F (2010) Mosaic trisomy 22: five new cases with variable outcomes. Implications for genetic counselling and clinical management. *Prenat Diagn* 30: 168-172.
12. Merks JH, Ceelie N, Caron HN, Hennekam RC (2004) Neuroblastoma, maternal valproic acid use, in-vitro fertilization and family history of mosaic chromosome 22: coincidence or causal relationship? *Clin Dysmorphol* 13: 197-198.
13. Thomas S, Parker M, Tan J, Duckett D, Woodruff G. (2004) Ocular manifestations of mosaic trisomy 22: a case report and review of the literature. *Ophthalmic Genet* 25: 53-56.