



Research Article

# A Sodium Hyaluronate-Based Oral Formulation as Adjuvant for Radiofrequency with Radioporation Treatment in Women with Vulvovaginal Atrophy: a Preliminary Study

Bertozzi Elena<sup>1</sup>, Nobile Vincenzo<sup>2\*</sup>, Tursi Francesco<sup>2</sup>, Vicariotto Franco<sup>3</sup>

<sup>1</sup>Poliambulatorio Sirio, 43036 Fidenza, PR, Italy.

<sup>2</sup>R&D Department, Complife Italia S.r.l., 27028 San Martino Siccomario, PV, Italy.

<sup>3</sup>Humanitas S. Pio X, 20159 Milano, MI, Italy.

\*Corresponding author: Nobile V, R&D Department, Complife Italia S.r.l., 27028 San Martino Siccomario, PV, Italy.

**Citation:** Bertozzi E, Nobile V, Tursi F, Vicariotto F (2023) A Sodium Hyaluronate-Based Oral Formulation as Adjuvant for Radiofrequency with Radioporation Treatment in Women with Vulvovaginal Atrophy: a Preliminary Study. J Nurs Women's Health 8: 194. DOI: <https://doi.org/10.29011/2577-1450.100094>

**Received Date:** 27 July, 2023; **Accepted Date:** 31 July, 2023; **Published Date:** 03 August, 2023

## Abstract

This interventional clinical study aimed to assess the efficacy of the oral intake of a food supplement containing 200 mg sodium hyaluronate (SH) as adjuvant of the radiofrequency (RF) and radioporation (RP) treatment in menopausal women suffering of vulvovaginal atrophy. The study was carried out in thirty menopausal patients with diagnosis of vulvovaginal atrophy who underwent radiofrequency and radioporation treatments. Half of the test subjects received the test food supplement. The primary outcome was the improvement in vaginal functional wellbeing while the secondary endpoint related to the persistence of vaginal atrophy symptoms. Sodium hyaluronate was effective in improving ( $p < 0.001$ ) the vaginal healthy status and in decreasing ( $p < 0.001$ ) the persistence of vaginal atrophy symptoms both during the treatment and at the follow-up. The study results demonstrated the clinical relevance of the SH intake in improving the vaginal symptoms during the RF/RP treatment, a prolongation of the benefits achieved at the end of the RF/RP treatment, and in maintaining the hydration of vagina. In conclusion SH intake can be a valid support in improving the vaginal functional wellbeing, in delaying the recurrence of vaginal atrophy symptomatology when administered in combination with the FR/RP treatment, and in preventing the relapse of vulvovaginal atrophy.

**Keywords:** sodium hyaluronate; vulvovaginal atrophy; women's health; symptoms improvement; radiofrequency; radioporation; menopause

## Introduction

During the menopausal period the declined ovarian function results in a drastic reduction of estrogen hormone secretion which leads to important endocrine, somatic, and psychological changes [1]. During this period, women are bothered by unpleasant

symptoms responsible for physical discomforts and lower quality of life.

The vulvovaginal atrophy (VVA) is a common genitourinary syndrome of menopause (GSM) associated with a decreased level of estrogen hormone in the vaginal tissue [2, 3]. Symptoms include dryness, irritation, soreness, decreased lubrication, dyspareunia, dysuria, and urinary symptoms of urgency leading to an increased risk of recurrent urinary infections as well as a serious discomfort [4, 5]. VVA is chronic, progressive and if not treated, the VVA

symptoms cannot only cause discomforts but can also progress into a worse condition impacting women's quality of life including emotional wellbeing and sexual relationship [6].

First-line therapies for GSM include non-hormonal, long-acting vaginal moisturizers, and low-dose vaginal estrogens [7]. Additional pharmacological therapies include intravaginal dehydroepiandrosterone (DHEA) ovules [8], ospemifene [9] and systemic hormone replacement therapy (HRT) [10]; while vitamin D and E vaginal suppositories [11] and oil-in-water (O/W) emulsion for vaginal application [12] represent the most common non-hormonal GSM treatments. The systemic hormone therapy is not always well tolerated, and many women do not want to undergo such a therapy.

In this context, hyaluronic acid (HA or SH in its sodium salt form) could represent a valid alternative. Recent studies demonstrated the efficacy of HA formulations in restoring a normal and healthy vaginal status, thus reducing the symptoms severity overall, with a good efficacy and safety profile [13-19]. HA is a naturally occurring polymer, involved in several physiological processes, including tissue homeostasis and regeneration, wound healing, inflammation, cell migration and proliferation, and embryonic development [20]. Studies showed that vaginal gel containing HA applied in vagina for a month resulted effective in reducing the atrophy as efficiently as estrogenic therapy [16, 21]. In a more recent study, hyaluronate based pessaries led to a significant improvement of the Vaginal Health Index (VHI) parameters (elasticity, vaginal secretion, pH, mucosa integrity, and lubrication degree), but also in patients' perception of VVA symptoms, sexual function, and vaginal maturation [17].

Among mechanical treatments used to restore the vulvovaginal tissue, laser therapy may be considered to induce vaginal tissue remodeling, promote collagen synthesis, thus increasing elasticity and integrity of the vaginal epithelium [22, 23]. An improvement in laser therapies or other treatments based on thermal energies has been achieved by coupling radiofrequency (RF) technology with electroporation (RP) technique. RF is based on thermal energy and acts on fibroblasts stimulating the epithelium proliferation and the collagen production, leading to an increment in fibers elasticity and a better vaginal lubrication [24, 25]. RP (applied in case of atrophy), through a quick impulse of an external electric field, generates a polarization of the membrane that causes a variation in cell membrane permeability, allowing to introduce dipolar molecules, such as HA, in cells [26, 27]. The procedure is usually well tolerated by patients since it is short and do not require anesthesia.

Recently the efficacy of clinical protocols based on coupling a proprietary low-energy Dynamic Quadripolar Radiofrequency technology (DQRFTM) with a proprietary Ultra-Pulsed Radioporation (UPRTM) for application of a hyaluronic acid gel in

women with post-menopausal VVA have been reported, indicating a synergy between the biological effect of the radiofrequency treatment and the effect of the topical active principle used in the studies [28, 29].

The aim of this study was to assess the efficacy of the oral intake of a sodium hyaluronate based food supplement as adjuvant of the radiofrequency and radioporation treatment in menopausal women suffering of vulvovaginal atrophy.

## Materials and Methods

### Study design, settings and locations, and participants

Thirty women, patient of the Sirio outpatient clinic (Fidenza, Italy), were enrolled in the present interventional clinical trial. All the subjects were diagnosed with vulvovaginal atrophy (VVA) and belonged to a cohort of patients already scheduled for a routinary RP/RF treatment cycle.

All the study procedures were conducted in accordance with the World Medical Association's (WMA) Helsinki Declaration and its amendments. The informed consent was obtained for all the subjects participating in the study before the start of the study.

Eligible participants were all the menopausal women (age between 45 and 65 years old) affected by vaginal dryness associated or not with atrophy. Exclusion criteria were the use of steroids, diabetes, previous surgical interventions, neurologic or oncologic pathologies and allergy to hyaluronic acid.

Volunteers were randomly divided in two groups, as follows:

- G1: fifteen (n = 15) women received the RF/RP treatment and one capsule/day for eight weeks of the test food supplement; and
- G2: fifteen (n = 15) women received only the RF/RP treatment.

All the enrolled subjects attended a gynecological visit at the recruitment (T0), at the end of the RF and RP cycle (T5), at the end of dietary supplement intake (T8) and after two months of follow-up (T16). Treatment efficacy evaluation in terms of vaginal functional wellbeing and persistence of vaginal atrophy symptoms was assessed by the clinician at each visit.

### Intervention

The test product was a food supplement (Silky Bloom, Dermaser Srl, Milano, Italy) containing SH (ExceptionHYAL<sup>®</sup> Blossom, ROELMI HPC, Origgio, VA, Italy) obtained with a full spectrum finely modulated biofermentation technology. Each capsule of the test product contained 200 mg sodium hyaluronate, 2.4 mg Niacin and 7.5 µg Biotin. The posology was 1 capsule/day for eight weeks.

The RF/RP protocol was carried out as follows: topical application of a hyaluronic acid-based cream and RF/RP

intravaginal treatment for 15 minutes followed by a RF/RP vulvar treatment for additional 10 minutes. Subjects received the RF/RP treatment once a week for 5 weeks.

### Endpoints and Outcomes

The primary efficacy endpoint was the evaluation of vaginal functional wellbeing by Vaginal Health Index (VHI) questionnaire [31]. Subjects scored from 1 to 5 vaginal elasticity, vaginal secretions, pH, epithelial integrity, and vaginal hydration. Therefore, the final score for each subject ranges between 5 and 25, with a cut-off <15, as index of atrophic vagina. The secondary efficacy endpoint was the evaluation of the improvement of the vaginal atrophy symptoms by a 11-points visual analogue scale (Table 1).

No.	Symptoms	Mild symptoms				Moderate symptoms			Severe symptoms			
		0	1	2	3	4	5	6	7	8	9	10
01	Vaginal dryness	<input type="checkbox"/>	<input type="checkbox"/>	<input type="checkbox"/>	<input type="checkbox"/>	<input type="checkbox"/>	<input type="checkbox"/>	<input type="checkbox"/>	<input type="checkbox"/>	<input type="checkbox"/>	<input type="checkbox"/>	<input type="checkbox"/>
02	Vulvovaginal burning	<input type="checkbox"/>	<input type="checkbox"/>	<input type="checkbox"/>	<input type="checkbox"/>	<input type="checkbox"/>	<input type="checkbox"/>	<input type="checkbox"/>	<input type="checkbox"/>	<input type="checkbox"/>	<input type="checkbox"/>	<input type="checkbox"/>
03	Dyspareunia	<input type="checkbox"/>	<input type="checkbox"/>	<input type="checkbox"/>	<input type="checkbox"/>	<input type="checkbox"/>	<input type="checkbox"/>	<input type="checkbox"/>	<input type="checkbox"/>	<input type="checkbox"/>	<input type="checkbox"/>	<input type="checkbox"/>
04	Itching	<input type="checkbox"/>	<input type="checkbox"/>	<input type="checkbox"/>	<input type="checkbox"/>	<input type="checkbox"/>	<input type="checkbox"/>	<input type="checkbox"/>	<input type="checkbox"/>	<input type="checkbox"/>	<input type="checkbox"/>	<input type="checkbox"/>
05	Heat	<input type="checkbox"/>	<input type="checkbox"/>	<input type="checkbox"/>	<input type="checkbox"/>	<input type="checkbox"/>	<input type="checkbox"/>	<input type="checkbox"/>	<input type="checkbox"/>	<input type="checkbox"/>	<input type="checkbox"/>	<input type="checkbox"/>
06	Vulval pain	<input type="checkbox"/>	<input type="checkbox"/>	<input type="checkbox"/>	<input type="checkbox"/>	<input type="checkbox"/>	<input type="checkbox"/>	<input type="checkbox"/>	<input type="checkbox"/>	<input type="checkbox"/>	<input type="checkbox"/>	<input type="checkbox"/>
07	Incontinence	<input type="checkbox"/>	<input type="checkbox"/>	<input type="checkbox"/>	<input type="checkbox"/>	<input type="checkbox"/>	<input type="checkbox"/>	<input type="checkbox"/>	<input type="checkbox"/>	<input type="checkbox"/>	<input type="checkbox"/>	<input type="checkbox"/>

**Table 1:** Visual Analogue Scale.

### Statistical Analysis

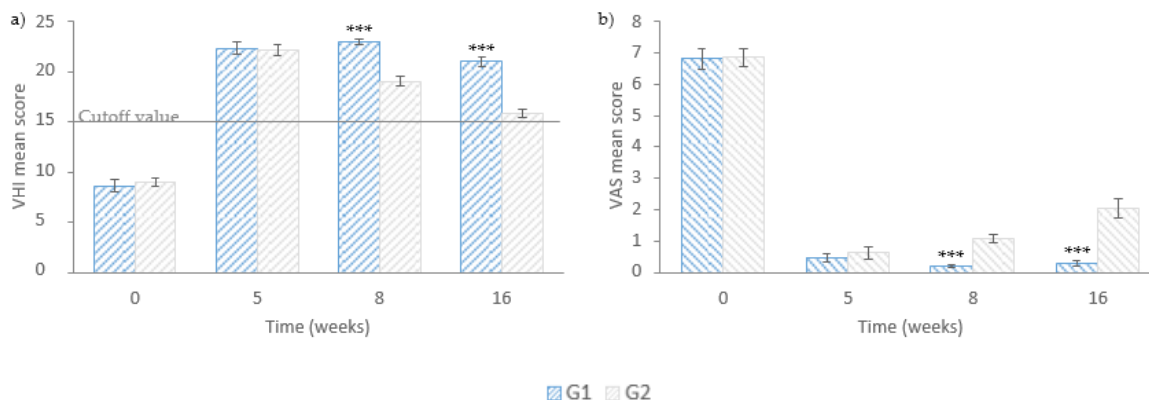
The statistical analysis was carried out using NCSS 10 (version 10.0.7 for Windows; NCSS, Kaysville, UT, USA) running on Windows Server 2008 R2 Standard SP1 64-bit edition (Microsoft, WA, USA). Before carrying out any statistical analysis the normal distribution of each dataset was checked by Shapiro–Wilk W test. Intergroup (group G1 vs. group G2) statistical analysis was carried by Mann-Whitney U test. A  $p < 0.05$  was considered statistically significant. The level of significance was reported as follows: \*  $p < 0.05$ , \*\*  $p < 0.01$ , and \*\*\*  $p < 0.001$ .

### Results

All women involved in the study well tolerated the routine treatment as well as the food supplement; moreover, no adverse effects and no dropouts were reported throughout the study.

No significant difference between the two groups was recorded at the beginning of the study in terms of mean VHI and VAS scores, confirming the homogeneity of the panel (Figure 1).

The initial mean VHI scores resulted  $< 15$  in both groups (Figure 1a), indicating all women showed a similar condition in terms of vaginal discomforts. A clinically relevant mean VHI improvement was recorded in both groups at the end of RF and RP treatment (T5) with no significant intergroup difference. VHI measured at the end of the food supplement intake (T8) confirmed that both groups achieved a relevant improvement in the global scores. However, with respect to the previous check-time, the active group showed a further VHI increment, whereas a slight decrement of the score was recorded in control group. Overall, such differences resulted in a significant intergroup difference ( $p < 0.001$ ). Mean VHI scores decreased in both groups at T16, however the mean VHI score of G1 resulted  $21.0 \pm 0.5$ , well above the cut-off level, whereas mean VHI score of G2 resulted  $15.8 \pm 0.4$ , i.e., very close to the cut off level of vaginal atrophy. A significant intergroup difference ( $p < 0.001$ ) was reported (Figure 1a).



**Figure 1.** a) Mean VHI questionnaire scores. b) Visual analogue scale cumulative average score. \*\*\* $p < 0.001$ . Data are mean  $\pm$  SEM.

Mean VAS scores of the individual parameter (Table 2) indicate that, at baseline, vaginal dryness, vulvovaginal burning, dyspareunia, and vulvar pain resulted high in both groups; also itching and heat were quite common among subjects, while incontinence received lower scores. After the RF and RP treatment (T5), all mean VAS values showed a relevant reduction in both groups (Figure 1b), however such differences did not result significant between groups.

Parameter	Treatment	T0	T5	T8	T16
Vaginal dryness	G1	8.1 $\pm$ 0.5	1.0 $\pm$ 0.3	0.5 $\pm$ 0.1***	0.8 $\pm$ 0.1***
	G2	9.1 $\pm$ 0.2	1.1 $\pm$ 0.4	2.1 $\pm$ 0.4	4.1 $\pm$ 0.5
Vulvovaginal burning	G1	7.9 $\pm$ 0.5	0.7 $\pm$ 0.2	0.4 $\pm$ 0.1***	0.5 $\pm$ 0.1***
	G2	8.1 $\pm$ 0.3	0.9 $\pm$ 0.4	1.8 $\pm$ 0.2	3.2 $\pm$ 0.4
Dyspareunia	G1	7.5 $\pm$ 0.6	0.6 $\pm$ 0.2	0.3 $\pm$ 0.1***	0.4 $\pm$ 0.1**
	G2	8.4 $\pm$ 0.3	1.4 $\pm$ 0.5	1.7 $\pm$ 0.3	2.3 $\pm$ 0.5
Itching	G1	6.9 $\pm$ 0.4	0.3 $\pm$ 0.2	0.1 $\pm$ 0.1	0.2 $\pm$ 0.2**
	G2	6.6 $\pm$ 0.4	0.1 $\pm$ 0.1	0.5 $\pm$ 0.2	1.7 $\pm$ 0.4
Heat	G1	6.4 $\pm$ 0.4	0.1 $\pm$ 0.1	0.0 $\pm$ 0.0*	0.0 $\pm$ 0.1**
	G2	5.6 $\pm$ 0.4	0.0 $\pm$ 0.0	0.3 $\pm$ 0.1	0.9 $\pm$ 0.3
Vulvar pain	G1	7.2 $\pm$ 0.5	0.3 $\pm$ 0.1	0.0 $\pm$ 0.0**	0.1 $\pm$ 0.2***
	G2	5.5 $\pm$ 0.4	0.4 $\pm$ 0.2	0.7 $\pm$ 0.2	1.7 $\pm$ 0.4
Incontinence	G1	3.8 $\pm$ 0.8	0.3 $\pm$ 0.2	0.0 $\pm$ 0.0*	0.0 $\pm$ 0.1*
	G2	4.6 $\pm$ 1.0.1	0.5 $\pm$ 0.2	0.5 $\pm$ 0.2	0.5 $\pm$ 0.2

**Table 2:** Mean VAS score for each single parameter for the two groups Intergroup statistical analysis. \*  $p < 0.05$ , \*\*  $p < 0.01$  \*\*\*  $p < 0.001$ . Data are mean  $\pm$  SEM.

The intake of the food supplement contributed to a further VAS reduction at T8 whereas women from G2 reported symptoms recurrence, mostly for vaginal dryness, vulvovaginal burning, and dyspareunia; significant intergroup differences were calculated for all parameters but itching. Indeed, vaginal dryness, vulvovaginal burning and dyspareunia improved with a  $p < 0.001$ , vulvar pain with  $p < 0.01$  and heat and incontinence with  $p < 0.05$ . Lastly, mean VAS scores increased again at T16; however, the intergroup

differences resulted significant for all parameters, as women who took the food supplement experienced an improved condition of vaginal dryness, vulvovaginal burning, and vulvar pain with  $p < 0.001$ , while dyspareunia, itching and heat got better with  $p < 0.01$  and incontinence with  $p < 0.05$ .

## Discussion

During menopause the change in estrogen production often lead to conditions such as GSM and VVA, which represents a serious discomfort for women, during their daily life.

The present study was carried out to highlight the efficacy of the oral intake of a full spectrum sodium hyaluronate food supplement in improving vaginal atrophy. The specific HA in the food supplement was obtained with the ExceptionHYAL® technology representing an innovative treatment for this discomfort. Regarding safety, such product is registered, and it is present on the market; additionally, no adverse effects were reported among women in the treated group at the end of the study.

According to the present study design, no placebo group was included since the applied gold standard therapy consisted in radioporation and radiofrequency treatments combined with the use of topical hyaluronic acid-based cream. The added value of the study was related to the intake of the food supplement; therefore, taking a placebo would not have affected the participants' response to the treatment. Moreover, once the food supplement intake was over, its effect in terms of vaginal functional wellbeing and persistence of vaginal atrophy symptoms was assessed during a period of follow-up reaching up to a total of two months.

*In vitro* and *in vivo* studies have demonstrated the synergistic activity of hyaluronic acid with different molecular weights which, by mimicking the body's physiological conditions, enables a more complex modulation of physiological processes if compared to the performances of a single molecular weight HA [30]. Some studies have shown that oral administration of Full Spectrum technology sodium hyaluronate could significantly contribute to an increase in hydration of tissues, in particular in the skin, thus leading to the improvement of moisturization, elasticity and firmness and consequently reducing the major signs of skin aging [31, 32].

Therefore, oral HA supplementation was evaluated in the present study as an adjunct to radioporation and radiofrequency therapy routinely performed on menopausal women at the clinic. Results achieved showed that the HA-based food supplement could represents an adjuvant to its topical application which was also enhanced by the radiofrequency and by the subsequent radioporation. In fact, the routine therapy adopted in the clinic was effective in achieving an improvement in the VVA symptoms up to 11 weeks after its conclusion; besides, a milder perception of the persistence of vaginal atrophy symptoms was recorded in the

control group, not taking the food supplement. However, VHI and VAS scores showed a greater and more lasting improvement in the active group.

The positive outcomes obtained in the present study may be attributed to the direct interaction of orally taken SH with the target tissues in which it is required; additionally, this specific sodium hyaluronate can stimulate the endogenous production of hyaluronic acid in vaginal cells restoring the vaginal turgor and giving a relief from atrophy symptomatology.

Results obtained in the present study support the potential efficacy of oral sodium hyaluronate in improving the atrophic symptomatology. However, its main limitations are due to the short follow-up period which does not allow to have a great overview of the patients' condition after a longer period and to the small sample size considered. Therefore, further studies are needed to definitively demonstrate oral sodium hyaluronate supplementation as one of the main strategies to improve vaginal atrophy as well as, by using different full spectrum hyaluronans, to verify whether specific SH molecules could have a precise and specific target.

## References

1. McNeil MA, Merriam SB (2021) Menopause. *Ann Intern Med* 174: ITC97-ITC112.
2. Nappi RE, Martini E, Cucinella L, Martella S, Tiranini L, et al. (2019) Addressing Vulvovaginal Atrophy (VVA)/Genitourinary Syndrome of Menopause (GSM) for Healthy Aging in Women. *Front Endocrinol (Lausanne)* 10: 561.
3. North American Menopause Society (2007) The Role of Local Vaginal Estrogen for Treatment of Vaginal Atrophy in Postmenopausal Women: 2007 Position Statement of The North American Menopause Society. *Menopause* 14: 355-69 quiz 370-1.
4. Mac Bride MB, Rhodes DJ, Shuster LT (2010) Vulvovaginal Atrophy. *Mayo Clin Proc* 85: 87-94.
5. Pastore LM, Carter RA, Hulka BS, Wells E (2004) Self-Reported Urogenital Symptoms in Postmenopausal Women: Women's Health Initiative. *Maturitas* 49: 292-303.
6. Portman DJ, Gass MLS (2014) Genitourinary syndrome of menopause: new terminology for vulvovaginal atrophy from the International Society for the Study of Women's Sexual Health and the North American Menopause Society. *Menopause* 21:1063-1068.
7. The NAMS 2020 GSM Position Statement Editorial Panel (2020) The 2020 Genitourinary Syndrome of Menopause Position Statement of The North American Menopause Society. *Menopause* 27: 976-992.
8. Labrie F, Archer DF, Koltun W, Vachon A, Young D, et al (2018) Efficacy of intravaginal dehydroepiandrosterone (DHEA) on moderate to severe dyspareunia and vaginal dryness, symptoms of vulvovaginal atrophy, and of the genitourinary syndrome of menopause. *Menopause* 25: 1339-1353.
9. Archer DF, Goldstein SR, Simon JA, Waldbaum AS, Sussman SA, et al (2019) Efficacy and safety of ospemifene in postmenopausal women with moderate-to-severe vaginal dryness: a phase 3, randomized, double-blind, placebo-controlled, multicenter trial. *Menopause* 26: 611-621.



10. Naumova I, Castelo-Branco C (2018) Current Treatment Options for Postmenopausal Vaginal Atrophy. *Int J Womens Health* 10: 387–395.
11. Keshavarzi Z, Janghorban R, Alipour S, Tahmasebi S, Jokar A, et al. (2019) The Effect of Vitamin D and E Vaginal Suppositories on Tamoxifen-Induced Vaginal Atrophy in Women with Breast Cancer. *Support Care Cancer* 27:1325-1334.
12. Chatspiroios D, Schmidts-Winkler IM, König L, Masur C, Abels C, et al. (2019) Topical Treatment of Vaginal Dryness with a Non-Hormonal Cream in Women Undergoing Breast Cancer Treatment - An Open Prospective Multicenter Study. *PLoS One* 14: e0210967.
13. Donders GGG, Ruban K, Bellen G, Grinceviciene S (2019) Pharmacotherapy for the Treatment of Vaginal Atrophy. *Expert Opin Pharmacother* 20: 821-835.
14. Nappi RE, Kotek M, Breštánský A, Giordan N, Beriotto I, et al. (2022) Treatment of Vulvo-Vaginal Atrophy with Hyaluronate-Based Gel: A Randomized Controlled Study. *Minerva Obstet Gynecol* 74: 480-488.
15. Advani P, Brewster AM, Baum GP, Schover LR (2017) A Pilot Randomized Trial to Prevent Sexual Dysfunction in Postmenopausal Breast Cancer Survivors Starting Adjuvant Aromatase Inhibitor Therapy. *J Cancer Surviv* 11: 477-485.
16. Chen J, Geng L, Song X, Li H, Giordan N, et al. (2013) Evaluation of the Efficacy and Safety of Hyaluronic Acid Vaginal Gel to Ease Vaginal Dryness: A Multicenter, Randomized, Controlled, Open-Label, Parallel-Group, Clinical Trial. *J Sex Med* 10:1575-1584.
17. Nappi RE, Kotek M, Breštánský A, Giordan N, Tramentozzi E, et al. (2020) Effectiveness of hyaluronate-based pessaries in the treatment of vulvovaginal atrophy in postmenopausal women. *Climacteric* 23:519-524.
18. Gustavino C, Sala P, Cusini N, Gravina B, Ronzini C, et al. (2021) Efficacy and safety of prolonged-release hyaluronic acid derivative vaginal application in the postpartum period: a prospective randomised clinical trial. *Ann Med* 53:1589-1597.
19. Stute P, May TW, Masur C, Schmidts-Winkler IM (2015) Efficacy and Safety of Non-Hormonal Remedies for Vaginal Dryness: Open, Prospective, Randomized Trial. *Climacteric* 18: 582-589.
20. Maytin EV (2016) Hyaluronan: More than just a wrinkle filler. *Glycobiology* 26: 553-9.
21. Grimaldi EF, Restaino S, Inglese S, Foltran L, Sorz A, et al. (2012) Role of High Molecular Weight Hyaluronic Acid in Postmenopausal Vaginal Discomfort. *Minerva Ginecol* 64: 321-329.
22. Knight C, Logan V, Fenlon DA (2019) Systematic Review of Laser Therapy for Vulvovaginal Atrophy/Genitourinary Syndrome of Menopause in Breast Cancer Survivors. *Ecancermedalscience* 13: 988.
23. Sarmento ACA, Lírio JF, Medeiros KS, Marconi C, Costa APF, et al. (2021) Physical methods for the treatment of genitourinary syndrome of menopause: A systematic review. *Int J Gynaecol Obstet* 153: 200-219.
24. Leibaschoff G, Izasa PG, Cardona JL, Miklos JR, Moore RD, et al. (2016) Transcutaneous Temperature Controlled Radiofrequency (TTCRF) for the Treatment of Menopausal Vaginal/Genitourinary Symptoms. *Surg Technol Int* 29:149-159.
25. Tadir Y, Gaspar A, Lev-Sagie A, Alexiades M, Alinsod R, et al. (2017) Light and Energy Based Therapeutics for Genitourinary Syndrome of Menopause: Consensus and Controversies. *Lasers Surg Med* 49:137-159.
26. Vicente-Manzanares M, Sánchez-Madrid F (2000) Cell Polarization: A Comparative Cell Biology and Immunological View. *Dev Immunol* 7: 51-65.
27. Huttenlocher, A (2005) Cell Polarization Mechanisms during Directed Cell Migration. *Nat Cell Biol* 7: 336-337.
28. Tranchini R, Raichi M (2018) Ultra-Pulsed Radioporation Further Enhances the Efficacy of Dynamic Quadripolar RadioFrequency in Women with Post-Menopausal Vulvo-Vaginal Atrophy. *Clin Obstet Gynecol Reprod Med* 4.
29. Prestia V, Bertozzi E, Raichi M (2021) DQRF™ (Dynamic Quadripolar Radiofrequency) and UPR™ (Ultra-Pulsed Radioporation) 12-Month Synergy in Postmenopausal Vulvovaginal Atrophy. *Integr Gyn Obstet J* 4: 1-6.
30. Petr Snetkov, Kseniia Zakharova, Svetlana Morozkina, Roman Olekhovich, Mayya Uspenskaya, et al. (2019) Hyaluronic Acid: The Influence of Molecular Weight on Structural, Physical, Physico-Chemical, and Degradable Properties of Biopolymer. *Pharmanutrition and Functional Foods* 4:25-34.
31. Michelotti A, Cestone E, De Ponti I, Pisati M, Sparta E, et al. (2021) Oral Intake of a New Full-Spectrum Hyaluronan Improves Skin Profilometry and Ageing: A Randomized, Double-Blind, Placebo-Controlled Clinical Trial. *Eur J Dermatol* 31:798-805.
32. Carlomagno F, Roveda G, Michelotti A, Ruggeri F, Tursi F, et al. (2022) Anti-Skin-Aging Effect of a Treatment with a Cosmetic Product and a Food Supplement Based on a New Hyaluronan: A Randomized Clinical Study in Healthy Women. *Cosmetics* 9: 54.