



Case Report

Know Your Options - A Relatively New Implant Especially Suitable for the Thin Adolescent Patient with a Femoral Neck Fracture

Nikolaus Floimayr^{1,2*}, Jonas Mühlebach¹, Roberto Sossai², Kerstin Schneider²

¹Department of Orthopedic and Trauma Surgery, Luzerner Kantonsspital, Switzerland

²Department of Children's Orthopedics and Traumatology, Luzerner Kantonsspital, Switzerland

***Corresponding author:** Nikolaus Floimayr, Department of Orthopedic and Trauma Surgery, Luzerner Kantonsspital, Lucerne, Switzerland

Citation: Floimayr N, Mühlebach J, Sossai R, Schneider K (2022) Know Your Options - The FNS is a Relatively New Implant Especially Suitable for the Thin Adolescent Patient with a Femoral Neck Fracture. Ann Case Report. 7: 1074. DOI: 10.29011/2574-7754.101074

Received Date: 28 November 2022; **Accepted Date:** 02 December 2022; **Published Date:** 05 December 2022

Abstract

Due to the rareness of the event and the anatomical characteristics of the patients, the choice of the optimal implant for femoral neck fractures in the pediatric population is challenging. A 15-year-old male presented with a highly unstable displaced femoral neck fracture. To guarantee stable fixation and to prevent soft tissue damage and irritation, we chose the so-called femoral neck system (FNS). At 6-month follow-up, the patient presented with a healed fracture without signs of implant failure and had an excellent functional outcome. Based on this case report, we consider the FNS as an equal to superior implant for the treatment of displaced femoral neck fractures in adolescents. The handling of the implant is as simple for the surgeon as safe for the patient.

Keywords: Adolescent; Femoral neck fracture; Femoral neck system; Minimal invasive surgery

Introduction

Femoral neck fractures are rare events among the adolescent population and most likely result from high-energy trauma. Pediatric femoral neck fractures can be classified according to the Delbet classification (4 types) [1] or the AO classification system [2] (B type). The complete, displaced, trans-/basicervical fracture type is highly unstable, comes along with a remarkable risk of varus collapse and leg length discrepancy [3] and is known to have the uppermost incidence of avascular necrosis (AVN) of the femoral head. [4] While AVN is rather influenced by fracture

characteristics [5, 6], early accurate reduction, and stable fixation is mandatory to minimize the risk of the other complications. [6] The choice of the optimal implant in pediatric orthopedic surgery is dependent on the fracture morphology as well as the child's bony dimensions, and include Kirschner wires, pediatric hip locking plates, and cannulated screws (CS). [7] Although the latter is a well-established method for adolescents and adults, it shows inferior biomechanical stability in comparison to an angular stable implant, such as the dynamic hip screw (DHS) [8, 9], which is also frequently used for the treatment of this type of fracture in adults. Due to constitutional reasons, the DHS, however, might not be suitable for adolescents as it exhibits a prominent implant footprint that is prone to cause soft tissue irritation.

The patient and his parents were informed that data concerning the case would be submitted for publication and they provided consent regarding the same.

Case Report

AA 15-year-old tall, slim boy (BMI, 19 kg/m²) presented to our emergency department with immobilizing right hip pain after a bicycle accident. Imaging of the hip of the clinically externally rotated and shortened leg revealed a displaced transcervical femoral neck fracture with a vertical fracture line (approximately 70°), corresponding to a Delbet Type II or an AO31B2.1(r) fracture, which is characterized by high instability.

The patient was neurovascularly intact, had no other injuries, and an unremarkable past medical history. Owing to the height (1.7 m) and weight (55 kg) of the patient, we wanted to use an implant that provides angular stability instead of a screw or K-wire fixation, which is usually chosen for the pediatric patient population. However, because of the smaller anatomical dimensions of the proximal femur of an adolescent compared to an adult or geriatric patient, as well as the thin soft tissue envelope of our patient, we decided against the classical DHS. Instead, we chose the femoral neck system (FNS, DePuy Synthes), a minimally invasive implant, which is only available since a short time ago.

To preserve biology, a successful attempt of closed reduction was made. The patient was placed on a fracture table, and the fracture was reduced satisfactorily with slight traction and maximal internal rotation of the leg. A 3cm skin incision for the transvastus approach was made to place a one-hole side-plate. The corresponding bolt and plate were implanted in accordance with the manufacturer guidelines. Postoperatively, immediate

mobilization with partial weightbearing was allowed. The patient was discharged on day 3. Full weightbearing was achieved at 6 weeks. During routine follow-up at 6 weeks, 3 and 6 months, the fracture healed uneventfully, showing neither loss of reduction nor any early signs of avascular necrosis. Clinically, an excellent functional outcome could be achieved with free range of motion and no signs of leg length discrepancy. No soft tissue irritation was caused by the side-plate. The patient was happy and had even fully returned to his pre-injury sports level.

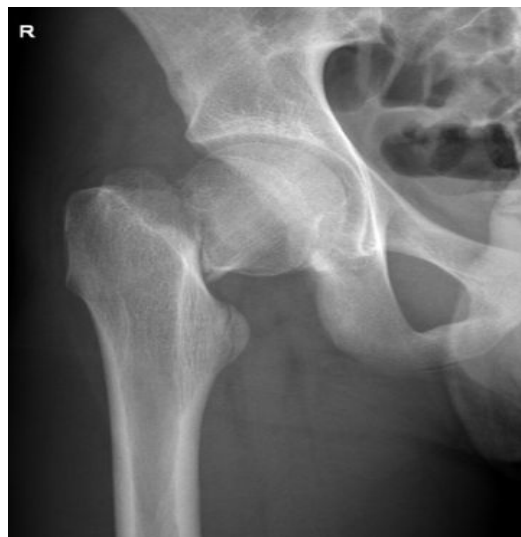

Figure 1: AP radiograph of the right hip showing a displaced transcervical femoral fracture with a vertical fracture line of about 70° (AO31B2.1 or Delbet II, respectively).

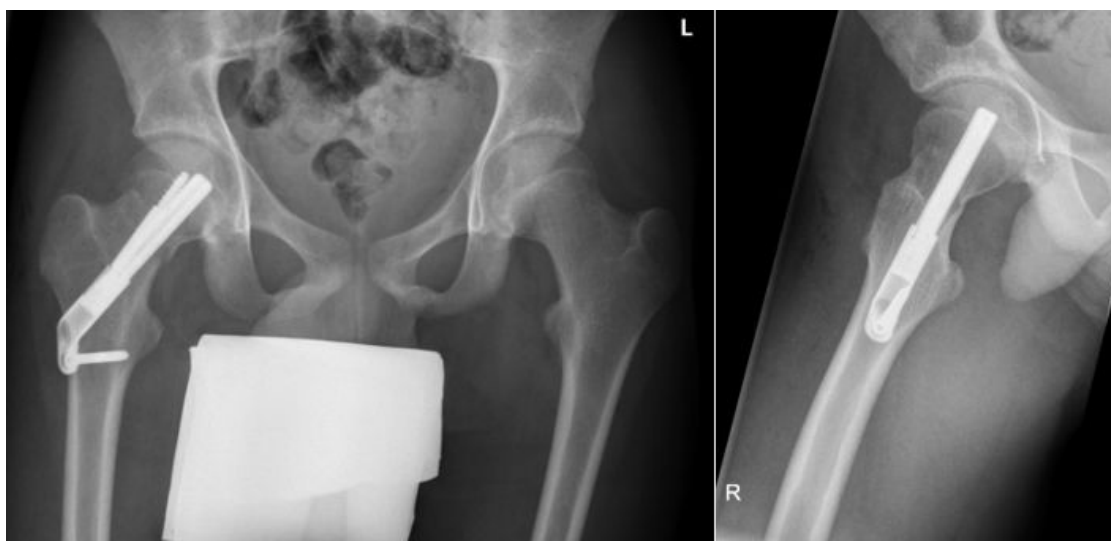


Figure 2: Postoperative radiographs in two planes showing adequate reduction and fixation with the FNS with a one-hole side-plate.

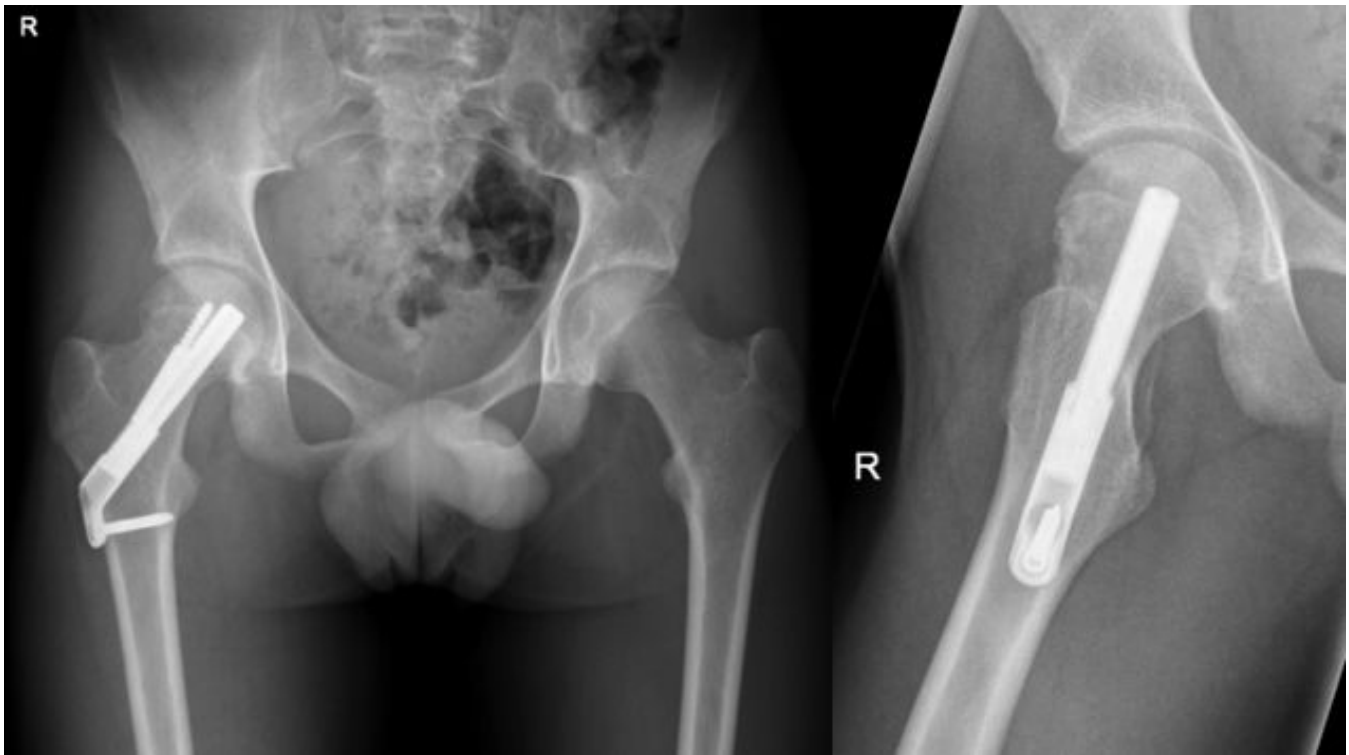


Figure 3: 6-month follow-up. Uneventful healing with no secondary displacement, marginal controlled collapse as allowed by the implant design (gliding mechanism) and no early signs of head necrosis.

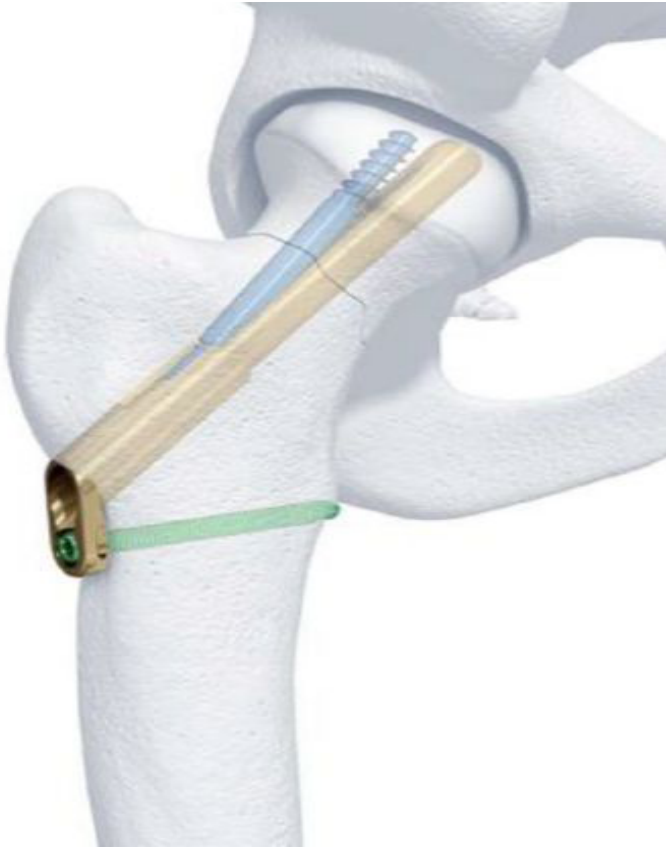

Figure 4: Schematic illustration of the FNS, consisting of a small side plate and a screw locked into a bolt providing angular stability and allowing free gliding within the baseplate and thus reducing lateral protrusion. © DePuy Synthes, Surgical Technique, Femoral Neck System (ENG/DE).

Discussion

Femoral neck fractures in skeletally immature teenagers are uncommon, and their treatment is challenging because of limited experience and data provided by literature. To avoid common complications such as mal-/nonunion, secondary displacement, and varus collapse, the goal of optimal treatment is an accurate, preferably anatomical reduction, stable fixation, and sustained biology [7]. Choosing an optimal fixation method is crucial for achieving these goals, which can be demanding for the adolescent patient. On the one hand, common pediatric implants are no longer suitable when certain anatomical dimensions are exceeded; on the other hand, adult implants tend to be oversized. CS have the advantage of providing some size variability and offer metaphyseal-only, physeal-sparing implantation, especially in basicervical fractures [7]. However, in case of extremely vertically oriented fractures, CS do not provide sufficient stability and could lead to

varus collapse [10]. DHS is widely used for the management of adult femoral neck fractures and simple pertrochanteric fractures and offers the advantage of angular stability. The biomechanical superiority of the DHS over the CS in unstable femoral neck fractures was reported by Deneka et al. [9] This was recently confirmed by a biomechanical study by Stoffel et al. for Pauwels type III fractures with regard to axial stiffness and neck shortening. [8] The FNS is a newly available implant, which also provides angular stability (like the DHS) promising to cause less soft tissue irritation in the same time, due to a much smaller side plate.

Stoffel et al. [8] also proved in their biomechanical study its stability to be comparable to that of the DHS and even superior to that of CS. In clinical studies, improved outcome in terms of healing time and complication rate such as neck shortening and screw cut out, as well as a better functional outcome could be shown. [11, 12] As the above-mentioned studies refer to the adult population, the use of the FNS in a skeletally immature patient is, to our knowledge, not reported in literature. We assume, that especially in this patient population, a rather small implant is beneficial, in order to avoid soft tissue irritation. In this regard, the FNS seems to offer an optimal solution. More benefits of this implant are rotational stability and that it enables intraoperative interfragmentary compression [8]. Nevertheless, the indication for its application in pediatric orthopedic surgery is dependent on the available implant dimensions. The length of the bolt can be a limiting factor for the treatment of younger children with a shorter femoral neck. Another disadvantage is the diameter of the bolt. In skeletally immature patients, although fracture stability is known to be more important than avoiding crossing the physis, [13] it is unknown whether transphyseal placement of the bolt leads to relevant growth arrest. Therefore, we recommend caution regarding physeal crossing until more clinical data prove its safety. Furthermore, no long-term results with the FNS are available currently, although the early outcomes are promising [14, 15].

Conclusion

Compared with previous implants, the FNS offers comparable to superior biomechanical stability and less soft tissue irritation. These benefits suggest that the FNS might be an optimal implant choice for unstable femoral neck fractures in adolescents.

Conflict of Interest

None of the authors or any immediate family member has received anything of value from or has stock or stock options held in a commercial company or institution related directly or indirectly to the subject of this article.

References

1. Colonna PC (1928) Fracture of the Neck of the Femur in Childhood: A Report of Six Cases. *Ann Surg*; 88: 902-907.
2. Meinberg EG, Agel J, Roberts CS, Karam MD, Kellam JF (2018) Fracture and Dislocation Classification Compendium-2018. *J Orthop Trauma*; 32: S1-S170.
3. Kay SP, Hall JE (1971) Fracture of the femoral neck in children and its complications. *Clin Orthop Relat Res*; 80: 53-71.
4. Moon ES, Mehlman CT (2006) Risk factors for avascular necrosis after femoral neck fractures in children: 25 Cincinnati cases and meta-analysis of 360 cases. *J Orthop Trauma*; 20: 323-329.
5. Spence D, DiMauro JP, Miller PE, Glotzbecker MP, Hedequist DJ, et al. (2016) Osteonecrosis After Femoral Neck Fractures in Children and Adolescents: Analysis of Risk Factors. *J Pediatr Orthop*; 36: 111-116.
6. Dai ZZ, Zhang ZQ, Ding J, Wu ZH, Yang X, et al. (2020) Analysis of risk factors for complications after femoral neck fracture in pediatric patients. *J Orthop Surg Res*; 15: 58.
7. Patterson JT, Tangtiphaibontana J, Pandya NK (2018) Management of Pediatric Femoral Neck Fracture. *J Am Acad Orthop Surg*; 26: 411-419.
8. Stoffel K, Zderic I, Gras F, Sommer C, Eberli U, et al. (2017) Biomechanical Evaluation of the Femoral Neck System in Unstable Pauwels III Femoral Neck Fractures: A Comparison with the Dynamic Hip Screw and Cannulated Screws. *J Orthop Trauma*; 31: 131-137.
9. Deneka DA, Simonian PT, Stankewich CJ, Eckert D, Chapman JR, Tencer AF (1997) Biomechanical comparison of internal fixation techniques for the treatment of unstable basicervical femoral neck fractures. *J Orthop Trauma*; 11: 337-343.
10. Eberl R, Singer G, Ferlic P, Weinberg AM, Hoellwarth ME (2010) Post-traumatic coxa vara in children following screw fixation of the femoral neck. *Acta Orthop*; 81: 442-445.
11. Hu H, Cheng J, Feng M, Gao Z, Wu J, Lu S (2021) Clinical outcome of femoral neck system versus cannulated compression screws for fixation of femoral neck fracture in younger patients. *J Orthop Surg Res*; 16: 370.
12. Zhou XQ, Li ZQ, Xu RJ, She YH, Zhang XX, et al. (2021) Comparison of Early Clinical Results for Femoral Neck System and Cannulated Screws in the Treatment of Unstable Femoral Neck Fractures. *Orthop Surg*; 13: 1802-1809.
13. Schneider K, Aufdenblatten C, Dreher T (2021) [Closed reduction and internal fixation of pediatric femoral neck fractures]. *Oper Orthop Traumatol*; 33: 4-14.
14. Stassen RC, Jeuken RM, Boonen B, Meesters B, de Loos ER, van Vugt R (2021) First clinical results of 1-year follow-up of the femoral neck system for internal fixation of femoral neck fractures. *Arch Orthop Trauma Surg*. 142: 3755-3763.
15. Cintean R, Pankratz C, Hofmann M, Gebhard F, Schutze K (2021) Early Results in Non-Displaced Femoral Neck Fractures Using the Femoral Neck System. *Geriatr Orthop Surg Rehabil*; 12: 21514593211050153.