



Research Article

“Mini-V lift” Facelifting

Bakhtiyor Najmiddinov¹, Taek-Kyun Kim^{2*}

¹Department of Plastic & Reconstructive Surgery, Seoul National University Bundang Hospital, Seoul National University College of Medicine, Seongnam, Republic of Korea

²THE PLUS Plastic Surgery, 9 Garosu-gil, Gangnam-gu, Seoul, Republic of Korea

*Corresponding author: Taek-Kyun Kim, THE PLUS Plastic Surgery, 9 Garosu-gil, Gangnam-gu, Seoul 06035, Republic of Korea

Citation: Najmiddinov B and Kim TK (2022) “Mini-V lift” Facelifting. J Surg 7: 1521. DOI: 10.29011/2575-9760.001521

Received Date: 22 June, 2022; Accepted Date: 24 June, 2022; Published Date: 28 June, 2022

Abstract

Background: “Mini”, “Minimal invasive” face-lift rejuvenation surgeries gained great popularity due to dramatic change on face with less invasive procedures nowadays. However, those methods focus on Caucasian patient group and still have some limitations as well. In this study, we aim to improve the pre-existing mini-facelift procedures, which plicate the Superficial Musculoaponeurotic System (SMAS) with our own technique called “Mini-V lift”.

Methods: A total of 44 patients including 43 Asians underwent Mini-V lift procedure between November 2019 and October 2020. The mean age of patients was 50.89 ranging from 29 to 78. Endoscopic forehead lift, thread lift, submental liposuction and/or fat graft were used as adjunctive procedures if indicated.

Results: The average follow-up period was 14 months. All patients were satisfied with the surgical results by questionnaire for evaluation of overall satisfaction rate including which part of face improved. Postoperative scar was rarely visible. No major complications were occurred during the follow-up period. Only 2 patients had minor hematoma, which were managed simply based on outpatient clinic.

Conclusion: This Mini-V lift technique is an effective short-scar facelift procedure more suitably designed for Asian patients by considering facial balance of Asian facial shape with less invasiveness.

Keywords: Facelift; Rejuvenation; Superficial musculoaponeurotic system

Introduction

Facial aging process involves the changes in both the bone and soft tissue compartments and it depends upon multiple factors. Wrinkles, folds, poor skin texture and sagging or imbalanced distribution of the soft tissue are the main signs of the facial aging, which may alter the self-perception by psychological, emotional and social effects [1-3]. A youthful face is featured with more positive feelings because of facial harmony, while facial aging may affect negative interpersonal relationships by changing the personal emotions to anger,

tiredness or sadness [1,2,4,5]. In recent, the desire of the most patients are getting increased toward a dramatic cosmetic improvement while having less invasive procedure with shorter downtime, less postoperative complication and less visible scar. To satisfy the needs of patient, the S-lift was proposed by Saylan in 1999, which involves a smaller excision of skin and a suspension of (SMAS) using purse-string sutures [6]. After then, Tonnard et.al. modified the S-lift procedure and named it as a “Minimal Access Cranial Suspension” (MACS-lift), which is one of the most commonly performed face-lift procedure today [7]. However, there are some limitations associated with less effect on lateral face and neck areas. Both procedures cause lateral

facial bulging due to the use of O-shaped purse-string suture, which is not adequate option to apply for Asian patients with round-shaped face since it makes more rounded facial shape. Moreover, it is not possible to improve the lateral neck area where Asian patients usually want to improve as a V-line by performing either procedure since both methods work with pure vertical vector. To improve the surgical outcome and overcome the limitations of pre-existing methods, we suggest another modified S-lift, named as “Mini-V lift” for Asian patients. The goal of our technique is to improve lateral neck area by applying the purse-string suture on the platysma, which makes prominent V-line and to prevent the lateral face bulging as well as minimizing the postoperative complications while having a dramatic improvement. In this study, we aim to present our experience with this “Mini-V lift” technique.

Methods

This study includes a total of 44 patients including 43 Asians (4 men and 40 women) who have undergone the modified S-lift rhytidectomy procedure, Mini-V lift between November 2019 and October 2020 at THE PLUS Plastic surgery clinic. Indications for the Mini-V lift include patients with the sagging of lower face, jowls, neck looseness, platysmal banding, skin laxity and who want dramatic cosmetic improvement with minimally invasive procedure and less complications.

Surgical Technique

Preoperative Marking

The marking is performed to outline the incision lines as well as the extent of skin undermining. An incision line is marked starting from the most cephalic point of the helical root, extending down to the caudal end of the earlobe and then going up to the retro-auricular area until the level of junction of cymba and cavum. Next, 3 guidelines for extent of skin dissection are drawn. The first line, which is a Pitanguy’s line from upper margin of the tragus to the 1.5cm above the lateral edge of the brow is drawn. This line indicates the temporal branch of the facial nerve. The second line is started from lower margin of the tragus and it connects with the corner of the mouth, while the third line connects the caudal end of the earlobe with the center of the chin. The points lying in 4 and 5cm distances from the center of the tragus were marked along the first and second lines, respectively, while 6cm is measured from the earlobe along the third line is marked.

A curved line connecting the marked three points is drawn and it shows the extent of the dissection anteromedially. And then another curved line connecting the third point and the end of marking for retroauricular incision is connected for posterolateral extent of the dissection, which makes an oval-shaped dissection boundary (Figure 1).

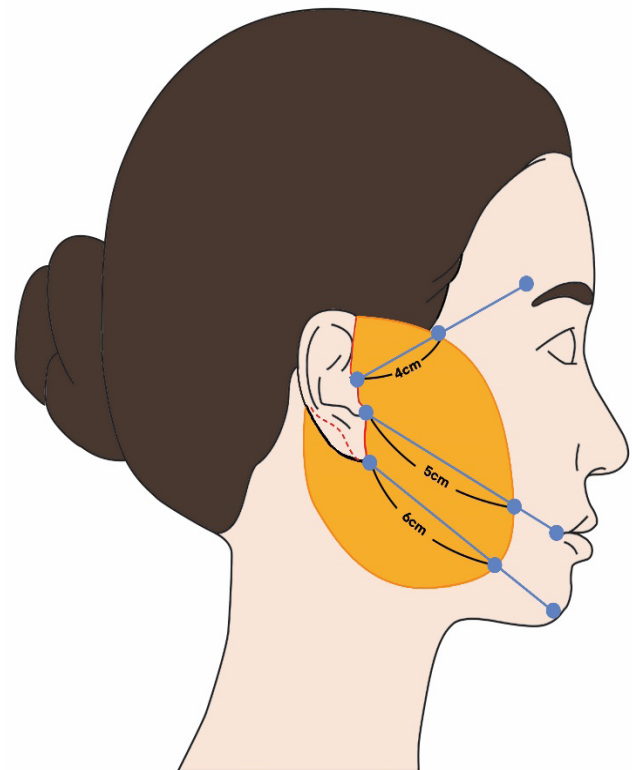


Figure 1: Preoperative marking, extent of incision and undermining are illustrated: Red-incision; Orange-undermining.

Anesthesia

The Mini-V lift is usually performed under the sedative and local anesthesia. After the patient is prepared and draped, 2mg of midazolam for retrograde amnesia, 0.2 mg of ketamine for pain control and 2 mg of propofol for hypnagogue were injected intravenously. Moreover, 4mg dexamethasone was given to reduce the postoperative swelling. Antibacterial prophylaxis was done with the injection of 1g cefazolin during the surgery. Once patient is sedated, a tumescent solution with 2% lidocaine, 1:1000 epinephrine and 8.4% sodium bicarbonate in normal saline was infiltrated bilaterally (30cc on each side of the face). Fifteen minutes was given to allow the tumescent for

adequate absorption.

Incision and Subcutaneous Undermining

The S-shaped ante-auricular with trans-tragal skin incision was performed anteriorly, extending from the caudal end of the earlobe to the cephalic border of the helical root using number 15 blade. The retro-auricular skin incision was done from just below the earlobe inferiorly to the level of the helical crus superiorly keeping the 2mm of skin wedge posterior to the retro-auricular fold for later suture placement. No pre-excision of the skin was performed. The oval-shaped skin undermining was performed using facelift scissors with a spreading fashion extending from the helical root, passing caudal border of the zygomatic arch cephalically, down to the mandibular angle and the marked line caudally and medially, respectively, between the SMAS and subcutaneous fat layers. Additional skin undermining was performed under the ear lobe and mastoid area up to helical crus level on the supra-platysmal plane (Figure 1).

Purse-String Sutures

Using the iris scissors, the zygomatic arch is exposed for the fixation 2cm anterior from the helical root. A caution is taken not to damage the periosteum as it is the fixation point. The first bite of the first purse-string suture is taken deep down to the outer periosteum of zygomatic arch. Once it is sure that periosteum is included, purse-string suture is continued downward to the level of the mandibular angle taking 1cm long bites on the SMAS. Once mandibular angle is reached, 1cm bite is taken horizontally toward medial side and next bites are taken upward in a same fashion including the periosteum of zygomatic arch as the last bite. While tying the first purse-string suture, assisting staff should push the soft tissue from mandibular angle toward zygomatic arch. The second loop also started at the same point and directed anteriorly in 45° from the first loop. The second loop is similar with the first one (U-shaped) rather than an oval shape to prevent bulging in the lateral face. After two loops, we check the looseness of SMAS using forceps whether it is

possible to lift more or not. If two loops are not enough, an additional loops medial to the second one are available. The final loop is made behind the ear starting from mastoid area holding the periosteum and proceeded anteriorly downward and then going back to lift the platysma. (Figure 2)

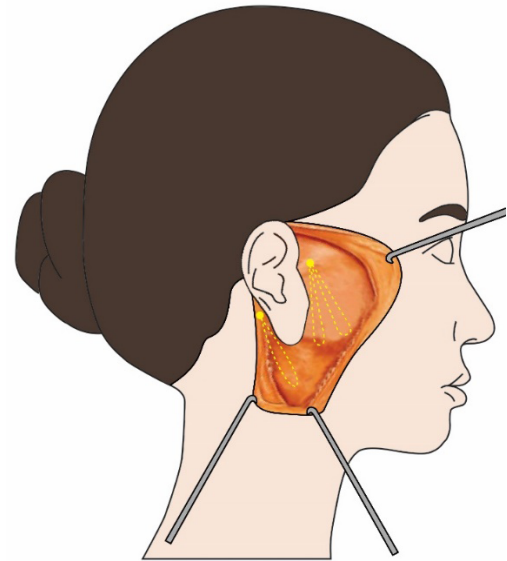


Figure 2: Illustration of purse-string sutures in Mini-V lift.

Skin redrape and closure

An electrocautery is used to smoothen the surface of the fatty layer in the lateral face after SMAS plication (Figure 3). After irrigation of the dissected area, JP drain is inserted. And then ear lobe is fixed at the SMAS base to prevent the pixie ear deformity using 4-0 vicryl and subcutaneous suture is done with same suture material. While subcutaneous closure is performed, a pre-auricular flap is rotated superolaterally and post-auricular flap is rotated superomedially in order to prevent the dog-ear formation. Moreover, if any irregularity is seen on the skin flap, we perform a tangential excision on the irregular surface of SMAS using facelift scissors. Subsequently, dermal closure using 5-0 vicryl and skin closure with 6-0 nylon are performed. An elastic facial band is applied as a compressive garment.

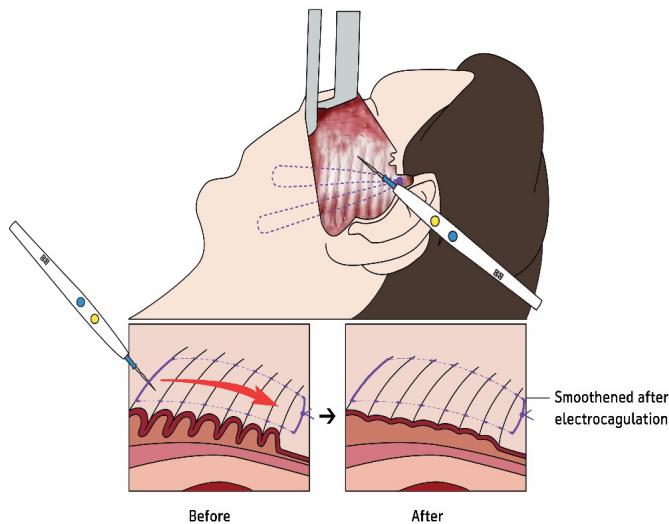


Figure 3: An electrocautery is used to smoothen the surface of the fatty layer and prevent the bulging in the lateral face after SMAS plication.

Post-operative care

After the surgery, pain killers, anti-inflammatory drugs and antibiotics are routinely given to the patient. Only soft diet is allowed during the day of surgery and then return to regular diet from next day. A regular follow-up is done on postoperative 1st, 3rd, 7th, 14th days, 1st, 3rd, 6th, and 12th month. The elastic facial band is worn for 24 hours during the first week and then worn while sleeping from second week until 1 month after the operation.

Adjunctive Procedures

If indicated, endoscopic forehead lift, thread lift, submental liposuction, and fat graft was performed simultaneously as adjunctive procedures to improve the surgical outcomes of Mini-V lift as well as facial harmony.

Endoscopic forehead lift for upper 1/3

If a patient comes with drooping brows or wrinkled forehead, the endoscopic forehead lifting is performed to minimize the extent of facelift procedure as well as to balance

the facial harmony. Then, if indicated, blepharoplasty can be added later.

Thread lift for middle 1/3

A thread lift using PDO thread ("V-xil", Bistool, Seoul, Korea) on the malar area is added for the patients with malar fat sagging as a less invasive procedure to improve the outcomes of Mini-V lift since Mini-V lift targets lower one third of the face (Figure 4).

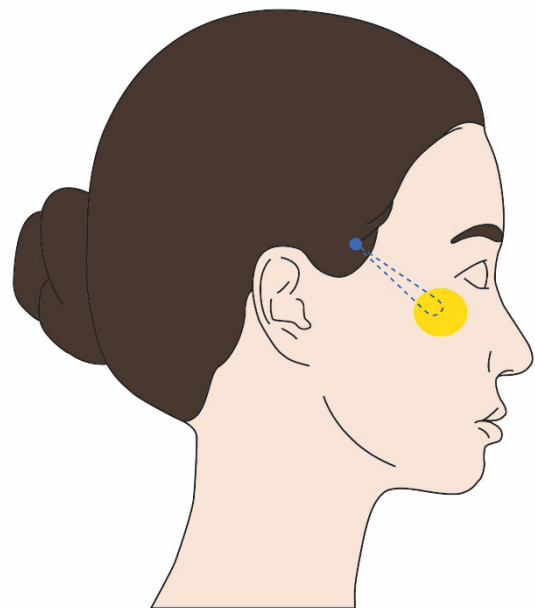


Figure 4: A thread lift using PDO thread on the malar area is added for the patients with malar fat sagging as a less invasive procedure to improve the outcomes of Mini-V lift.

Submental liposuction for lower 1/3

A submental liposuction is done after subcutaneous dissection of Mini-V lift. It will improve the cervicomental angle as well as the jawline. In addition, it facilitates easier movement of soft tissue with less resistance by creating subcutaneous tunnels (Figure 5). After the surgery, the area of the liposuction is taped to reduce the dead space with compression. The tape will be removed after one week.

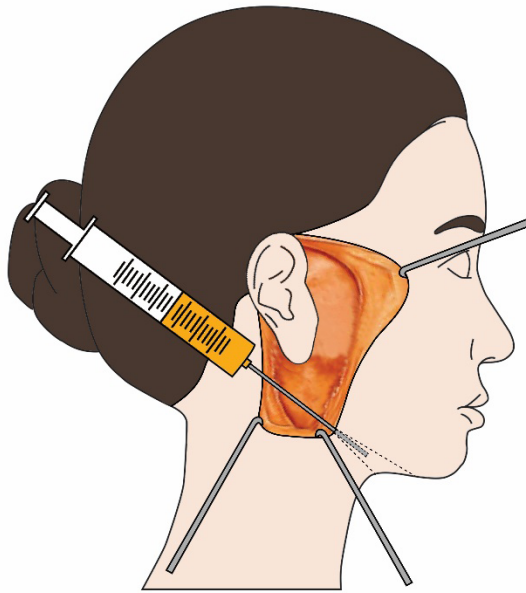


Figure 5: A submental liposuction is done using the same incision after subcutaneous dissection of Mini-V lift.

Fat graft for entire face

At the end of the surgery, fat graft is usually performed to refill the hollow areas with volume if indicated. The common area includes forehead, temple, anterior cheek, under the zygomatic arch, nasolabial fold, marionette line and chin.

Results

Among 44 patients including 43 Asians who underwent Mini-V lift procedure, four were men and 40 women. The mean age of the patients was 50.89 ranging from 29 to 78. The average operation time was about 2 hours when no adjunctive procedures were done. The average follow-up period was 14 months and all patients were satisfied with the final results at the end of their follow-up. No significant complications, such as delayed healing, nerve injury and facial irregularities were occurred, but there were 2 cases with a minor hematoma requiring the evacuation on the outpatient clinic. Lateral neck area was significantly improved in all patients and early relapses were not identified during our follow-up period. No dimpling on lateral face and ear deformities were happened. Figure 6 shows preoperative and postoperative views of the patient who underwent Mini-V lift and fat grafting in our clinic.

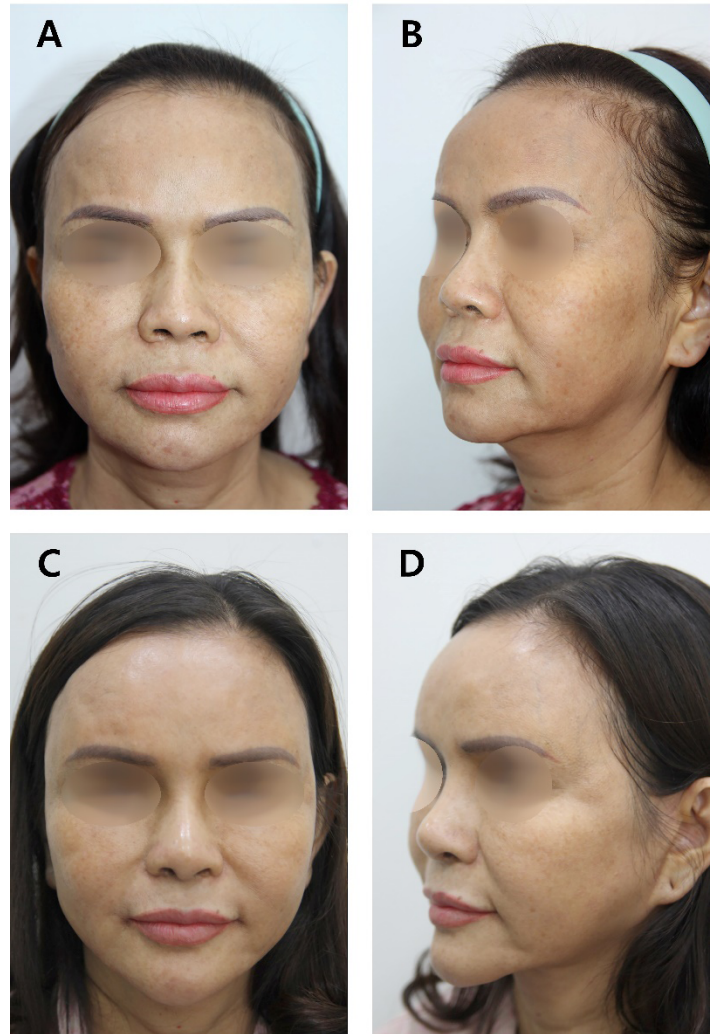

Figure 6: 52-year-old woman underwent Mini-V lift and an autologous fat grafting to the forehead, temple and nasolabial fold and chin augmentation using silicone implant (“Softxil”, Bistool, Seoul, Korea): **A**-preoperative frontal view; **B**-preoperative oblique view; **C**-frontal view 5 month after the operation; **D**-oblique view 5 months after the operation

Discussion

The earliest forms of the face lifting were performed by Miller and Passot by ellipsoidal skin excisions in natural skin creases in the early 1900s [8,9]. After Aufrecht introduced a SMAS plication technique using suture [10], a SMAS suspension was described by Pangman and Wallace [11], but both techniques were ignored for two decades [12]

until the crucial role of the SMAS in facelift surgery was appreciated. Skoog introduced the classic facelift technique in 1974, which is marked as a beginning of renaissance era in face lifting [13,14,15]. Then, different modifications of the facelift techniques were introduced including in both skin and SMAS techniques [16]. Although a significant improvement is achievable by the classic facelift procedures, potential risks and postoperative complications associated with an extensive surgery, cost-effectiveness, variability of the surgical skills among the surgeons and overcorrected or operated look after surgery lead the trend toward mini-facelift techniques.

After S-lift, in which purse-string sutures are used for SMAS plication was proposed by Saylan in 1999 [17], Tonnard et al. modified it and named as “MACS-lift” which stands for “minimal access cranial suspension” [18]. Although it is one of the most commonly performed mini-facelift procedures today, there are some limitations in both S-lift and MACS-lift including no effect on the lateral neck area. It was reported that some patients had a relapse in the neck deformity 2 years after MACS lift surgery [19]. Jacano and Parikh stated that the neck appearance is the main source of dissatisfaction among patients undergoing mini-facelift procedures [6-6]. Similarly, Tonnard et al. mentioned the necessity of secondary surgery following MACS-lift due to the poor neck contour [18,19]. Moreover, they may cause a widening of the face due the formation of bulging on the lateral face after using the O-shaped purse-string suture. That may cause unattractive look in patients with a round face, especially in Asian population. In our technique, we use only U-shaped purse-string sutures instead of O-shaped to prevent over-fullness on lateral face using 2 or 3 U-shaped loops. For the SMAS suspension, the periosteum of zygomatic arch was used as fixation point since it is more stable and secure anchoring point

compared to deep temporal fascia. In addition, anchoring to deep temporal fascia may cause postoperative pain in the temple area while chewing. Moreover, as long as we search, there was no reference commenting facelift procedure with the purse-string suture at retro-auricular area for prominent jaw line so far. The U-shaped loop of purse-string suture on platysma which is equivalent to SMAS at lateral neck area extends from mastoid down to mandibular angle inferiorly to enhance the lateral neck. Table 1 illustrates the differences of Mini-V lift from S-lift and MACS lift. Plastic surgeon should always consider the overall facial balance and harmony whatever procedure is being performed. Therefore, several adjunctive procedures were performed routinely if the facial condition of the patient is indicated or following the patient desires. If patient has a forehead wrinkle or brow ptosis, a forehead lifting was done to enhance youthfulness of the upper third of the face as an adjuvant procedure. In addition, a liposuction of the submental area was done to improve the cervicomental angle as well as it helps easier re-draping of soft tissue by lowering the resistance of SMAS during plication by creating subcutaneous tunneling. On the other hand, if a patient has drooping of soft tissue on the malar area, PDO threads was used to lift the malar fat pads since Mini-V lift does not cover the midface. This will help to avoid extension of the skin incision on the temple as well as undermining of malar area, which minimize the overall procedure, thus reducing the postoperative swelling as well as bruising. Finally, an autologous fat was grafted mainly into the forehead, temple, anterior cheek, lateral cheek, nasolabial fold and chin to enhance the skin texture, to reduce the aging lines and to fill the depressed areas by adding volume. No major complications were occurred and overall patients were highly satisfied after the operation. Any relapse was not occurred during the follow-up periods.

Difference of facelift techniques			
Type of facelift	S-Lift	MACS Lift	Mini-V Lift
Pre-excision of skin	Yes	No	No
Shape and extent of the incision	S-shaped skin incision, crossing the non-hair-bearing skin at the helical root	Inverted L-shaped skin incision following lower border of sideburn	S-shaped anteroauricular skin incision anteriorly, retroauricular incision extension posteriorly
Skin undermining	Oval-shaped, lateral face	Oval-shaped, lateral face	Oval-shaped skin under-mining on the lateral face connecting to retroauricular undermining on mastoid area
Purse-string sutures	Vertical U-shaped and oblique O-shaped purse-string sutures on SMAS	Vertical U-shaped and oblique O-shaped purse-string sutures on SMAS	Vertical U-shaped and oblique U-shaped purse-string sutures on SMAS anteriorly and U-shaped purse-string suture on platysma posteriorly
Anchoring point	Periosteum of the zygomatic arch	Deep temporal fascia	Periosteum of the zygomatic arch anteriorly and periosteum of mastoid posteriorly
The angle of lift	45°	Vertical	45°
Effecting areas	Anterior neck and jowls	Anterior neck and jowls	Anterolateral neck, jowls and jaw line

Table 1: The table compares the Mini-V lift with S-lift and MACS lift. (MACS lift: minimal access cranial suspension lift).

Mini-V lift technique is a safe and simple procedure, which can improve facial harmony significantly, especially when performed with other adjunctive procedures: forehead lift, submental liposuction, thread lift and fat graft with minimal postoperative complications. However, an additory study about this Mini-V lift involving longer follow-up period with more participants is mandatory to become the mainstay among the short scar rhytidectomy for Asians.

References

- Gupta MA, Gilcrest BA (2005) Psychosocial aspects of aging skin. *Dermatol Clin* 23: 643-648.
- Friedman O (2005) Changes associated with the aging face. *Facial Plast Surg Clin North Am* 13: 371-380.
- Reilly MJ, Tomsic JA, Fernandez SJ, Davison SP (2015) Effect of facial rejuvenation surgery on perceived attractive-ness, femininity, and personality. *JAMA Facial Plast Surg* 17: 202-207.
- Swift A, Liew A, Weinkle S, Garcia JK, Silberberg MB (2021) The Facial Aging Process From the “Inside Out” *Aesthetic Surgery Journal* 41: 1107-1119.
- Fitzgerald R (2013) Contemporary concepts in brow and eyelid aging. *Clin Plast Surg* 40: 21-42.
- Saylan Z (1999) The S-lift for facial rejuvenation. *Int J Cosmet Surg* 7: 18-23.
- Tonnard P, Verpaele A, Monstrey S, Landuyt KV, Blondeel P, et al. (2002) Minimal access cranial suspension lift: A modified S-lift. *Plast Reconstr Surg* 109: 2074-2086.
- Miller C (1907) *The Correction of Featural Imperfections*. Chicago: Oak Printing Company 1907.
- Passot R (1919) *La chirurgie esthetique des rides du visage*. Presse Med 27: 258-262.
- Aufricht G (1960) Surgery for excess skin of the face. In: *Transactions of the Second International Congress of Plastic and Reconstructive Surgery*. Edinburgh: E & S Livingstone 1960: 495-502.
- Pangman WJ II, Wallace RM (1961) Cosmetic surgery of the face and neck. *Plast Reconstr Surg Transplant Bull* 27: 544-550.
- Barton FE Jr (2008) *Facial Rejuvenation*. Boca Raton, Fla: Quality Medical Publishing/CRC Press 2008.
- Skoog T (1974) *Plastic Surgery: New Methods and Refinements*. Philadelphia: Saunders 1974.
- Mitz V, Peyronie M (1976) The superficial musculo-aponeurotic system (SMAS) in the parotid and cheek area. *Plast Reconstr Surg* 58: 80-88.

15. Stuzin JM, Baker TJ, Gordon HL (1992) The relationship of superficial and deep facial fascias: Relevance to rhytidectomy and aging. *Plast Reconstr Surg* 89: 441-449.
16. Wan D, Small KH, Barton FE (2015) Face Lift. *Recons. Surg* 136: 676e-689e.
17. Saylan Z (1999) The S-lift for facial rejuvenation. *Int J Cosmet Surg* 7: 18-23.
18. Tonnard P, Verpaele A, Monstrey S, Landuyt KV, Blondeel P, et al. (2002) Minimal access cranial suspension lift: A modified S-lift. *Plast Reconstr Surg* 109: 2074-2086.
19. Saleh DB, Brierley N, Riaz M (2021) R” face and neck lift: a modified technique for en-bloc facial rejuvenation. *Plast Aesthet Res* 2021: 8.