



## Anatomic Dissection of the Superficial Planes of the Hand on a Cadaver – Review of the Bifurcation Point of the Common Digital Arteries and Nerves

Miguel Matias\*, Luís Ribeiro, Luís Vieira

Department of Plastic Reconstructive and Aesthetic Surgery, Central Lisbon University Hospital Center, Lisbon, Portugal

\*Corresponding author: Miguel Matias, Department of Plastic Reconstructive and Aesthetic Surgery, Central Lisbon University Hospital Center, Lisbon, Portugal

Citation: Matias M, Ribeiro L, Vieira L (2021) Anatomic Dissection of the Superficial Planes of the Hand on a Cadaver – Review of the Bifurcation Point of the Common Digital Arteries and Nerves. J Surg 6: 1405. DOI: 10.29011/2575-9760.001405

Received Date: 21 June, 2021; Accepted Date: 02 July, 2021; Published Date: 05 July, 2021

### Abstract

Hand trauma is one of the leading causes of plastic emergency surgery on rural areas [1]. The knowledge of the precise course of vessels and nerves is of major clinical importance in order to evaluate the integrity of neurovascular structures in face of common injuries. In order to better understand the anatomy of the palmar superficial arch and the digital nerves we performed cadaver dissection with skeletisation of the referred structures in order to better understand their relations, especially the point where the common digital palmar artery and nerve bifurcate and their relative positions in space. In our single case analysis, the common digital artery was anterior to the nerve, until it bifurcated gaining a more posterior position thereafter. Also of clinical relevance is the fact that the nerve bifurcates more proximally (distal diaphysis of the metacarpal bone) than the artery (near the interdigital space).

### Introduction

The hand is supplied by a rich network of vessels and nerves. In terms of vascular anatomy, the hand is supplied by 2 main arterial pedicles – the radial and ulnar artery, which form the superficial and deep palmar arches of the hand. In most forms of hand trauma, either the arches or one of their terminal branches is injured along with the nerve [2,3]. It is of the utmost importance to understand the relation and the level of the bifurcation in order to be able to evaluate the integrity of the neurovascular bundles in face of trauma occurring at different levels.

The radial artery has its origin in the brachial artery, being the external branch, traversing the anterior aspect of the forearm in a descending and oblique course from the elbow crease to the radio-cubital-carpal articulation, where it gains the radial and posterior aspect of the hand until it reaches the first interosseous space, where it splits into its terminal branches [2,3]. Along its path the radial artery runs along the superficial aspect (posteriorly) of the short head of the biceps brachii, brachialis muscle, pronator teres muscle, and supinator muscle and the deep aspect (anteriorly) of the brachioradialis becoming just deep to the fascia when this muscle becomes tendinous. At the wrist level it is more radial and anterior to the flexor pollicis longus and pronator quadratus, until it crosses between the insertion of the flexor carpi radialis (medially) and brachioradialis (laterally) to reach the radial aspect of the wrist [2]. At this level the proper palmar digital artery forms and the radial artery gains the dorsal aspect of the hand where it continues

until the 1st interosseous space of the hand where it originates the carpalis dorsalis branch and the metacarpis dorsalis branch transversing under the abductor pollicis longus, extensor pollicis brevis and extensor pollicis longus. Passing the first interosseous space it finishes into the arcus palmaris profundus [3].

Important branches are the recurrent radialis, carpal palmar superficial artery, digitalis palmaris propria, princeps pollicis, carpalis dorsalis, metacarpalis dorsalis [2,3].

The ulnar artery has its origin in the brachial artery, being the internal and more voluminous branch, traversing the anterior aspect of the forearm in a descending and oblique course from the elbow crease to the upper third of the forearm, and then running a vertical line until the flexor retinaculum at the hand, completing the palmar and dorsal arches of the hand. Along its path, in the upper third of the forearm, the cubital artery runs along the superficial aspect of the short head of the biceps brachii and the flexor digitorum profundus and the deep aspect of the pronator teres, flexor carpi radialis and flexor digitorum superficialis [2]. At this level the median nerve crosses the ulnar artery, passing anteriorly from internal to external. In the last two thirds the ulnar artery keep its posterior relation with the flexor digitorum profundus and is anterior to the pronator quadratus and flexor digitorum profundus. At this level, the artery resides just posteriorly to the deep forearm aponeurosis. At this level, the artery leaves the deep aspect of the flexor digitorum superficialis and is covered by the flexor carpi ulnaris, until it becomes tendinous. After this point,

the artery is exposed until it reaches the Guyon channel, formed by the pisiform bone medially, the flexor retinaculum posteriorly and an expansion from the flexor carpi ulnaris and the fibers from the extensor retinaculum anteriorly. Along its course in the forearm, the cubital nerve is medial to the artery.

Importante branches are the recurrent ulnaris, the common interosseous artery (which divides in the anterior and posterior interosseous artery), carpalis dorsalis, and carpal palmar deep artery and an anastomotic branch between the deep and superficial palmar arches. At the Hand, the radial and ulnar artery form two arches: one deep and one superficial. The superficial arch is formed by the anastomosis of the ulnar artery and the superficial carpal palmar artery from the radial artery [2,3]. After leaving the Guyon channel, the ulnar artery crosses medially the hamulus of the hamate bone and progresses externally to anastomose normally at the intersection between the opposition and superior transversal flexion crease. The resulting arch is angulated, normally with a proximal concavity. Due to the ulnar artery bigger diameter it appears it continues with the 4<sup>th</sup> common palmar artery. This superficial arch is immediately deep to the palmar aponeurosis and anterior to the flexor tendons of the fingers, and the terminal branches of the ulnar and radial nerve. From the convexity of this arch several collateral branches form which go to the last four fingers of the hand. They are named from medial to lateral. The first common palmar digital artery crosses the hipotenar muscles until it reaches the 5<sup>th</sup> finger medial side, originating the medial palmar digital artery.

The second, third and fourth common palmar digital arteries cross between the flexor tendons of the fingers until the interdigital space where they split into two branches – the digital palmar arteries of the fingers. The 2<sup>nd</sup> originates the lateral of the fifth finger and medial of the forth; the 3<sup>rd</sup> originates the lateral of the forth finger and medial of the third; the 4<sup>th</sup> originates the lateral of the third finger and medial of the second finger. The first interosseous space is supplied by the princeps pollicis artery from the radial artery. Sometimes, the lateral digital palmar artery of the 2<sup>nd</sup> finger is also supplied by the superficial palmar arch originating from a 5<sup>th</sup> common palmar digital artery. The deep palmar arch is composed by the anastomosis of the radial artery and the deep palmar collateral of the ulnar artery. After passing the first interosseous space, the radial artery travels deep to the interosseous palmar muscle and the adductor pollicis, emerging from the adductor pollicis muscle at the level of the 3<sup>rd</sup> metacarpal bone. It is situated deep to the flexor tendons and the deep palmar

aponeurosis and is often crossed by the deep branch of the ulnar nerve. From the deep arch three types of collateral emerge: articular branches to the carpal bones and respective articulations; Perforating branches that end in the dorsal metacarpal arteries; Metacarpal palmar arteries, one for each interosseous space.

## Methods

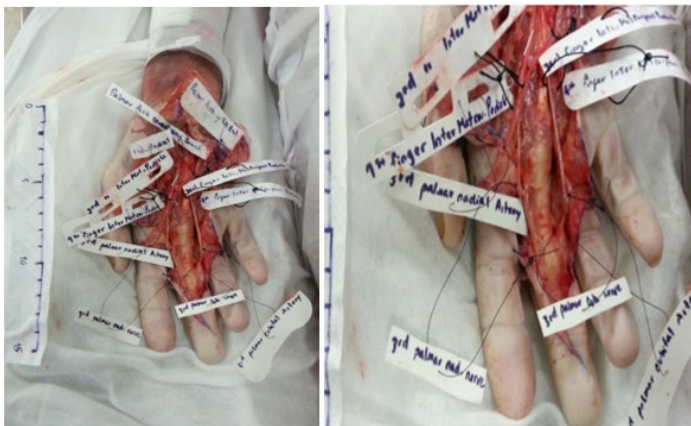To understand the relation of the superficial palmar branches with the nerves dissection of the hand was performed in an indigent cadaver. Two incisions were made initially – one along the upper transverse flexion crease and the other from the the pisiform bone until the previous line. Using a blade n°24 and a pair of Debakey forceps, Adsons forceps and Mützenbaum scissors we proceeded to the desepidermization of the skin, followed by the dissection of the palmar longus tendon and the continuing superficial palmar fascia. Careful identification and skeletisation of the vessels and nerves followed. We identified the structures encircling them with surgical thread. On a second stage we prolonged the incision along the third digit, with Brunner Z line, in order to better evaluate the relations of the neurovascular bundles at the finger level.

## Results and Discussion

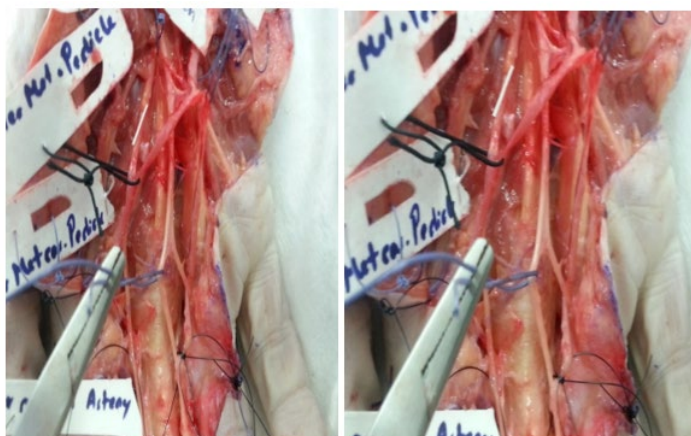
Classical anatomic description refers the palmar position of the common digital artery regarding the nerve and the more dorsal aspect of the radial and ulnar arteries when the neurovascular bundles of each individual finger are formed. Two important considerations resulted from this dissection session: First, the level of the bifurcation of the nerve is much before the bifurcation of the artery, which means that a lesion at the metacarpal distal diaphysis level two fingers may be compromised in terms of its vascular pedicles, but only one finger can show signs of nerve damage. In order to exclude neurovascular lesion at this level, one should look for two nerves and a single artery [4,5]. Any lesion at the webspace between fingers should confirm the presence of two arteries and two nerves before excluding neurovascular injury.

Second, the point of crossing from palmar to dorsal is near the finger webspace, much nearer to the artery bifurcation. At the level of nerve bifurcation, the common digital artery starts to gain the dorsal aspect of the nerves. Around the webspace the digital nerve crosses the palmar aspect of the artery, just before its bifurcation. This means that neurovascular assessment and repair attempts in Flexor Zone II, the so called No Mans Land, should take into consideration the shifting relation of the vessels and nerves (Figure 1 and 2).

## Anexes



**Figure 1:** Dissection of the palmar crease and volar aspect of the third finger.



**Figure 2:** Close up of the decussation point of the digital nerve.

## References

1. Maroukis, Brianna L (2016) Hand trauma care in the United States: a literature review. *Plastic and reconstructive surgery* 137: 100e.
2. Fazan, Valéria Paula Sassoli (2004) Superficial palmar arch: an arterial diameter study. *Journal of anatomy* 204: 307-311.
3. Karlsson, S., and I. A. Niechajev (1982) Arterial anatomy of the upper extremity. *Acta Radiologica. Diagnosis* 23: 115-121.
4. Meals, Roy A., and Martin Shaner (1983) Variations in digital sensory patterns: a study of the ulnar nerve—median nerve palmar communicating branch. *The Journal of hand surgery* 8: 411-414.
5. Engineer, Nitin J (2008) Variations in the anatomy of the third common digital nerve and landmarks to avoid injury to the third common digital nerve with carpal tunnel release. *Eplasty* 2008.