



## Case Report

# Resolution of Baker's Cyst with Knee Osteoarthritis by Bidirectional Therapy: Posterior Aspiration and Anterior Injection

Kyeong Mee Park<sup>1\*</sup>, Tae Hwan Cho<sup>1</sup>, Dong Phill Cho<sup>2</sup>

<sup>1</sup>Cho Orthopaedic & Oriental Clinic, Seoul, South Korea

<sup>2</sup>Fuzopuncture Institute, Seoul, South Korea

\***Corresponding author:** Kyeong Mee Park, Cho Orthopaedic & Oriental Clinic, Seoul 06979, South Korea

**Citation:** Park KM, Cho TH, Cho DP. (2021) Resolution of Baker's Cyst with Knee Osteoarthritis by Bidirectional Therapy: Posterior Aspiration and Anterior Injection. Ann Case Report 6: 667. DOI: 10.29011/2574-7754.100667

**Received Date:** 15 May, 2021; **Accepted Date:** 21 May, 2021; **Published Date:** 25 May, 2021

### Abstract

Baker's cyst, the popliteal cyst, is a swelling with synovial fluid located behind the knee joint. Popliteal cysts often cause pain and may need therapeutic interventions. A 68-year-old female with pain on the knee fossa and heavy discomfort on the calf visited our clinic. On physical examination, her left knee was swollen with a bulging mass in the popliteal region and showed a slight limitation in flexion movement compared to normal right knee. Ultrasonography showed anechoic images both in suprapatellar and posterior compartments of the left knee. Using an "in-plane needle technique" of ultrasonography, the cyst was punctured by a sterile syringe needle and cystic fluid was completely extracted. After shifting the position from prone to supine, she subsequently got a bolus of triamcinolone in the knee cavity. After the treatment, her uncomfortable symptoms disappeared and pain was decreased from VAS 7 to VAS 1. Up to 8 weeks from the treatment, her left knee did not show anechoic images in the suprapatellar and knee fossa compartments by ultrasonographic examination. The bidirectional therapy with posterior aspiration and anterior injection brought no recurrence during the 8 week-follow up period.

**Keywords:** Popliteal cyst; knee osteoarthritis; Ultrasonography; Aspiration; Injection; Steroid

anterior triamcinolone injection in popliteal cyst with knee OA patient.

### Introduction

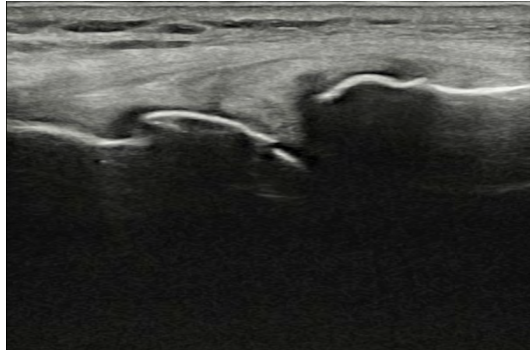
Baker's cyst, the popliteal cyst, is a synovial fluid-filled sac located between the tendons of gastrocnemius and semimembranosus muscles in the posteromedial region of knee fossa. Popliteal cyst arises as the result of accumulation and extrusion of synovial fluid, which is mostly implicated with inflammatory knee joint diseases [1]. It is proposed that chronic joint effusion in knee osteoarthritis (OA) triggers a continuous unidirectional flow of synovial fluid from the cavity to the popliteal cyst [2]. Popliteal cyst in knee OA patients can cause a sensation of tightness, discomfort, or pain behind the knee. Treatment of popliteal cyst is carried out only if it is symptomatic. If necessary, the cyst can be drained, injected with a steroid, or surgically removed to relieve the symptoms. Open surgical excision surgery or arthroscopic surgery from posterior popliteal fossa sometimes discourages the patients due to a considerable recurrence rate [3]. Scholars have insisted that popliteal cyst with knee OA patients is communicated with knee cavity and the cyst would disappear automatically when joint effusion is ceased [4]. Here, we report a result of bidirectional therapy with posterior cystic aspiration and

### Case

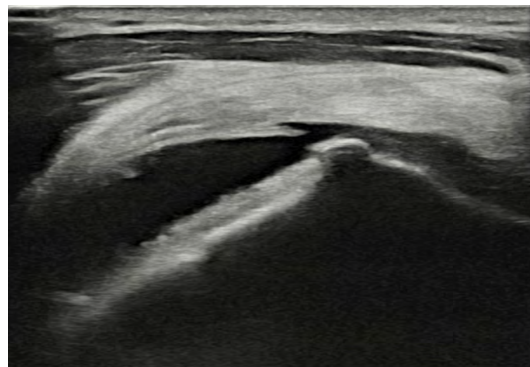
A 68-year-old female was admitted to Cho Orthopaedic & Oriental Clinic with swollen popliteus and hardness to bend the left knee for 6 days. Her symptoms started 2 weeks ago and worsened with time. She expressed her left calf became tight and swollen. On physical examination, the left knee was swollen with a bulging mass in the popliteal region. Passive dorsiflexion of the ankles was normal and dorsalis pedis pulses were palpable. The range of motion of the left knee was slightly limited compared to normal right knee. All ultrasound examinations were performed using a linear 3-16 MHz probe (HS40, Samsung Madison, Korea). With the patient in supine position and extended knees, definite osteophytes and narrowing of joint space were identified in her left femorotibial joint by ultrasonography (Figure 1A). A scoring system based on osteophytosis validated her as grade 2 of knee OA. Joint effusion was identified as compressible and anechoic distension of the joint space, which was measured in the suprapatellar recess (Figure 1B). With the patient lying in prone position and extended knees, the Baker's cyst was recognized as an anechoic cystic formation between the tendons of gastrocnemius

and semimembranosus muscles behind the left knee (Figure 2A). Under complete aseptic conditions, the cyst was punctured by an 18-G, 1.5-inch syringe needle using an “in-plane needle approach” of ultrasonography (Figure 2B). As the needle was introduced from posteromedial direction, the intraluminal content was completely extracted (Figure 2C). Once the cyst was thoroughly aspirated and decompressed, the puncture was covered by a sterile compression bandage.

complained of a feeling of tightness behind the left knee and heavy discomfort on the posterior side of the left calf. However, her uncomfortable symptoms disappeared after posterior aspiration from the cyst and anterior injection of triamcinolone into the knee cavity. The VAS pain score was decreased from 7 points before the treatment to 1 point after the treatment (Figure 3). Up to 8 weeks after the treatment, the left knee did not show anechoic images both in suprapatellar and knee fossa compartments by ultrasonography.

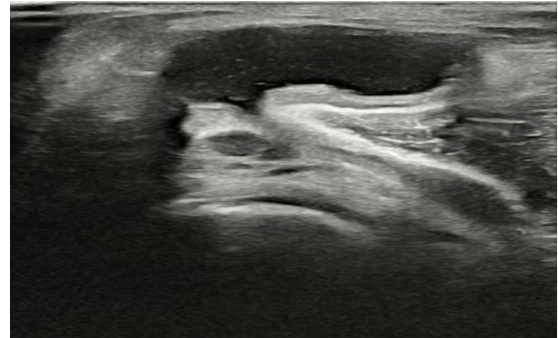


**Figure 1A:** Ultrasonography of osteophytes in femorotibial joint of the patient.

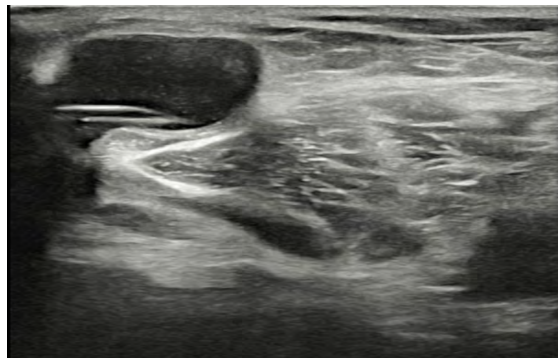


**Figure 1B:** Ultrasonography of knee joint effusion in suprapatellar recess.

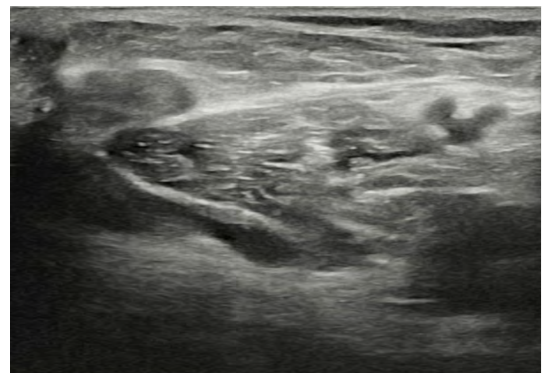The patient then shifted the position to supine and made her knees bended at an angle of 45 by a triangle support. The knee joint was determined by identifying and marking the dent between the articular surfaces of lateral condyles of femur and tibia. Then, a single intraarticular bolus of 40 mg triamcinolone (5 mL injection volume in saline) was given to the patient without extraction of knee effusion by a 23-gauge, 3.5-inch sterile syringe needle. She was taught to perform knee compression by elastic bandages for 2 days following the treatment. The patient was followed up after the treatment for 8 weeks. The VAS score and ultrasonographic evaluation were compared between posttreatment and pretreatment. Before the treatment, the patient had a limitation on flexion of the left knee joint and suffered pain behind the knee. She also



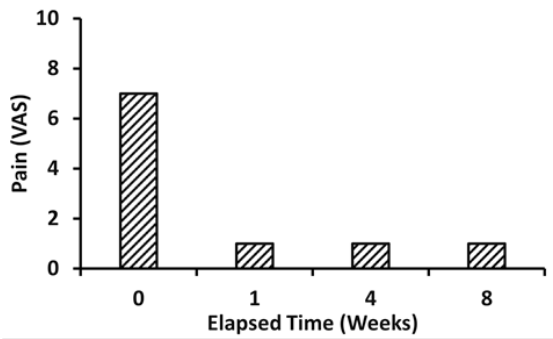
**Figure 2A:** Ultrasonography of Baker’s cyst of the patient.



**Figure 2B:** Ultrasonography of in plane-needle approach to Baker’s cyst.



**Figure 2C:** Ultrasonography of Baker’s cyst after the bidirectional intervention.



**Figure 3:** Effect of the bidirectional therapy on pain.

## Discussion

In adults, popliteal cysts usually occur concomitantly with knee OA which results in persistent and excess production of synovial fluid. Marti-Bonmati et al. [5] reported there was extremely significant association between knee joint effusion and popliteal cyst using MRI examination. The bursa space is communicated with knee cavity through one-way valvular mechanism covered by posteromedial capsular fold. Accumulated evidence manifested a posteromedial injection of steroid after cystic aspiration induced a rapid elimination of popliteal cyst associated with knee OA [6,7]. In a 56-year-old male with atraumatic left knee pain and swelling, Baker’s cyst aspiration with corticosteroid injection represented a safe alternative treatment option for patients [8].

However, there is a question of whether the in situ-injection of triamcinolone at the site of cystic extraction is recommended because of a substantial recurrency after the treatment. We premised if a bolus of triamcinolone poured into the anterior knee cavity, the synovial flow to the posterior popliteal cyst would be reduced, resulting in the extinction of the cyst. The result was just as we expected. The anterior injection of triamcinolone after the posterior cystic aspiration resulted in pain relief and disappearance of the cyst during the 8-week follow-up period. We evaluate the bidirectional intervention is a valid method to treat popliteal cyst

with knee OA. According to our undisclosed data, a bidirectional therapy consisting of posterior aspiration from the cyst and anterior injection to the knee cavity was more efficient and longer lasting than unidirectional one with posterior aspiration from the cyst and posterior injection to the cyst. Further, the posterior aspiration and anterior injection intervention is simpler and safer than open surgery or arthroscopic resection.

This case study is presented to share our experience on the bidirectional intervention to the popliteal cyst with knee OA. The bidirectional intervention is worth being considered one of the first choices which patients with Baker’s cyst consider a non-surgical and non-recurrent remedy.

## References

1. Sansone V, De Ponti A. (1999) Arthroscopic treatment of popliteal cyst and associated intra-articular knee disorders in adults. *Arthroscopy*. 15: 368-372.
2. Lindgren PG, Willen R. (1977) Gastrocnemio-semimembranosus bursa and its relation to the knee joint. I Anatomy and histology. *Acta Radiol Diagn (Stockh)*. 18: 497-512.
3. Newsham KR. (2009) Recurrent popliteal cyst in an adult: a case report and review. *Orthop Nurs*. 2009; 28: 11-14.
4. Rupp S, Seil R, Jochum P, Jochum P, Kohn D. (2002) Popliteal cysts in adults. Prevalence, associated intraarticular lesions, and results after arthroscopic treatment. *Am J Sports Med*. 30: 112-115.
5. Marti-Bonmati L, Molla E, Dosda R, Casillas C, Ferrer P. (2000) MR imaging of baker cysts prevalence and relation to internal derangements of the knee. *MAGMA*. 10: 205-210.
6. Mert K, Mehmet C, Hüseyin NE, Mustafa K, Meltem C, Mahmut Y, et al. (2012) Ultrasound guided percutaneous treatment and follow-up of Baker’s cyst in knee osteoarthritis. *Eur J Radiol*. 81: 3466-3471.
7. Bandinelli F, Fedi R, Generini S, Porta F, Candelieri A, et al. (2012) Longitudinal ultrasound and clinical follow-up of Baker’s cysts injection with steroids in knee osteoarthritis. *Clin Rheumatol*. 31: 727-731.
8. Fredericksen K, Kiel J. (2021) Bedside ultrasound-guided aspiration and corticosteroid injection of a baker’s cyst in a patient with osteoarthritis and recurrent knee pain. *J Am Coll Emerg Physicians Open*. 2: e12424.