



Dermatofibrosarcoma Protuberans (Dfsp) with Fibrosarcomatous Transformation: A Case Report

María Fernández Martínez¹, María Luz Fernández Vázquez¹, Maitane Orue-Echebarría¹, Lorena Martín Román¹, Wenceslao Vázquez Jiménez², Pablo Lozano Lominchar², Natividad Palencia García², Luis González Bayón^{2*}, Francisco Alijo Serrano³, Carmen Pinilla Martínez⁴, Luis González Bayón^{2*}.

¹Cirugía General, Hospital General Universitario Gregorio Marañón, Madrid, Spain

²Unidad de Patología Peritoneal y Retroperitoneal, CSUR Sarcomas de partes óseas y de partes blandas, Hospital General Universitario Gregorio Marañón, Madrid, Spain

³Servicio de Anatomía Patológica, Unidad de Sarcomas, Hospital General Universitario Gregorio Marañón, Madrid, Spain

⁴Servicio de Cirugía Plástica, Hospital General Universitario Gregorio Marañón, Madrid, Spain

***Corresponding author:** Luis González Bayón, Peritoneal and Retroperitoneal Unit, Hospital General Universitario Gregorio Marañón, Madrid, Spain

Citation: Martínez MF, Vázquez MLF, Orue-Echebarría M, Román LM, Jiménez WV, et al. (2021) Dermatofibrosarcoma Protuberans (Dfsp) with Fibrosarcomatous Transformation: A Case Report. Ann Case Report 6: 662. DOI: 10.29011/2574-7754.100662

Received Date: 27 April, 2021; **Accepted Date:** 10 May, 2021; **Published Date:** 14 May, 2021

Abstract

Case Report: We report a case of a 40 year-old woman, who consulted for an infraumbilical 5cm cutaneous node, the third recurrence of a fibrocystic lesion. An expert sarcoma pathologist analyzed the previous histopathological samples, and suspected a DFSP, finding a positive rearrangement for the PDGFB gene (derived growth factor beta polypeptide). Surgical removal with wide local excision was performed. The histopathological analysis showed a mesenchymal proliferation with storiform pattern according to a DFSP, and a fishbone pattern with fusiform cells corresponding to a fibrosarcoma in the deeper region.

Backgrounds: DFSP is a rare soft tissue tumor affecting young adults, and has been related to a chromosomal translocation t(17;22)(q22;q13), presented in 90% of the cases, that results in a fusion protein COL1A1-PDGFB (collagen type 1A1). It is usually presented as an indurated skin plaque, involving dermis and subcutaneous fat. It has a high risk of local recurrence (10-60%), being weird lymphatic dissemination and distant hematogenous metastasis (4-5%). Histologically it is characteristic fusiform cells with a storiform pattern (cellular swirls). The treatment is surgical removal with wide local excision. It has a 10-year overall survival of 99%. It has been described de fibrosarcomatous degeneration (7-16% of the cases), with more aggressive behavior, a higher local recurrence and distant metastasis rate.

Conclusion: A proper identification of this type of tumors may change the surgical procedure and disease prognosis, so they must be managed by expert pathologists and a Multidisciplinary Team on soft tissue sarcomas in order to achieve the best results.

Keywords: Dermatofibrosarcoma; Protuberans; Soft tissue; Fibrosarcoma

Introduction

Dermatofibrosarcoma protuberans (DFSP) is a rare soft tissue tumor originated from mesenchymal stem cells of reticular dermis. The incidence is around 0.8-4.5 cases/million/year. Young adults in the third to fifth decade are the most affected population,

with a slight female predominance, in whom accelerated growth has been described during pregnancy [1]. The pathogenesis is unknown. It has been related to a chromosomal translocation t(17;22)(q22;q13), present in 90% cases of DFSP, that results in a fusion protein COL1A1-PDGFB (collagen type 1A1 gene-platelet-derived growth factor beta polypeptide gene) which leads to an overproduction of PDGF and cellular proliferation [2,3]. DFSP usually is presented as an indurated skin plaque, with slow

growth. It involves dermis and subcutaneous fat, but rarely fascia and muscle. The most frequent location is trunk (50%), followed by extremities (35%). It presents a high risk of local recurrence (10-60%), but it is weird lymphatic dissemination and distant hematogenous metastasis (4-5%) (being lung the most frequent location) [4].

Histologically, it is characteristic a highly cellular diffuse dermal proliferation, with fusiform and hyperchromatic cells arranged in a storiform pattern (cellular swirls). Immunohistochemistry (IHC) is typically positive for CD34, vimentin, and negative for S-100. It has been described the fibrosarcomatous degeneration (7-16% of the cases), with more aggressive clinical behavior, and a higher local recurrence and distant metastasis rate. The higher rate of metastasis has been associated with factors such as the level of invasion (depth), ulceration, necrosis, affected borders and tumor differentiation degree [5,6]. The highest risk of local recurrence is in the first 3 years, so it requires a close clinical follow-up, and thoracic CT scan in case of aggressive variants [7,8].

The treatment of DFSP is surgical removal with wide local excision, although Mohs micrographic surgery (intraoperative histopathologic margin control) achieves a decisive role in regions where tissue preservation is a priority. Its prognosis is good, with a 10- year overall survival of 99% of patients [7,8]. Imatinib mesylate, a tyrosine kinase inhibitor, has been recently approved for recurrent, unresectable, or metastatic DFSP in patients with the PDGFB mutation previously described [8].

We present a case of a 40-year-old woman with no medical backgrounds (just 3 pregnancies and 3 vaginal deliveries), who consulted for the first time in 2008, in a peripheral hospital, for an infraumbilical cutaneous nodule, during first pregnancy. It was surgically removed and the histopathological exam showed a fibrocystic lesion. After that, she presented two recurrences (also while pregnancies) in 2014 and 2015, that were removed and with a histopathological exam of nodular fasciitis. In September 2018, a new indurated plaque appeared with a faster growth in the same location, and she was referred to our Sarcoma Unit.

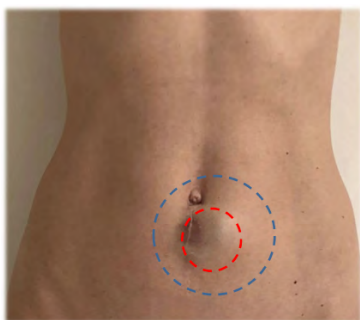


Figure 1: Red points: Macroscopic lesion. Blue points: surgical excision margin.

She presented a subcutaneous infraumbilical mass of 5x4cm in diameter (Figure 1), well- defined borders, fixed to the skin but not to deep layer. An expert sarcoma pathologist analyzed the previous histopathological samples. Because a DFSP was suspected on microscopy, histochemistry was performed, being positive for CD34, ML actin, vimentin and bcl2, and negative for F.XIIIa, S-100. Molecular cytogenetics study was also carried out by fluorescence in situ hybridization (FISH), showing a positive rearrangement for the PDGFB gene. Surgical removal with wide local excision was performed. An infraumbilical tumor of 5.2 x4 cm was found in dermis and subcutaneous cellular tissue, reaching the fascia without invading it. Block exeresis was performed, including skin, subcutaneous and fascia with margins of 3cm in all directions. Fragments from 4 cardinal points were analyzed intraoperative, reported tumor free. Anterior abdominal fascia was closed with a Marlex mesh and primary skin closure was possible.

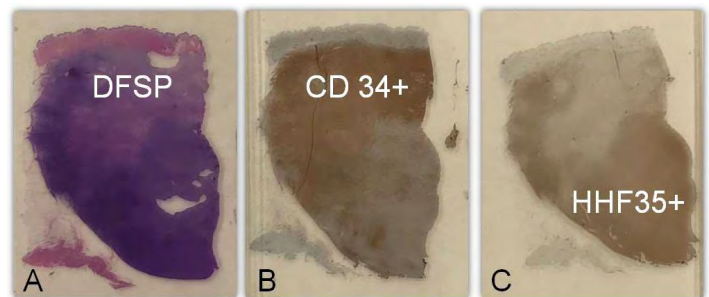


Figure 2: A. H-E (clear area: DFSP) B. DFSP CD34 + (clear area negative for CD34: fibrosarcoma. C. Fibrosarcoma HHF35+ (clear area: DFSP negativa).

The histological analysis showed a mesenchymal proliferation with a storiform pattern in the shallow region according to a DFSP, and a fishbone pattern with fusiform cells corresponding to a fibrosarcoma in the deeper region. IHC: CD34 +, actin HHF35 +, XIII factor + (Figure 2). The final diagnosis was a FIBROSARCOMA GRADE 2 of the FNCLCC pT2N0M0, with respected margins. The deep fascial margin was negative, although it was close to the tumor (2mm). As it was a surgical barrier (fascia), margin extension was not considered necessary. The Sarcomas Multidisciplinary Team recommended close follow-up with local exploration and thoracoabdominal-pelvic CT scan. No distant lesions were found. A proper identification of this type of tumor, with an early and precise diagnosis, is very important. It may change the surgical procedure and the disease prognosis. For all these reasons we strongly suggest that skin lesions with nonclear pathologic diagnosis or recurrent lesions) to be managed by expert pathologists and a Multidisciplinary Team on soft tissue sarcomas in order to achieve the best results.

Compliance with Ethical Standards Conflicts of Interest

No conflicts of interest to declare in this study.

Research Involving Human Participants and/or Animals

This is a descriptive case report study. No other researching involving humans or animals have been developed. Information related to participant will be kept confidential and managed in accordance with Data Protection Law.

Informed Consent

The informed consent to participate in this descriptive case report study was signed by the patient.

Acknowledgement

Acknowledgement to “Peritoneal and Retroperitoneal Unit”, Plastic Surgery and Histopathologists team from Hospital General Universitario Gregorio Marañón.

References

1. Brooks J, Ramsey ML. (2018) Cancer, Dermatofibrosarcoma Protuberans. In: StatPearls [Internet]. Treasure Island (FL): StatPearls Publishing.
2. Li Y, Wang C, Xiang B, Chen S, Li L, Ji Y. (2017) Clinical Features, Pathological Findings and Treatment of Recurrent Dermatofibrosarcoma Protuberans. *Journal of Cancer* 8: 1319-1323.
3. Thway K, Noujaim J, Jones RL. (2016) Dermatofibrosarcoma protuberans: pathology, genetics, and potential therapeutic strategies. *Ann Diagn Pathol.* 25: 64-71.
4. NCCN Guidelines Version 1.2019. Dermatofibrosarcoma protuberans
5. Kuzel P, Mahamood MN, Metelitsa AI, Salopek TG. (2015) A clinicopathologic review of a case series of dermatofibrosarcoma protuberans with fibrosarcomatous differentiation. *Journal of Cutaneous Medicine and Surgery* 19: 28-34.
6. Socoliuc C, Zurac S, Andrei R, Staniceanu F. (2015) Multiple histological subtypes of dermatofibrosarcoma protuberans occurring in the same tumor. *J Intern Med.* 53: 81-90.
7. Noujaim J, Thway K, Fisher C, Jones RL. (2015) Dermatofibrosarcoma protuberans: from translocation to targeted therapy. *Cancer Biol Med* 12: 375-384.
8. Ugurel S, Becker JC. (2017) Imatinib in Dermatofibrosarcoma: Targeted Therapy or Immunotherapy? *J Invest Dermatol.* 137: 277-279.