



Case Report

Severe Acute Pancreatitis Associated with SARS-CoV-2 Virus Infection: Case Report

Tadeo-Jiménez Y¹, Cházaro-Rocha E.F^{1*}, Granados-Espinosa I.B¹ García-Cortes L.R², Dichi-Romero M²

¹Departamento de Medicina Interna, Hospital Regional de zona n° 72 Instituto Mexicano del Seguro social, Tlalnepantla, Estado de México, México.

²Headship service medical benefits OOAD East Regional Instituto Mexicano del Seguro Social, Mexico State.

***Corresponding author:** Cházaro-Rocha E, Departamento de Medicina Interna, Hospital Regional de zona n° 72 Instituto Mexicano del Seguro social, Tlalnepantla, Estado de México, México

Citation: Tadeo-Jiménez Y, Cházaro-Rocha E.F, Granados-Espinosa I.B. (2021) Severe Acute Pancreatitis Associated with SARS-CoV-2 Virus Infection: Case Report. Ann Case Report 6: 660. DOI: 10.29011/2574-7754.100660

Received Date: 05 May, 2021; **Accepted Date:** 10 May, 2021; **Published Date:** 14 May, 2021

Abstract

Introduction: The severe acute respiratory syndrome coronavirus 2 (SARS-CoV-2) induced by coronavirus (COVID-19) is responsible for the current pandemic that has affected more than 130 million people worldwide, its pathogenesis has been reported to affect glands of the endocrine system, the pancreas is no exception, as a background the pancreas has also been affected by other respiratory viruses.

Material and methods: We report the case of an 82-year-old male with a diagnosis of viral pneumonia due to SARS-CoV-2 who presented abdominal pain during his evolution, fulfilling Atlanta classification criteria for suspected pancreatitis, during his stay an abdominal axial tomography was performed, reporting grade C on the Baltazar scale, anti-inflammatory management was given, however the outcome was not favorable despite the management already established for COVID-19 and pancreatitis. The association between COVID-19 and pancreatitis was sought in other documented case reports. The results with the highest number of patients were reported by Wang et al. Within a 52 patients study with positive SARS-CoV-2, 8 patients had pancreatic lesions and biochemical alteration (elevated amylase and lipase) with an asymptomatic course.

Discusión: Understanding the clinical manifestations of COVID-19 continues to progress, this case illustrates that SARS-CoV-2 can precipitate acute pancreatitis in the setting of COVID-19.

Keywords: Acute pancreatitis; COVID-19 pneumonia; SARS-CoV-2 infection

Introduction

The severe acute respiratory syndrome coronavirus 2 (SARS-CoV-2) induced by coronavirus (COVID-19) is responsible for the current pandemic that has affected more than 130 million people worldwide, its pathogenesis, in severe cases it induces multi-organ failure [1]. In recent months, pulmonary, renal, cardiac, endothelial, hepatic and cerebral affections above all, have been studied.

Regarding organs related to the endocrine system, there are few reports of association. Regarding the thyroid gland, the THYRCOV study was published, which reported an association in 20% of cases of thyrotoxicosis related to coronavirus [2]. In the adrenal glands, findings were consistent with fibrinoid necrosis

found in 5 autopsies in patients with septic shock requiring steroid use [3]. Manifestations such as edema and neuronal degeneration in pituitary tissue were associated with central hypocortisolism, central hypothyroidism, and decreased dehydroepiandrosterone sulfate [4]. Cases of hyperglycemia have been reported regarding the pancreas as an endocrine and exocrine organ in non-diabetic patients. being an independent mortality factor. Pancreatitis is a multifactorial disease, the viruses that have been associated are parainfluenza, measles, coxsackie, Epstein-Barr and hepatitis A, recently associated cases with SARS-CoV-2 [1].

Materials and Methods

The clinical case's objective is to document the association between severe idiopathic acute pancreatitis in patients with active SARS-CoV-2 infection and to know the association variables that have been found in case reports.

Results

A 82-year-old male, Medical history was significant for type 2 diabetes and systemic arterial hypertension, denies alcoholism. On day +8 symptoms of fever, dry cough, progressive dyspnea, nausea, vomiting and diarrhea, developed, and the patient presented to the emergency department. The following vital signs were recorded: Blood pressure: 84/56 mmHg, Heart rate: 120 bpm, Respiratory Rate: 26 rpm, Temperature: 36.7°C, Oxygen Saturation in ambient air: 75%, neurologically conscious, responds to verbal stimulus with disorientation, although cooperative. The findings on the pulmonary exploration were diffuse rales without integrating condensation syndrome, a chest radiography was performed which was suggestive of SARS-CoV-2 pneumonia (Figures 1 and 2). Due to acute respiratory failure, he required supplemental oxygen with a reservoir mask, improving saturation to 88% on the first day of hospitalization. A soft, depressible abdomen is palpated, painful on medium and deep palpation in the epigastrium and mesogastrium no peritoneal irritation, peristalsis present. due to the location of the abdominal pain, laboratory tests were performed reporting: Serum amylase: 1534 U/L, Serum lipase: 5117 U/L, Albumin: 3 g/dl, AST: 28 U/L, ALT: 16 U/L, Total bilirubin: 0.49 mg/dl, Direct bilirubin: 0.14 mg/dL, Indirect bilirubin: 0.35 mg/dL, Total proteins: 6.83 g/dL, Leukocytes: 13000/mm³, Neutrophils: 11890/mm³, Lymphocytes 980/mm³, Platelets 338k/mL, Hemoglobin: 11.9 g/dL and hematocrit 38.63%. Due to the elevation of pancreatic enzymes, a liver and bile ducts ultrasound was performed on the second day of hospital stay, which reported: Liver in normal anatomical position, with dimensions within normal parameters, preserved morphology, regular borders, defined and delimited, the parenchyma is homogeneous without evidence of focal or diffuse lesion, the vascularity is preserved, no intra or extrahepatic gallbladder dilatation was observed., portal vein 9 mm, choledochal diameter 4 mm, gallbladder with dimensions of 74x36x33 mm, no lesions were shown, thin wall 2.3 mm thick. Pancreas was not assessed for the presence of gas in its topography, spleen without alterations in its parenchyma. For this reason, acute pancreatitis was integrated, then the fluid therapy started, along with pain management, empirical antibiotic and fasting due to oral intolerance. Studies are requested to determine the severity: Calcium: 9.3 mg/dL, Creatinine: 4.0 mg/dL, BUN 131 mg/dL, Urea: 280.7 mg/dL, Hematocrit: 38.6%, Glucose: 571 mg/dL, LDH: 252 U/L: BISAP score: 5pts. APACHE II: A Ranson: 3 during the initial 48hrs.

Due to the patient's respiratory status, a nasal swab was requested for RT-PCR for SARS-CoV-2, which was positive. On the 4th day, an abdominal CT scan was requested, finding the following findings: Edematous pancreatitis with peripancreatic fluid in all peritoneal recesses reporting grade C on the Baltazar scale.

During his stay, the clinical evolution was torpid even with the initial support treatments, he presented data of respiratory distress, the blood gas upon admission reported: pH 7.44, Pco₂ 32mmHg, pO₂ 64mmHg, HCO₃ 21 mEq/L, BE -1.5 mEq/L, O Sat 93%, PaO₂/FiO₂ ratio 305mmHg integrating type I respiratory failure, without criteria for intubation at the time of admission, it has a chest CT with a report of multiple diffuse alveolar infiltrates of baseline predominance compatible with viral pneumonia, CORADS 5, however 2 days later it progressed gradually to multiple organic failure the patient died.

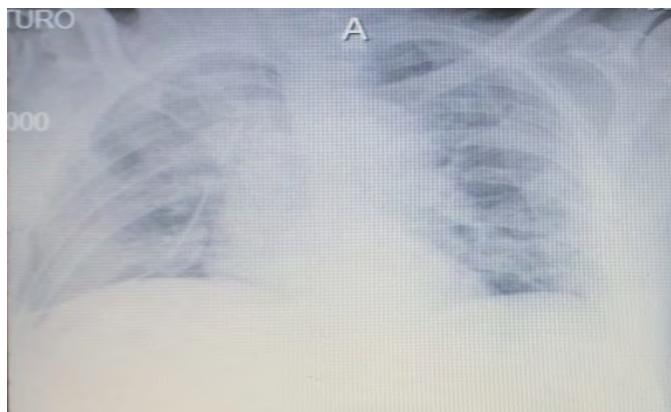


Figure 1: Plain chest radiograph: RALE 7-point bilateral interstitial socket pattern.

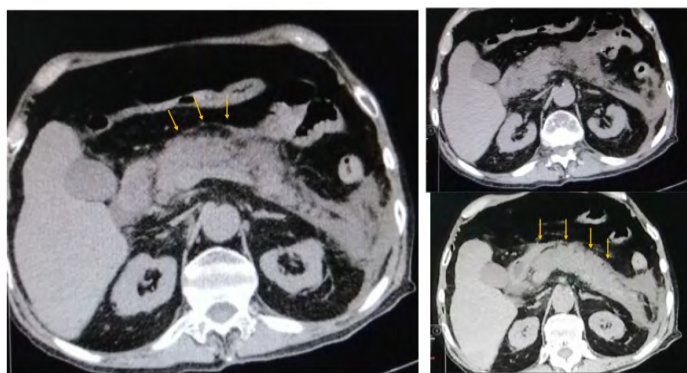


Figure 2: Computed Tomography Scan: Edematous pancreatitis with peripancreatic inflammation, peripancreatic fluid in all peritoneal recesses. Baltazar C.

Discussion

In context with the clinical case, during the week of admission, 67 patients with COVID-19 were received and only this case presented the definitive diagnosis of severe acute pancreatitis by Atlanta criteria not associated with the main causes: gallstones, alcohol, hypercalcemia and hypertriglyceridemia. The results support a potential damage to the pancreatic gland by SARS-

CoV-2 virus. In a study of 52 patients, 9 had pancreatic damage defined by any abnormality in lipase/amylase without demonstrating the direct presence of the virus in pancreatic tissue, 6 non-diabetic patients had abnormal glucose levels suggesting a cytopathic effect on the replication of SARS-CoV -2 and indirect damage by systemic inflammatory response, this had been observed in SARS-CoV-1 (2003) [5].

The pathogenesis of SARS-CoV-2 is mediated by the angiotensin converting enzyme receptor 2 (ACE-2) in host cells, which previously are highly expressed in pancreatic islets, acute pancreatitis in COVID19 could occur due to the direct cytopathic effect of local SARS-CoV-2 replication or indirectly by a harmful immune response induced by the virus [3].

Case reports are scarce, the study with the largest number of patients was reported by Wang et al [16]. Within a 52 patients with positive SARS-CoV-2, 8 patients had pancreatic lesions and biochemical alteration (elevated amylase and lipase) with an asymptomatic course. (wang et al) [16]. Regarding isolated cases, the most frequent etiologies of pancreatitis were studied, finding absence of alcoholism, lithiasis, hypertriglyceridemia, malformations. In addition to PCR positive for SARS-CoV 2, the outcomes were mostly favorable due to clinical improvement (Table 1).

Case Repot	Nº Patient/ Gender	Age	Risk Factors	COVID-19 Severity	Pancreatitis Severity	Outcome
Gonzalo-Voltas 2020 [6]	1/Female	76 years	Alcoholism 10 g / week Hypercholesterolemia	Moderate	Interstitial edematous	Favorable
Lakshmanan S. 2020 [7]	1/Male	68 years	Diabetes / Hypertension Chronic kidney disease	Mild (normal chest radiograph)	Edematous Baltazar B	Favorable
Brikman S 2020 [8]	1/Male	61 years	No antecedents	Moderate (bilateral infiltrates)	Edematous Baltazar D	Unknown
Meireles PA 2020 [9]	1/Female	36 years	ERC KDIGO V due HELLP Syndrome	Moderate (polished glass)	Association without image study	Favorable
Aloysius MM 2020 [10]	1/Female	36 years	Chronic anxiety treated with alprazolam	Severe	Unremarkable pancreas	Favorable
Kataria S 2020 [11]	1/Female	49 years	No antecedents	Severe	Edematous Baltazar B	Favorable
Mazrouei SSA 2020 [12]	1/Male	24 years	No antecedents	Mild	Edematous Baltazar C	Favorable
Karimzadeh S 2020 [13]	1/female	65 years	Hypertension Asthma	Moderate	Pleural effusion / Baltazar A with + biochemical pattern	Favorable
Hadi A 2020 [14]	2/Female	47/ 68 years	Both with no antecedents	Severe / Severe	Severe Pancreatitis	Unfavorable up to now *

Kumaran NK 2020 [15]	1/Female	67 years	Superior mesenteric arterial stenosis	Severe	Necrotic Pancreatitis	Favorable
Wang K 2020 [16]	2/Male	42/ 35 years	Both with no antecedents	Both Severe	Both with Baltazar C	Fatal and Favorable respectively
Rahman RA 2020 [17]	1/Female	52 years	Diabetes, hypertension, hypothyroidism, obesity	Moderate	Baltazar D	Favorable

Conclusion

We interpret despite not having a significant sample or analytical study that having a chronic degenerative history or an aggressive presentation of COVID-19 pneumonia could be associated with mortality when accompanied by pancreatic inflammation. However, our understanding of the clinical manifestations of COVID-19 continues to progress, and this case illustrates that SARS-CoV-2 can precipitate acute pancreatitis in the COVID-19 setting.

References

- Hegyí, P., Szakács, Z., Sahin-Tóth, M. (2020). Lipotoxicity and Cytokine Storm in Severe Acute Pancreatitis and COVID-19. *Gastroenterology*, 159: 824-827.
- Lania A, Sandri MT, Cellini M, Mirani M, Lavezzi E, et al. (2020). Thyrotoxicosis in patients with COVID-19: the THYRCOV study. *Eur J Endocrinol*. 183: 381-387.
- Iuga AC, Marboe CC, M Yilmaz M, Lefkowitz JH, Gauran C, et al. (2020) Adrenal Vascular Changes in COVID-19 Autopsies. *Arch Pathol Lab Med*. 144: 1159-1160.
- Pal R. (2020) COVID-19, hypothalamo-pituitary-adrenal axis and clinical implications. *Endocrine*. 68: 251-252.
- Liu F, Long X, Zou W, Fang M, Wu W, et al. (2020) Highly ACE2 expression in pancreas may cause pancreas damage after SARS-CoV-2 infection. *medRxiv.2020.02.28.20029181*.
- Gonzalo-Voltas A, Fernández-Pérez-Torres CU, Baena-Díez JM. [Acute pancreatitis in a patient with COVID-19 infection]. *Med Clin*. 155: 183-184.
- Lakshmanan S, Malik A. (2020) Acute pancreatitis in mild COVID-19 infection. *Cureus* 12: e9886.
- Brikman S, Denysova V, Menzal H, Dori G (2020) Acute pancreatitis in a 61-year-old man with COVID-19. *CMAJ* 192: E858–E859.
- Meireles PA, Bessa F, Gaspar P, Parreirae I, Silva VD, et al. (2020) Acalculous acute pancreatitis in a COVID-19 patient. *Eur J Case Rep Intern Med* 7: 001710.
- Aloysius MM, Thatti A, Gupta A, Sharma N, Bansal P, et al. (2020). COVID-19 presenting as acute pancreatitis. *Pancreatology*. 20: 1026-1027.
- Kataria S, Sharif A, Ur Rehman A, Ahmed Z, Hanan A. COVID-19 induced acute pancreatitis: a case report and literature review. *Cureus*. 12: e9169.
- Mazrouei SSA, Saeed GA, Al Helali AA. (2020) COVID-19-associated acute pancreatitis: a rare cause of acute abdomen. *Radiol Case Rep* 15: 1601-1603.
- Karimzadeh S, Manzuri A, Ebrahimi M, Huy NT, (2020). COVID-19 presenting as acute pancreatitis: lessons from a patient in Iran. *Pancreatology*. 20:1024-1025.
- Hadi A, Werge M, Kristiansen KT, Pedersen UG, Karstensen JG, et al. (2020) Coronavirus Disease-19 (COVID-19) associated with severe acute pancreatitis: case report on three family members. *Pancreatology* 20: 665-667.
- Kumaran NK, Karmakar BK, Taylor OM. (2020). Coronavirus disease-19 (COVID-19) associated with acute necrotising pancreatitis (ANP). *BMJ Case Rep* 13: e237903.
- Wang K, Luo J, Tan F, Liu J, Ni Z, et al. (2020). Acute pancreatitis as the initial manifestation in 2 cases of COVID-19 in Wuhan, China. *Open Forum Infect Dis*. 7: ofaa324.
- Rahman RA, Fateel T, Sayed JA, Alawadhi K. (2021) Acute pancreatitis in a patient with COVID-19. *BMJ Case Rep*. 14: e239656.
- Bradley EL. (1993) A clinically based classification system for acute pancreatitis *Arch Surg*, 189: 586-590.
- Lankisch PG, Weber-Dany B, Hebel K, Maisonneuve P, Lowenfels AB (2009) The harmless acute pancreatitis score: a clinical algorithm for rapid initial stratification of nonsevere disease *Clin Gastroenterol Hepatol*, 7: 702-705.
- J.H. Ranson, K.M. Rifkind, D.F. Roses, S.D. Fink, K. Eng, et al. (1974) Prognostic signs and the role of operative management in acute pancreatitis. *Surg Gynecol Obstet*, 139: 69-81.
- E.J. Balthazar, P.C. Freeny, E. Sonnenberg (1994). Imaging and intervention in acute pancreatitis *Radiology*, 193: 297-306.