



## Case Report

### Necrotizing Soft Tissue Infection of the Right Upper Thigh Secondary to Perforated Appendicitis in a de Garengéot's Hernia-Report of a Case and Review of the Literature

Dorothy Liu<sup>1</sup>, Chau Hoang<sup>1</sup>, Tracy Zhang<sup>2</sup>, Hongyi Cui<sup>1\*</sup>

<sup>1</sup>Department of Surgery, University of Massachusetts Medical School, UMass Memorial Medical Center, Worcester, MA 01655, USA

<sup>2</sup>University of Massachusetts Medical School, Worcester, MA, 01655, USA

\***Corresponding author:** Hongyi Cui, Department of Surgery, University of Massachusetts Medical School, UMass Memorial Medical Center, 55 Lake Avenue North, Suite S3-723, Worcester, MA 01655, USA

**Citation:** Liu D, Hoang C, Zhang T, Cui H. (2021) Necrotizing Soft Tissue Infection of the Right Upper Thigh Secondary to Perforated Appendicitis in a de Garengéot's Hernia-Report of a Case and Review of the Literature. Ann Case Report 6: 597. DOI: 10.29011/2574-7754.100597

**Received Date:** 29 March, 2021; **Accepted Date:** 10 May, 2021; **Published Date:** 17 May, 2021

#### Abstract

Necrotizing soft tissue infections (NSTI), which are associated with high morbidity and mortality, are most commonly associated with trauma or illicit drug use. However, NSTI of the flank, abdominal wall, perineum and upper thigh should also raise concern for intra-abdominal sources. De Garengéot's hernia is a rare entity that currently has no established treatment protocol due to its rare presentation – there are less than 100 published cases of de Garengéot's hernia since 1960. There is no report in the literature of NSTI secondary to de Garengéot's hernia. We describe a case of a 64-year-old male who presented with NSTI of the right thigh secondary to de Garengéot's hernia containing a perforated appendix.

**Keywords:** Necrotizing soft tissue infection; De Garengéot's hernia; NSTI of abdominal source; Abdominal infection.

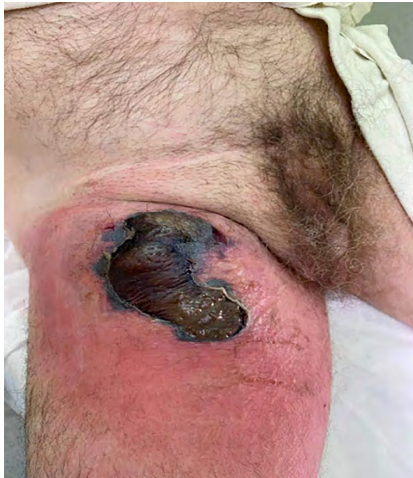#### Introduction

Necrotizing soft tissue infections (NSTIs) are associated with high morbidity and mortality rates, and accurate diagnosis and early intervention are crucial to achieve optimal outcome. Although trauma and illicit drug use are common risk factors for NSTI, it is important to consider intra-abdominal causes for NSTI of the abdominal wall, flank and thigh. Here we report a case of NSTI of the right upper thigh secondary to a de Garengéot's hernia containing a perforated appendix.

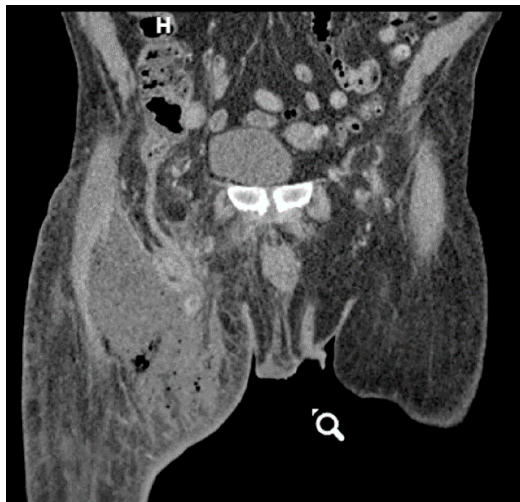De Garengéot's Hernia is a rare subtype of an incarcerated femoral hernia containing the vermiform appendix. It was named after the 18th century Parisian surgeon Rene Jacques Croissant de Garengéot, who first described this rare entity in 1731. Its typical presentation is in an emergent setting where acute appendicitis has developed within the femoral canal, but the true nature of the incarcerated tissue is rarely diagnosed preoperatively. No treatment protocol for De Garengéot's hernia currently exists due to its rare occurrence. This is the first report of NSTI in association with a De Garengéot's hernia.

#### Case

The patient is a 64-year-old male with a history of HTN, two prior right sided inguinal hernia repairs (1980s and 2010) who presented with complaints of right groin and medial thigh pain for 5 days. Of note, five days prior to arrival the patient had a fall at work but sustained no obvious injuries. In the first two days following his fall, he started to experience extreme pain and erythema in his right groin and medial upper thigh areas. The pain somewhat improved in the following days, but in the morning of his presentation he noticed a 6cm wide lesion on the medial aspect of his anterior right upper thigh that began to have malodorous, "yellowish pink" drainage. The lesion rapidly increased in size (Figure 1). On the day of presentation, the patient was initially seen at an outside hospital where he underwent a CT scan of the RLE demonstrating a significant amount of subcutaneous air on the medial and anterior thigh as well as a deep abscess, a femoral hernia and a tubular structure approaching the abscess cavity (Figure 2). Labs were notable for a white blood cell count of 20,500/ $\mu$ l, lactate 1.6 mmol/L, creatinine 1.14 mg/dL, sodium 135 mmol/L, hemoglobin of 12.8 g/dL and hematocrit 37.2%. He received Vancomycin and Zosyn prior to transfer and received Clindamycin upon arrival to our institution.

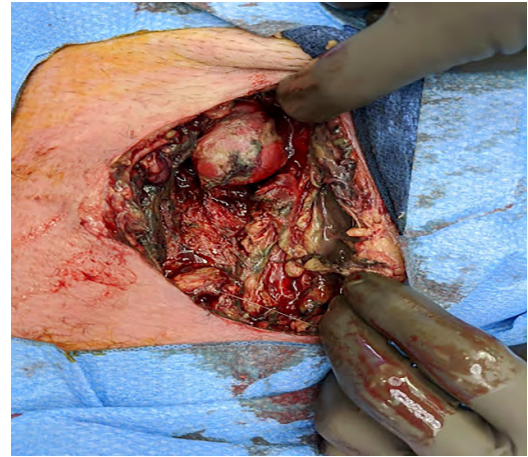


**Figure 1:** Anterior right upper thigh skin and soft tissue necrosis with surrounding erythema.



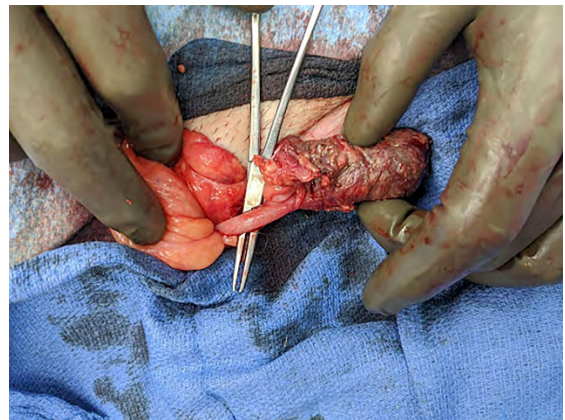
**Figure 2:** CT scan demonstrates a subcutaneous abscess with a collection of air as well as a femoral hernia containing a tubular structure approaching the abscess cavity.

The patient was resuscitated in the ED and taken to the operating room emergently for surgical intervention. In the operating room, the frankly necrotic skin and subcutaneous tissue on the anterior thigh was sharply excised along its border circumferentially. The large pocket of fluid visualized on the CT scan was entered and foul-smelling, dark and purulent fluid drained from the wound. This fluid was sent for cultures. Necrotic tissue extended down into the pectineal ligament and muscle layers was also excised and sent to pathology. After sharp excision of all necrotic tissue, the wound base was 15cm in length and 10cm wide. A hernia sac was visualized protruding from the femoral canal. The distal end of the sac was inflamed and necrotic, raising the concerns for a perforated appendix within the sac (Figure 3).



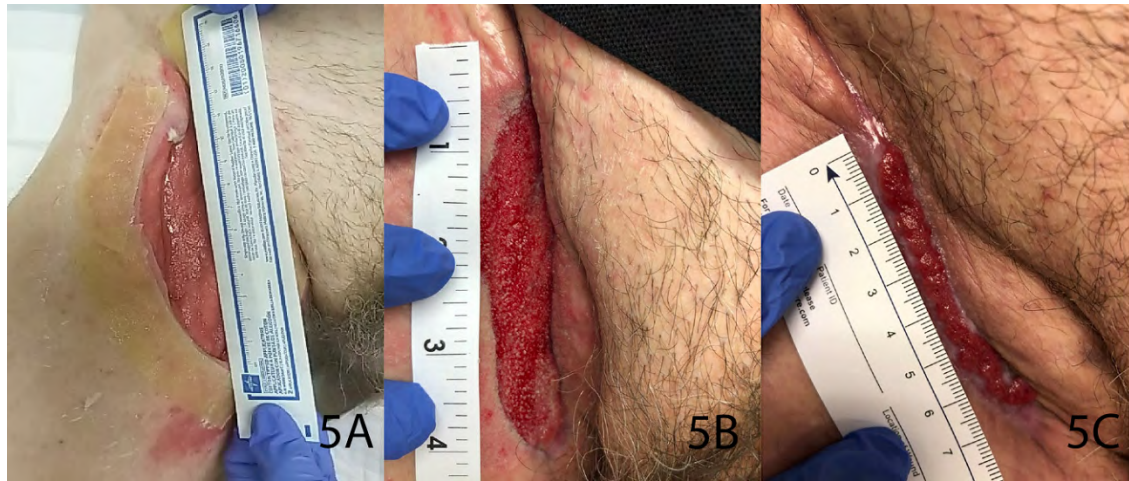
**Figure 3:** A thickened, inflamed femoral hernia sac with focal necrosis visualized after sharp debridement of necrotic tissue.

The sac was isolated and opened, and an infected appendix with perforation at the tip was identified. The inguinal ligament was partially transected to properly enlarge the right femoral canal, the appendiceal base and cecum were then delivered to the field and inspected and were healthy-appearing (Figure 4). Suture ligation of the appendiceal base was performed with a 2-0 silk suture, and the appendix was then transected with electrocautery. The mesoappendix was also suture-ligated and transected with electrocautery. The specimen was sent for histological examination and the appendiceal base was reduced into the abdomen. Throughout the duration of the operation the femoral vessels were periodically identified and protected from injury. The wound was irrigated with hydrogen peroxide and normal saline, and the femoral canal was plugged with a gauze bandage roll prior to packing the wound with a betadine-soaked gauze bandage roll. The entire wound was then covered with dry sterile dressings.



**Figure 4:** The healthy appendiceal base is visualized proximal to the inflamed hernia sac containing the portion of the appendix that has perforated.

Postoperatively, the patient's wound was managed with daily bedside dressing changes and his antibiotic coverage was de-escalated to Ancef and Flagyl (wound cultures returned as *Bacteroides fragilis* and fragilis group). Negative pressure wound therapy was applied to the wound on postoperative day 5. He was discharged on postoperative day 6 and at this time his antibiotics were discontinued, totaling a 7-day course. Postoperative follow up on day 14, day 27 and day 55 revealed a progressively healing wound without any sign of hernia recurrence (Figure 5 A-C). Pathologic examination of the specimen demonstrated acute appendicitis and periappendicitis with tip perforation.



**Figure 5:** (A) First outpatient follow up on postoperative day 14. (B) Appearance of groin wound at outpatient visit on postoperative day 27. (C) Groin wound at outpatient visit on postoperative day 55. Granulation tissue was treated with silver nitrate and covered with a dry sterile dressing.

## Discussion

Necrotizing soft tissue infections (NSTIs) are associated with high morbidity and mortality rates, and it is well established that successful treatment includes minimizing delays in surgical exploration and debridement. Delays can arise when nonspecific signs and symptoms make distinguishing NSTI from a simple cellulitis/abscess difficult, especially when there is no clear point of entry [1]. Although trauma and illicit drug use are common risk factors for NSTI, it is important to consider intra-abdominal causes for NSTI of abdominal wall, flank and thigh. This individual patient did suffer a minor fall at work several days prior, but there was no skin and soft tissue trauma because of the fall. This was clarified with the patient at the time of presentation. Wound cultures returned as *Bacteroides fragilis* and *fragilis* group, which are often associated with acute appendicitis. The area of NSTI was directly above the incarcerated femoral hernia, which contains an infected appendix with tip perforation confirmed by pathology.

Typical Fournier's gangrene (FG) is characterized as NSTI involving the perineum, anus, and genitalia; however, there are reported cases of FG presenting atypically as NSTI of the abdominal flank, or thigh. In a review of 67 cases of atypical FG, an associated bowel perforation was often overlooked, resulting in delays in surgical intervention and a mortality rate of > 33%, exceeding that of typical FG. Common causes of bowel injury among these pa-

tients included iatrogenic or surgical trauma and perforated appendicitis, and the most common sites of the presenting NSTI were the thigh and lower extremity [2].

NSTI due to a perforated appendix is rarely reported in literature, but reports have highlighted this dangerous complication as it is almost always associated with delayed diagnosis and treatment [3,4]. The Petit and Grynfeltt-Lesshaft lumbar triangles may contribute to the spread of infection or abscesses as these triangles lack muscular layers and are areas of weakness in the abdominal wall. One case report describes the role of the lumbar triangles in the propagation of retroperitoneal inflammation and/or abscess from a perforated retrocecal appendix to the flank and/or lumbar area [4]. Other reports describe intraoperative findings of incarcerated hernia, retroperitoneal abscess, or small bowel perforation presenting as NSTI of the thigh, drawing attention to the importance of considering an abdominal cause [5].

Although femoral hernias account for less than 5% of all abdominal wall hernias, the risk of strangulation (15-20%) is much higher compared to other types of hernias, likely a result of the narrow and rigid anatomy of the femoral canal [6,7]. In 1731, French surgeon Rene Jacques Croissant de Garengeot was the first to report a case of an appendix within an incarcerated femoral hernia [7]. Cases of de Garengeot's hernia, a femoral hernia that contains the appendix, are rare both in the clinical presentation

and in published literature. Approximately 1% of femoral hernias contains the appendix, and the presence of appendicitis within a femoral hernia occurs in only 0.08% to 0.13% of all cases [6]. There have been fewer than 100 cases of de Garengeot's hernia published from the 1960s onward [8]. This is the first report about NSTI in association with a de Garengeot's hernia.

Analyses of published reports of de Garengeot's hernia have demonstrated a strong predisposition for postmenopausal women, attributed to changes during pregnancy. Other risk factors include increased abdominal pressure, smoking, aging, and muscle and connective tissue disorders [9]. Clinical presentation is often a chief complaint of a painful right groin mass with duration of symptoms ranging from 3-5 days. Most patients underwent imaging investigations, with CT most likely to yield a positive diagnosis. However, preoperative diagnosis of de Garengeot's hernia is rare with most definitive diagnoses occurring intraoperatively, although we were almost certain with this patient upon review of imaging prior to surgery [9,10].

There is no established treatment strategy for de Garengeot's hernia, due to its rare nature and the low likelihood of preoperative diagnosis. Reported surgical strategies include open (inguinal or midline incision) or laparoscopic approach and repair of the hernia with and without mesh [7]. Laparoscopic repair can be considered when the preoperative diagnosis is made in a clinically stable patient. It allows for evaluation of the rest of the abdomen and the cecum, but should be used with caution if an appendiceal perforation or abscess is suspected. In an open repair, evaluation of the appendix through the groin incision without entry into the abdomen is appropriate as long as it can be drawn into the operative field. Mesh repair of the femoral hernia, while it is associated with lower hernia recurrence rate, should be avoided in an infected field [8]. There is a consensus that prompt surgical intervention is essential as delayed surgery could lead to life-threatening complications such as necrotizing fasciitis or necrosis of the hernia contents [9]. In this patient, the femoral canal appears to have sealed off with granulation following surgical debridement of NSTI and no hernia repair was rendered, continuous clinical follow up is needed for signs of hernia recurrence.

## References

1. Anaya DA, Dellinger EP. (2007) Necrotizing soft-tissue infection: diagnosis and management. *Clin Infect Dis Off Publ Infect Dis Soc Am.* 44: 705-710.
2. Kumar D, Cortés-Penfield NW, El-Haddad H, Musher DM. (2018) Bowel Perforation Resulting in Necrotizing Soft-Tissue Infection of the Abdomen, Flank, and Lower Extremities. *Surg Infect.* 19: 467-472.
3. Beerle C, Gelpke H, Breitenstein S, Staerkle RF. (2016) Complicated acute appendicitis presenting as a rapidly progressive soft tissue infection of the abdominal wall: a case report. *J Med Case Reports.* 10: 331.
4. Hua J, Yao L, He ZG, Xu B, Song ZS. (2015) Necrotizing fasciitis caused by perforated appendicitis: a case report. *Int J Clin Exp Pathol.* 8: 3334-3338.
5. Nijhof HW, Steenvoorde P, Bonsing BA, Hartgrink HH. (2006) Necrotizing soft tissue infection of the thigh: consider an abdominal cause. *World J Surg.* 30: 1836-1842.
6. Fousekis FS, Christou PA, Gkogkos S, Aggeli P, Pappas-Gogos G. (2018) A case of De Garengeot's hernia with acute appendicitis and literature review. *Int J Surg Case Rep.* 49: 55-57.
7. Misiakos EP, Paspala A, Prodromidou A, Machairas N, Domi V, et al. (2018) De Garengeot's Hernia: Report of a Rare Surgical Emergency and Review of the Literature. *Front Surg.* 5: 12.
8. Guenther TM, Theodorou CM, Grace NL, Rinderknecht TN, Wiedeman JE. (2021) De Garengeot hernia: a systematic review. *Surg Endosc.* 35: 503-513.
9. Kalles V, Mekras A, Mekras D, Papapanagiotou I, Al-HaretheeW, et al. (2013) De Garengeot's hernia: a comprehensive review. *Hernia J Hernias Abdom Wall Surg.* 17: 177-182.
10. Linder S, Linder G, Månsson C. (2019) Treatment of de Garengeot's hernia: a meta-analysis. *Hernia J Hernias Abdom Wall Surg.* 23: 131-141.