

Unusual Clinical Picture of a Comedo Mimicking Keratoacanthoma

Rauno J. Harvima*, Olli Saksela, Arja-Leena Kariniemi

Department of Dermatology, Kuopio University Hospital* and University of Eastern Finland* and Helsinki University Central Hospital, Finland

***Corresponding author:** Rauno J. Harvima, Department of Dermatology, Kuopio University Hospital, P.O.Box 1777, FIN-70211 Kuopio, Finland

Citation: Harvima RJ, Saksela O, Kariniemi AL. (2021) Unusual Clinical Picture of a Comedo Mimicking Keratoacanthoma. Ann Case Report 6: 647. DOI: 10.29011/2574-7754.100647

Received Date: 31 March, 2021; **Accepted Date:** 05 April, 2021; **Published Date:** 09 April, 2021

Case

A 61-year-old woman had adult type diabetes and hypercholesterolemia. For a few years she had mild to moderate plantar pustular eczema treated with intermittent topical class II corticosteroids. She developed within a month in the middle upper back a slightly itchy ball-shaped dark tumor with a diameter of 7 millimeters. The clinical picture (Figure 1) was fitting best to keratoacanthoma, and differential diagnosis included spinocellular carcinoma, atypical melanoma and pyogenic granuloma. The histology (Figure 2) revealed a comedo with a mild inflammation.



Figure 1: Comedo Clinical

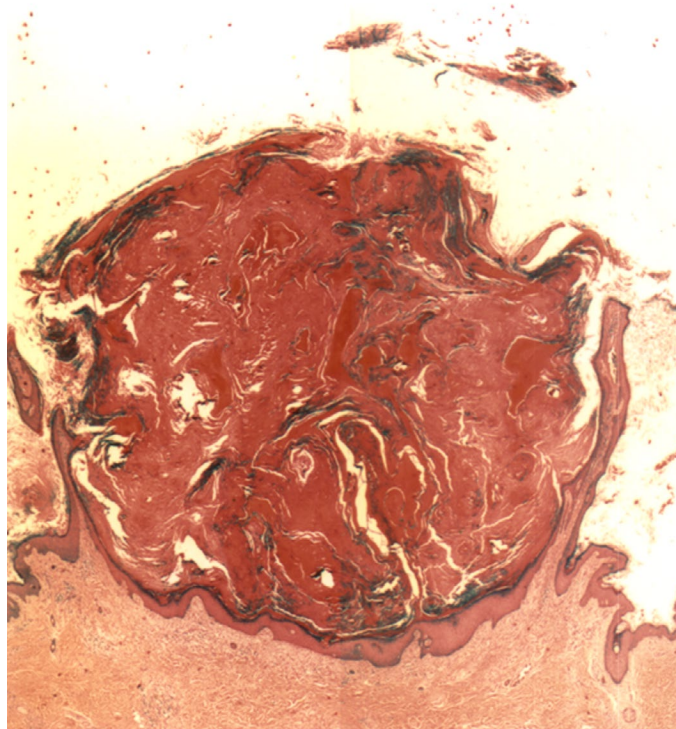


Figure 2: Comedo Histology