

Image Article

Giant Axillary Plexiform Neurofibroma in a Case of Neurofibromatosis Type 1

Alhad Mulkalwar, Sujay Jaju*, Samir Deolekar

Department of Surgery, Seth Gordhandas Sunderdas Medical College and King Edward Memorial Hospital, Mumbai, Maharashtra, India

*Corresponding author: Dr. Sujay Jaju, Intern, Department of Surgery, Seth Gordhandas Sunderdas Medical College and King Edward Memorial Hospital, Parel, Mumbai 400 012, Maharashtra, India

Citation: Mulkalwar A, Jaju S, Deolekar S (2021) Giant Axillary Plexiform Neurofibroma in a Case of Neurofibromatosis Type 1. J Surg 6: 1384. DOI: 10.29011/2575-9760.001384

Received Date: 19 March, 2021; Accepted Date: 29 March, 2021; Published Date: 05 April, 2021

Neurofibromatosis type 1 (NF-1), also known as Von-Recklinghausen disease, is a rare autosomal dominant genetic condition, resulting from mutation of the *NF1* gene (located at chromosome 17q11.2). It is characterized by multiple dermatological manifestations such as café au lait macules, axillary and inguinal freckling and tumoral growth along cutaneous nerves, called neurofibromas^[1].

Plexiform neurofibroma is a relatively uncommon variant of neurofibroma, which presents as deformed bulging masses arising from the nerves and involves connective tissue and skin folds (lesion described as a bag of worms)^[2]. Although these are generally benign, a significant potential for malignant transformation is present, which is seen in 5-10% of larger tumors^[3,4]. Owing to the infiltrating nature of these tumors, a complete resection is seldom possible.

We report a case of a 30 year old male who presented with a chronic history of progressively growing mass in his right axilla. Multiple smaller sized neurofibromas were appreciated all over the body including face, trunk and legs ranging from 0.7cm to 4.3cm in widest diameter, which also showed a positive buttonhole sign. Additionally, multiple café au lait macules (more than 6 in number, each greater than 15mm in size) were seen on various parts of the body (Figure 1), providing clinical diagnosis for Neurofibromatosis Type 1 according to National Institutes of Health Consensus Development Conference^[5]. Histopathological evaluation confirmed the diagnosis of plexiform neurofibroma (Figure 2). The patient was advised surgical intervention for symptomatic relief. He was counselled regarding its benefits, probable complications and chances of recurrence in this case. The patient however, denied surgery for the time being, post which he was lost to follow up.

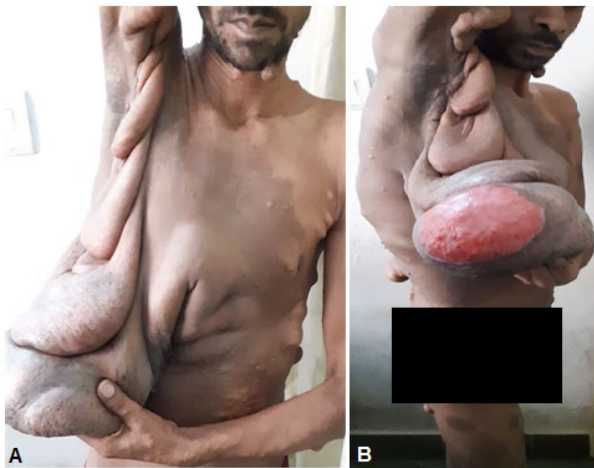

Figure 1: (A) A large mass in right axilla along with a large café au lait macule covering almost the entire chest and abdomen is visible. Multiple small nodules all over the body can be observed. (B) The axillary mass has grown to form multiple skin folds, resulting in massive excoriation of the underlying skin. Multiple café au lait macules can also be appreciated on the lateral aspect of right thigh.

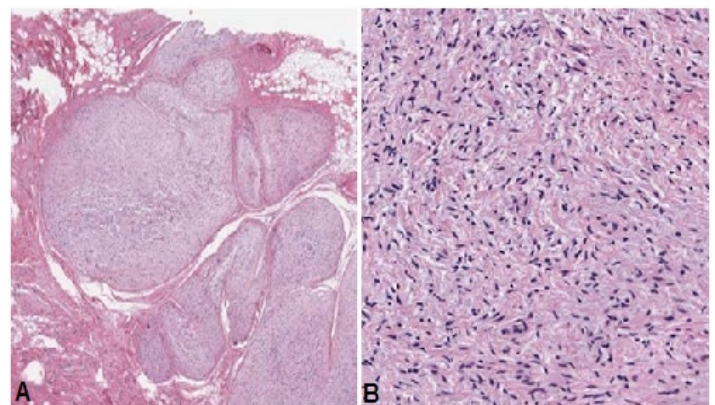


Figure 2: (A) Histopathology revealed numerous cross sections of tortuous dilated nerves with multinodularity. External perineurial layer is intact giving an encapsulated appearance to individual nodules. (B) On higher magnification, spindle shaped wavy cells in a background of schwann cells, fibroblast and collagen with increased amount of myxoid matrix can be appreciated.

References

1. Evans DG, Howard E, Giblin C, et al. (2010) Birth incidence and prevalence of tumor-prone syndromes: estimates from a UK family genetic register service. *Am J Med Genet A* 152A:327-332.
2. Tchernev G, Chokoeva AA, Patterson JW, Bakardzhiev I, Wollina U, et al. (2016) Plexiform Neurofibroma: A Case Report. *Medicine (Baltimore)* 95:e2663.
3. Cotran RS, Kumar V, Collins T, et al. (1999) *Robbins pathologic basis of disease*. W.B. Saunders Company 1999.
4. Louis DN, Ohgaki H, Wiestler OD, Cavenee WK "WHO Classification of Tumours of the Central Nervous System. 4th Edition Revised" .
5. Neurofibromatosis. NIH Consens Statement Online 6:1-19.

Citation: Mulkalwar A, Jaju S, Deolekar S (2021) Giant Axillary Plexiform Neurofibroma in a Case of Neurofibromatosis Type 1. J Surg 6: 1384. DOI: 10.29011/2575-9760.001384
