

## Extracervical Endoscopic Thyroid Surgery by Axillary Approach: First Case Series

José Sampaio Neto<sup>1</sup>, Taiana Naila Mazaro Zarelli<sup>1</sup>, Valdemar Pereira da Rocha Júnior<sup>2</sup>, Luiza Dall'Asta<sup>3</sup>, João Henrique e Silva Costa<sup>3</sup>, Luciano Zanellato Marques<sup>4</sup>

<sup>1</sup>Hospital Santa Casa de Curitiba, Brazil

<sup>2</sup>Hospital Universitário Cajuru, Brazil

<sup>3</sup>Pontifícia Universidade Católica do Paraná, Brazil

<sup>4</sup>Universidade do Oeste de Santa Catarina, Brazil

\***Corresponding author:** José Sampaio Neto, Hospital Santa Casa de Curitiba, Praça Rui Barbosa, 694 - Centro, Curitiba - PR, 80010-030, Brazil

**Citation:** Neto JS, Zarelli TNM, Júnior VPR, Asta LD, Costa JHS, et al. (2021) Extracervical Endoscopic Thyroid Surgery by Axillary Approach: First Case Series. Ann Case Report 6: 585 DOI: 10.29011/2574-7754.100585

**Received Date:** 22 December, 2020; **Accepted Date:** 15 March, 2021; **Published Date:** 19 March, 2021

### Abstract

To perform a thyroidectomy the classic approach is the Kocher technique. Despite safe, it does not end up with a satisfactory result on an aesthetic point of view. That is why others techniques have been developed to improve the aesthetic aspect of the incisions, like minimally invasive video-assisted thyroidectomy for example. This article addresses six extracervical endoscopic thyroid surgery by axillary approach and revealed more benefits, for the patients, than the open surgery, being the first case series by axillary approach described outside of Asia.

**Keywords:** Thyroid diseases; Thyroidectomy; Endoscopy; Minimally Invasive Surgical Procedures; Thyroid Gland.

**Abbreviations:** VAT-Video-assisted thyroidectomy; MIVAT-Minimally invasive video-assisted thyroidectomy; MINET-Minimally invasive, nonendoscopic thyroidectomy; CT-Conventional thyroidectomy; TOETVA-Transoral endoscopic thyroidectomy by vestibular approach

### Introduction

Two centuries ago, Emil Theodor Kocher (1841-1917), described for the first time a standardized technique of open thyroidectomy, which granted him the Nobel Prize in Physiology or Medicine in 1909. This procedure was widely spread in the western world, bringing contributions to many surgeons, such as Willian Halsted who not only performed physiology studies about thyroid and parathyroid glands, but also performed the first parathyroid autotransplantation in 1909 [1]. The Kocher technique is still performed in modern days, precisely because it is considered a safe procedure with low rates of postoperative complications. However, by using a single extended transverse skin incision, from 7 to 10 centimeters, it results in an displeased aesthetic result, which accentuates in our modern socio-cultural context [2-4].

Thyroid diseases are very common, reaching about 11% of the world population. It is characterized by predominantly affecting females compared to males, in a 4:1 proportion [5]. These peculiarities stimulate the formulation of new researches and studies focusing on how to perform new thyroidectomy techniques, looking for a better aesthetic and hypothetical secondary gains, such as a reduced operative duration, a better view and preservation of the adjacent structures, as parathyroid glands and recurrent laryngeal nerve [6]. Thinking about that, Gagner, in 1996, used an endoscopic parathyroidectomy technique, being it the reason that stimulated new researches for procedures involving thyroid and parathyroid [7].

Clinical studies referring to endoscopic thyroidectomy have made use of two kinds of surgical approach, mainly: a cervical approach and an extra-cervical approach [8]. The cervical approach was described by Miccoli et al. Currently, this technique is performed in two ways: a minimally invasive video-assisted thyroidectomy (MIVAT) and a minimally invasive, nonendoscopic thyroidectomy (MINET) [2,9].

There is also another approach called Video-Assisted Thyroidectomy (VAT). the use of VAT can reduce the chances of suffering early symptoms in the voice and in swallowing in

a post thyroidectomy surgery. The result showed that there was a significantly decrease in swallowing impairment score: 1 and 3 months after VAT, but not after conventional thyroidectomy (CT). The average impairment score of the voice 3 months after the surgery was significantly higher when compared to the postoperative group CT [10,11]. Training is still required to reduce operative time, which takes a longer time when compared to an open surgery and to the endoscopic cervical approach [6].

Concerning the extra-cervical thyroidectomy surgery, there is the axillary, subclavian, sternum, upper edge of areola and Transoral endoscopic thyroidectomy by vestibular approaches (TOETVA). This procedure can be done in a single spot, or in a variety of combined spots. The most common approaches start from the unilateral axillary position, unilateral lateral subclavian, bilateral breast, and unilateral subclavian combined with sternum [3,4].

An TOETVA, it's already have been done in Brazil [12,13]. In this technique the surgery is done through an 1,5 cm incision in mucosa on the lower lip and with the same traditional endoscopic materials. The experience of this approach have been related by oriental surgeons, and the complication related are bruises 5-17%, temporary paralysis of the recurrent laryngeal nerve 2.6 – 20% and transient hypoparathyroidism 5 – 17,5% [12].

The extra-cervical axillary route allows the surgeon to perform a surgery with a minimum of surgical dissection, being an excellent option for lobectomies, since all the thyroid gland can be observed from a lateral view without having to dissect the sternohyoid muscle. The risk of hypercapnia, respiratory acidosis, subcutaneous emphysema, and gas embolism are lower because a CO2 insufflation < 4 mmHg is used [3].

Although the use of extra cervical approach, including axillary, is growing in eastern countries, it has not been spread in western countries yet. In Brazil, there has already been in literature a study that makes use of cervical approach [14] and the transoral approach [12,13], however no work displays the extra-cervical approach by axillary route.

Therefore, the aim of this study is to describe a case series and its benefits using the extra-cervical approach by axillary route in a Brazilian hospital.

## Patients and Methods

This is a retrospective case report series, all the information was obtained through a review of 6 (six) patient's records, all women and with benign nodules. All procedures were partial thyroidectomy fulfilled in the same hospital in South of Brazil, by the same surgeon. Using the Extra-Cervical Thyroidectomy by axillary approach technique in the period between 2017 and 2020.

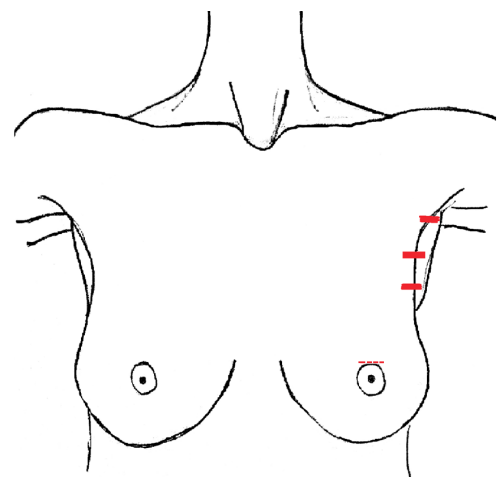
Inclusion criteria: (1) Patients negative for malignancy on fine

needle aspiration biopsy (FNAB). (2) Patients with symptoms related to the thyroid nodule.

Exclusion criteria: (1) Patients positive for malignancy on Fine Needle Aspiration Biopsy (FNAB).

## Surgical Technique

The surgery relies on preoperative preparation, which consists in putting the patient under general anesthesia in the supine position, performing the antisepsis and setting the sterile field. The procedure begins with a incision of about 10mm between the anterior axillary line and the axillary fossa on the proposed side of the surgery for the first trocar. The CO2 is insufflated dissecting the subcutaneous tissue making enough room so the other trocar can be inserted under direct observation. Two others trocars of 5mm are inserted in the anterior axillary line and, between the axillary fossa and the posterior axillary line, as showed in (Figure 1). One additional trocar can be inserted right above the areola mammae. When all trocars are inserted the dissection of deep surface is done until the thyroid gland is found and the median raphe is opened. The dissection of the lobe/lobes where the nodule is located is done, together with their luxation, the parathyroid glands are recognized and preserved. The electrocauterization is done with the use of the electrocautery. The thyroid gland is removed by one of the 5mm trocars and the sample is sent to pathological analysis. Before the incision is closed, a review of the hemostasis and the surgery is performed. Only then the subcutaneous tissue can be closed with Monocryl 3-0. The intradermal suture is performed with Monocryl 3-0 and end with dressing. The operating time was between 120 and 180 minutes (Table 1).



**Figure 1:** – Places for incision.

## Case Reports

The cases of six patients submitted to partial thyroidectomy through video-assisted extra-cervical approach by axillary route will be described next:

## Patient 1

Female, 48 years old, checked in general surgery service in September 2017, complaining of cervical mass for more than 2 years. An ultrasonography performed in 2016 revealed a hypoechoic nodule, ovoid, well-defined, measuring 2,7cm X 1,1cm X 2,0cm in the right thyroid lobe. Anatomopathological examination also performed in 2016, showed a substance compatible to colloid goiter. The patient only related eventual discomfort during meals, and aesthetic discomfort, and no other symptoms. Preoperative evaluations pointed to an ultra-sensitive TSH of 2,37 mUI/L and free T4 of 0,87 ng/dL. The patient was submitted to surgery in December 2017. In the postoperative period presented no dysphonia and no other complaints, being discharged from hospital the day after the surgery with a scheduled return to the clinic. In February 2018, it was presented dysphonia, and no other complaints. Routine exams showed a total calcium of 9,8mg/dL, ultra-sensitive TSH of 3,41 mUI/L, free T4 of 0,81 ng/dL and a PHT of 107,5 pg/mL. In March 2018 the patient no longer presented dysphonia nor other complaints. A biopsy of collected samples during surgery revealed follicular adenoma, with no malignancy. After routine exams - TSH, T4 and PTH – within normal range, the patient was discharged from general surgery service.

Patient	Age	Measuring nodule	Thyroid fine needle aspiration punch biopsy (Bethesda category)	Surgery	Discharge	Drain	Diagnostic	Complications
1	48	2,7 X 1,1 X 2,0cm.	III	Parcial thyroidectomy	Next day	No	Adenoma follicular	Temporary dysphonia
2	42	6,0X3,3X2,5cm.	II	Left Parcial thyroidectomy	Next day	No	Multinodular goiter. Lymphocytic thyroiditis (Hashimoto thyroiditis).	Hoarseness
3	25	6,4x3,7x5,1cm.	II	Left Parcial thyroidectomy	Next day	No	Follicular neoplasm	-----
4	38	3,2x2,9x2,7cm.	II	Parcial thyroidectomy	Next day	No	Multinodular goiter	-----
5	39	Left: 5,3x3,3x3,1 cm.	II	Left parcial thyroidectomy	Next day	No	Multinodular goiter-lymphocytic thyroiditis	-----
6	38	Right 4.1 x 3 x 3cm - left 1.4 x 0.9cm - isthmus 0.5 x 0.4cm	II	Right Parcial thyroidectomy plus isthmectomy	Next day	No	Right lobe: classic variant papillary carcinoma. Isthmus free from neoplastic cells.	-----

**Table 1:** characteristics evaluated in the complementary exams.

## Patient 2

Female, 42 years old, checked in general surgery service in January 2018 complaining of cervical mass for more than seven years. The patient has brought exams from 2017: An ultrasonography revealed a solid nodule in the left thyroid lobe; anatomopathological examination pointed a Bethesda Category II adenomatous nodule; anti-thyroglobulin, 446 UI/mL; anti-TPO 289 UI/mL. The patient was submitted to surgery in March 2018. In the postoperative period presented mild pain in the operative wound related to the movement of the left arm, no dysphonia, no

other complaints. Discharged from hospital on the day after the surgery with scheduled outpatient return. In April 2018 the patient complained of having weak voice and fatigue. Anatomopathological examination revealed the left thyroid lobular segment covered with a thin, fibrous capsule, measuring 6,0cm X 3,3cm X 2,5cm, composed by an elastic, finely grained reddish-brown tissue, with red winey hemorrhage areas and yellow calcification spots, with no malignancy. In May 2018, the patient checked in complaining of increase in the mass of the cervical region, a “hardened throat” feeling, hoarseness, snorting when sleeping, and hair loss. Routine exams showed TSH of 5,57, mUI/L, free T4 of 0,64 mg/dL and

thyroglobulin of 0,8 ng/mL. It was prescribed levothyroxine 50 mcg and follow up with clinical endocrinology.

### Patient 3

Female, 25 years old, referred to general surgery service in May 2018, complaining of cervical mass for more than seven months, with a progressive growth and sporadic pulsation. A doppler ultrasonography revealed the image of a nodule in the left thyroid lobe, ovoid, well-delimited, heterogeneous, predominantly hyperechoic, with the predominantly at the center of the doppler (Chammas IV), measuring 64x37x51mm, located at the higher, medium and lower parts of this lobe. Anatomopathological examination revealed a thyroid adenoma nodule, Bethesda category II – benign. The surgery was performed in August 2018, without any complications, under general anesthesia. The patient evolved postoperatively well, with no dysphonia, and no other complaints. The anatomopathological examination showed left thyroid lobe weighing 50,0 grams, with a rugous surface, covered with a slender, fibrous capsule measuring 6,0 x 4,5x 3,5 cm, opaque creamy-white colored. Microscopic exams of the sample showed a focal capsular invasion, follicular neoplasm, encapsulated microfollicular, trabecular and solid, moderately differentiated. A immunohistochemistry of the sample was requested.

### Patient 4

Female, 38 years old, referred to general surgery service in September 2018, complaining of dysphagia and dysphonia, due to an increase in the anterior cervical region for about 1 year. During the medical visit, the patient claimed to feel pain in the right cervical region. Thyroid ultrasonography has shown suggested signs of multinodular goiter, with emphasis to bilateral thyroid nodules (TI-RADS:4). FNA confirmed the multinodular goiter, and the biopsy has proved the Bethesda Category II, consistent with colloid nodule. The surgery was performed in October 2018, the procedure was performed under general anesthesia, with no complications. The patient evolved postoperatively well, with no dysphonia, no signs of wound infections and no further complaints. The anatomopathological examination confirmed the multinodular goiter diagnosed previously. The sample which was sent weighted about 20,0g, with uneven and lacerated surface, with a rugous surface, covered with a slender, fibrous capsule measuring 3,2 x 2,9 x 2,7 cm. At the cut it could be observed a multinodular surface, composed by an elastic, finely grained reddish-brown tissue, with winey bleeding and yellow calcification spots.

### Patient 5

Female, 39 years old, referred to general surgery service in august 2019, complaining of solid dysphagia for about 3 years. Patient brought a Thyroid ultrasonography: three nodules in the right lobe of the thyroid; a left lobe cyst measured 5.3 x 3.3 x

3.1 with heterogeneous echogenicity without regional lymph node enlargements. Diagnostic impression: enlargement of the thyroid gland caused by right lobe nodules and a heterogeneous cyst. FNA: negative for malignancy, Bethesda category II. Cytological findings may be suggestive of colloid nodules. A left partial thyroidectomy was performed in October 2019, under general anesthesia and without complications. A postoperative with a good recovery, without dysphonia and no other complaints. Anatomopathological analysis revealed a colloid cyst – lymphocytic thyroiditis; weighing 20,0 grams, measurement of the left lobe: 5.5 x 3.5 x 1.5cm. Outer surface was bosselated, surrounded by a thin fibrous capsule. Histological slides shows a multinodular aspect surface, composed by brownish, elastic and thin granulation tissue with two whitish irregular areas, the bigger one measured 0.2 x 0.2cm. It also shows cystic areas with elastic and whitish walls, fulfilled by a reddish-brown liquid material, with a gelatinous, reddish-brown aspect material stick to the wall, measuring 2.9 x 1.5cm. Postoperative labs (December 2019): TSH 4,69 mUI/L, free T4 0,92 mg/dL, PTH 26,4, TRAB 0,10 UI/L, anti-TPO 35UL/mL, ATG 15UI/mL. Patient referred to follow up with endocrinology, being discharged of general surgery.

### Patient 6

Female, 38 years old, referred to general surgery clinic because of thyroid nodule, during the visit she complained of aphonia, hoarseness, cough and dysphasia for solid foods. No weakness, gain or weight loss in the past few days. Thyroid ultrasound with suggestive signs of multinodular goiter, bilateral nodules - right 4.1 x 3 x 3cm and left 1.4 x 0.9cm and a nodule in the isthmus measuring 0.5 x 0.4cm (TI-RADS: 3). FNA: negative for malignancy, Bethesda category II. Postoperative labs: TSH 2,004 uIU/mL, free T4 0,80 ng/dL. Underwent a right partial video-assisted surgery in March 2020, under general anesthesia without complications. Postoperative with a good recovery, without dysphonia, with no signs of wound infections and no further complaints. Anatomopathological revealed weight of 30.0 grams, right lobe measurement 4.3 x 3.5 x 2.6cm, isthmus 3.5 x 2.5 x 1.0cm. Bosselated outer surface, surrounded by a thin fibrous capsule. Histological slides of the right lobe shows a solid, cystic and gelatinous surface with a firm consistency, finely granulated, and whitish scattered areas. Isthmus slides shows brownish red elastic, thin and granulated tissue, with red wine hemorrhage areas – well-differentiated classic variant papillary carcinoma partially encapsulated. Multifocal tumor. Tumor site: right lobe. Largest tumor dimension: 1.3cm. Free surgical margins with close focal edges. Vascular invasion: present. Lymphatic invasion: absent. Mitotic rate: not identified. Perineural invasion: not identified. Extrathyroid extention: not identified. Thyroid isthmus free from neoplastic cells. Pathological staging (tnm 2010): pt1b pnx pmx.



## Discussion

Regarding to the epidemiology of the thyroid gland diseases, all the surgeries described in this case report have been performed in women, which demonstrates a higher importance in relation to aesthetic in this procedure, as women tend to be more careful with body image than men do [3,4]. The operatory wound in all patients varied between 1-1,5cm and the suture made were intradermal, therefore the surgery scar became almost undetectable in the postoperative evolution, since the scars were in places that were not so exposed (axillary region). In comparison with the classic technique (which has bad aesthetic results), the TOETVA and the approach described in this article (axillary) demonstrated more benefits regarding the surgery scar.

The endoscopic thyroidectomy by axillary approach allows a better exposition, a enlargement of the visual field and a better view of the vascular structures and nerves of the region, resulting in less chance of accidental lesion of these structures and better hemostasis. It was not observed the formation of bruises, seroma, nor significant dysphonia. None of the patients presented any kind of change in swallowing. Furthermore, it was not required a conversion to open surgery in any of the patients. As to the parathyroid glands, theoretically there is a higher chance to preserve them as a result of having a superior visual field. None of the patients presented symptoms of hypoparathyroidism in the postoperative period.

The average operating time was 2 hours, comparatively less than the studies with the transoral endoscopic thyroidectomy by vestibular approach technique, which was 3.5 hours [12,13]. Despite having a long learning curve, the operating time is similar to a conventional thyroidectomy and similar to the video-assisted cervical thyroidectomy, with an average time of 1.5 hour to a total thyroidectomy and an average time of 1 hour to a lobectomy + isthmectomy [14].

All performed procedures were just lobectomies or lobectomies + isthmectomy, and the nodules varied between 1,1 to 6,0cm. This surgical modality is still only designated to small to medium sized unilateral benign nodules.

## Conclusion

Despite being the classic method of surgery, the Kocher technique still brings negative aesthetic results to the patients submitted to it. However, because it is the most common, the surgery proves to be the most effective regarding to safety. The extra-cervical video-assisted technique brought aesthetic

benefits to patients of the presented question, yet there is not a stablished security profile due to its recent implementation. Thus, it is possible to conclude that more studies about this surgery technique is required, in order to analyze the aesthetic benefits and to stablish a security profile and monetary difference between the two techniques.

## Conflict of interest

The authors declare that there is no conflict of interest.

## References

1. Brandão LG. (2008) Artigo de Revisão: Kocher e a história da tireoidectomia. 37: 240-3.
2. Duke WS, Terris DJ. (2014) Alternative approaches to the thyroid gland. *Endocrinol Metab Clin N Am*. Elsevier Inc; 43: 459-474.
3. Ikeda Y, Takami H, Sasaki Y, Kan S, Niimi M. (2000) Endoscopic neck surgery by the axillary approach. *J Am Coll Surg*. 191: 336-340.
4. Shimazu K, Shiba E, Tamaki Y, Takiguchi S, Taniguchi E, et al. (2003) Endoscopic thyroid surgery through the axillo-bilateral-breast approach. *Surg Laparosc Endosc Percutan Tech*. 13: 196-201.
5. Ubirajara C, Friguglietti M, Cividanes R. (2008) Artigo Original Análise retrospectiva das tireoidectomias realizadas por residentes de cirurgia geral em hospital universitário. 37: 67-70.
6. Zhang CG, Shi X. (2012) Systematic comparison of cervical and extra-cervical surgical approaches for endoscopic thyroidectomy. 42: 835-41.
7. Gagner M. (1996) Endoscopic subtotal parathyroidectomy in patients with primary hyperparathyroidism. 83: 875.
8. Russell JO, Noureldine SI, Khadem MG Al, Tufano RP. (2016) Minimally Invasive and Remote-Access Thyroid Surgery in the Era of the 2015 American Thyroid Association Guidelines. 1: 175-179.
9. Metidieri MM, Moraes GCDE. (2008) Interventional Techniques of Totally Endoscopic Thyroidectomy. 3: 116-121.
10. Liu J, Song T, Xu M. (2012) Minimally invasive video-assisted versus conventional open thyroidectomy: A systematic review of available data. *Surg Today*. 42: 848-856.
11. Lombardi CP, Raffaelli AEM, Lucia AED, Crea AEC De. (2008) Video-Assisted Thyroidectomy Significantly Reduces the Risk of Early Post thyroidectomy Voice and Swallowing Symptoms. 32: 693-700.
12. Gomes MA, ACBC-RJ, Silva GD. (2018) Tireoidectomia endoscópica pelo acesso transvestibular (TOETVA). *Relatos Casos Cir* :e1957
13. Tesseroli, Marco Antonio Scirea; Spagnol, Mauricio; Sanabria, Álvaro. (2018) Tireoidectomia endoscópica transoral por acesso vestibular (TOETVA): experiência inicial no Brasil. *Rev. Col. Bras. Cir*, 45: e1951.
14. Experience VT, Cases In. (2007) Tireoidectomia Vídeo Assistida: Experiência De 120 Casos. 34:1-6.