



## Case Report

# Coexistence of Tyrosinemia and Friedreich Ataxia in a Single Patient: Treatment with Liver Transplantation

Diya Cherian<sup>1</sup>, Kimberly Schadt<sup>1</sup>, Courtney Park<sup>1</sup>, Stephanie Veasey<sup>2</sup>, David Goldberg<sup>2</sup>, David Lynch<sup>1\*</sup>

<sup>1</sup>Division of Neurology Department of Pediatrics, Perelman School of Medicine at the University of Pennsylvania Children's Hospital of Philadelphia, Abramson Research Center Civic Center Blvd, Philadelphia, Pennsylvania, USA

<sup>2</sup>Division of Hepatology and Medicine, Perelman School of Medicine at the University of Pennsylvania, Pennsylvania, USA

\***Corresponding author:** David Lynch, Division of Neurology Department of Pediatrics, Perelman School of Medicine at the University of Pennsylvania Children's Hospital of Philadelphia, Abramson Research Center Civic Center Blvd, Philadelphia, Pennsylvania, USA.

**Citation:** Cherian D, Schadt K, Park C, Veasey S, Goldberg D, et al. (2021) Coexistence of Tyrosinemia and Friedreich Ataxia in a Single Patient: Treatment with Liver Transplantation. Ann Case Report 6: 581. DOI: 10.29011/2574-7754.100581

**Received Date:** 16 January, 2021; **Accepted Date:** 25 February, 2021; **Published Date:** 04 March, 2021

**Keywords:** Friedreich ataxia; Tyrosinemia type 1; Nitisinon; Liver transplant

## Background

Friedreich's ataxia (FRDA) is an autosomal recessive disease leading to impaired coordination, progressive weakness, fatigue, spasticity, hypertrophic cardiomyopathy, scoliosis, and diabetes mellitus [1]. The majority of individuals with FRDA have onset between the ages of five and 18 years, although late onset and very late onset ataxia occur in 25% of patients. FRDA arises from the presence of two mutated alleles of the FXN gene (usually GAA expansions), leading to decreased production of the protein frataxin. Frataxin facilitates assembly of iron-sulfur clusters for enzymes of the Krebs cycle, oxidative phosphorylation and other cellular functions [2].

Another autosomal recessive disorder is Tyrosinemia, a genetic disorder created by disturbances to the catabolism of tyrosine reflecting deficiency of fumarylacetoacetate hydrolase (FAH) [3]. This leads to an excess of toxic intermediates and byproducts of tyrosine metabolism. There are three types of tyrosinemia classified by their severity. Type one tyrosinemia (HT1) often begins within the first few months following birth. Such individuals later develop peripheral neuropathy and a decline in respiratory function. Over time, HT1 can lead to liver and kidney disease and increases the likelihood of hepatocellular carcinoma (HCC). Without intervention, HT1 may prove fatal in less than a decade. Nitisinone (NTBC) is used to manage progression by inhibition of the enzyme fumarylacetoacetate hydrolase (FAH), which blocks production of toxic metabolites. The use of NTBC raises plasma tyrosine level; consequently, the drug must be coupled with a diet low in phenylalanine and tyrosine to prevent toxicity.

Here we describe a young woman with coincidental presence of both FRDA and HT1, focusing on possible interactions between HT1 and FRDA, as well as her treatment by liver transplantation.

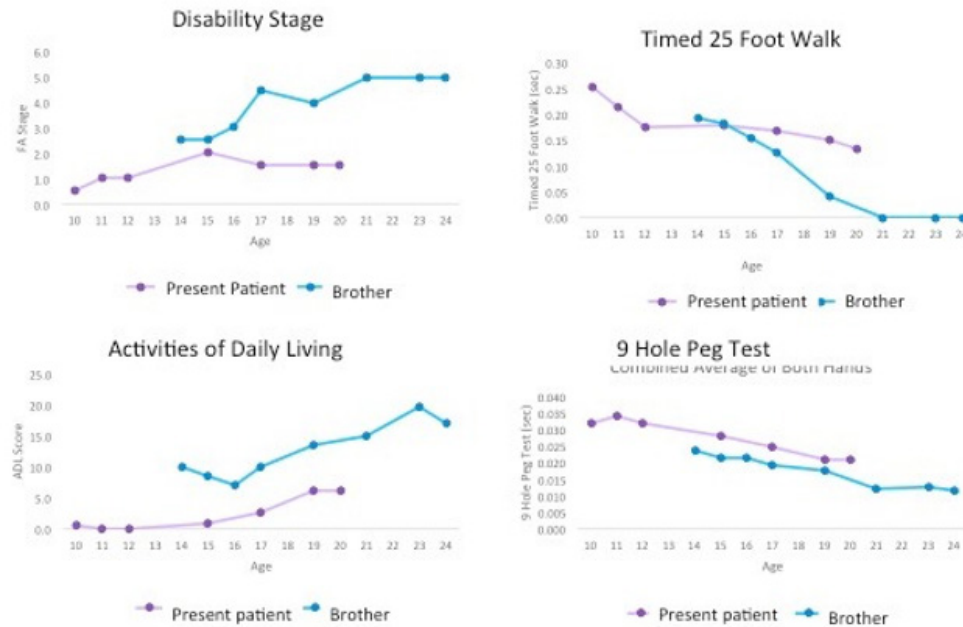
## Case Presentation

The patient was diagnosed with HT1 at 6 weeks of age, and manifested liver failure within 4 weeks. She was started on NTBC and a low protein diet. Later, she was diagnosed with FRDA by predictive testing at age 10 years after her brother presented with ataxia, hypertrophic cardiomyopathy and scoliosis at age 14. She remained minimally affected with minimal progression, no features of cardiomyopathy and mild scoliosis (10°) (Figure 1) through the next 10 years [4]. At age 19, she developed an 8mm lesion on liver MRI felt to represent a hepatocellular carcinoma; it was treated with a liver transplant in January 2019 from a cadaveric donor. Her Model for End-stage Liver Disease score was 30 at that point. She did well until serum transaminases increased on post-operative day 6; she was started on Imuran, Tacrolimus, and Prednisone leading to improvement in liver function, then maintained on Tacrolimus and Imuran long term. Immediate postoperative complications included transient steroid induced hyperglycemia. Later complications included iron deficiency anemia, which improved with iron infusions, acne and hair loss. At present, she has stable graft function. Her FRDA has progressed minimally since liver transplantation.

## Discussion

The combination of FRDA and HTI in this patient provides insight on treating disorders coexisting with FRDA. Although performed for a reason unrelated to FRDA, the outcome demonstrates the potential safety and value of organ

transplantation in FRDA. Although such a procedure has not previously been performed in FRDA, liver transplantation here provided the appropriate therapy for a complication of tyrosinemia. In FRDA, a limited number of individuals have received cardiac transplants [5,6]. The present subject further demonstrates that organ transplantation is potentially useful when needed in FRDA. In addition, as her course with FRDA has been slower than her brothers', the present study suggests that the presences of abnormalities of tyrosine metabolism and their treatment do not worsen the course of FRDA.



**Figure 1:** Comparison of Clinical course in present patient and her brother. Patient and her brother were examined every year for 10 years during clinical care. Graphs show disability stage, Activities of daily living, timed walk, and 9 Hole pegboard scores [4]. At every age, the patient has less dysfunction than her brother, though they had similar GAA repeat and Frataxin levels.

**Ethics Approval, Consent to Participate and Consent for Publication:** All studies were conducted as a component of the Friedreich Ataxia Clinical Outcome Measures Study, approved the IRB at the Children's Hospital of Philadelphia. Both subjects have given written permission to publish the work and reviewed a copy of the manuscript.

**Competing Interests:** The authors declare no competing interests with regard to the present work

**Funding:** This research did not receive any specific grant funding from agencies in the public, commercial or not for profit sectors.

**Authors' Contributions:** Ms. Cherian drafted the initial manuscript, performed background research and data calculations. Ms Schadt carried out critical review of the manuscript, supervised data collection. Ms Park carried out data collection and provided critical review. Dr. Goldberg carried out data collection and provided critical review. Dr. Lynch aided in writing the first draft, performed data collection, and provided critical review.

## References

1. Babady NE, Carelle N, Wells RD, Rouault TA, Hirano M, et al. (2007) Advancements in the pathophysiology of Friedreich's Ataxia and new prospects for treatments. *Mol Genet Metab* 92: 23-35.
2. Rötig A, de Lonlay P, Chretien D, Foury F, Koenig M, et al. (1997) Aconitase and mitochondrial iron-sulphur protein deficiency in Friedreich ataxia. *Nat Genet* 17: 215-7.
3. Chinsky JM, Singh R, Ficicoglu C, van Karnebeek CDM, Grompe M, et al. (2017) Diagnosis and treatment of tyrosinemia type I: a US and Canadian consensus group review and recommendations. *Genet Med*.
4. Patel M, Isaacs CJ, Seyer L, Brigatti K, Gelbard S, et al. (2016) Progression of Friedreich ataxia: quantitative characterization over 5 years. *Ann Clin Transl Neurol* 3: 684-94.
5. McCormick A, Shinnick J, Schadt K, Rodriguez R, Addonizio L, et al. (2017) Cardiac transplantation in Friedreich Ataxia: Extended follow-up. *J Neurol Sci* 375: 471-473.
6. Yoon G, Soman T, Wilson J, George K, Mital S, et al. (2012) Cardiac transplantation in Friedreich ataxia. *J Child Neurol* 27: 1193-6.