



Pyoderma Gangrenosum Complicated by Myopathy after Tumor Resection Surgery: A Rare Case Report

Joe Hasei¹, Toshiyuki Kunisada², Eiji Nakata¹, Tomohiro Fujiwara¹, Toshifumi Ozaki¹

¹Department of Medical Materials for Musculoskeletal Reconstruction, Okayama University Graduate School of Medicine, Dentistry and Pharmaceutical Sciences

²Department of Orthopaedic Surgery, Okayama University Graduate School of Medicine, Dentistry and Pharmaceutical Sciences

***Corresponding author:** Joe Hasei, Department of Medical Materials for Musculoskeletal Reconstruction, Okayama University Graduate School of Medicine, Dentistry and Pharmaceutical Sciences, Japan

Citation: Hasei J, Kunisada T, Nakata E, Fujiwara T, Ozaki T (2021) Pyoderma Gangrenosum Complicated by Myopathy after Tumor Resection Surgery: A Rare Case Report. Ann Case Report 6: 634. DOI: 10.29011/2574-7754.100634

Received Date: 17 February, 2021; **Accepted Date:** 20 February, 2021; **Published Date:** 25 February, 2021

Abstract

Pyoderma gangrenosum (PG) is a type of an ulcerative, neutrophilic, and inflammatory dermatitis. It is associated with systemic diseases such as inflammatory bowel disease and rheumatoid arthritis in up to 78% of the cases, and has a female predilection. In about 25-50% of the cases, it is caused by a nonspecific external stimulus such as trauma or surgery and is difficult to diagnose especially when it occurs postoperatively. PG often mimics postoperative wound infection and commonly affects areas include the feet and legs. In about 25-50% of the cases, it is caused by a nonspecific external stimulus such as trauma or surgery and is difficult to diagnose. We describe the clinical course of a patient with PG who was misdiagnosed with a surgical site infection and treated with surgical debridement that led to an exacerbation of the lesion. We performed a surgical debridement 8 days postoperatively, but the wound necrosis progressed rapidly again just 3 days after the debridement. Systemic corticosteroids improved the necrotic ulcer dramatically. To the best of our knowledge, this is the first case report of PG following a wide resection for a malignant soft tissue sarcoma. The infection rate is very high due to extensive defects resulting from the wide resection of sarcomas, making the diagnosis of PG important.

Introduction

Pyoderma gangrenosum (PG), first described in 1930, is a type of an ulcerative, neutrophilic, and inflammatory dermatitis, and it is associated with several chronic diseases such as inflammatory bowel disease, rheumatoid arthritis, and hepatitis. PG often mimics postoperative wound infection and commonly affects areas include the feet and legs. In about 25-50% of the cases, it is caused by a nonspecific external stimulus such as trauma or surgery and is difficult to diagnose especially when it occurs postoperatively. The rapid evolution of the cutaneous necrosis is often curtailed by a surgical debridement of the wound that in turn can trigger an exacerbation of the skin ulcer and lead to disastrous consequences, thus necessitating a prompt diagnosis. A detailed history and knowledge of the typical clinical and histologic features of PG are helpful diagnostic aids. We describe the clinical course of a patient with PG who was misdiagnosed with a surgical site infection and treated with surgical debridement that led to an exacerbation of the lesion. To the best of our knowledge, this is the first case report of PG following a wide resection for a malignant soft tissue sarcoma. The patient was informed that data from the case including his

photographs would be submitted for publication, and his consent was obtained.

Report of the case

A 48-year-old male was admitted to a hospital 3 months ago, following a road traffic accident. His whole body CT scan incidentally revealed a soft tissue tumor, with calcification, in his right thigh. MRI revealed a well-defined mass within vastus intermedius muscle that was predominantly lipomatous; with thick septa and nodular areas. One part of the tumor showed high signal intensity on T1- and T2-weighted images (suggestive of an atypical lipomatous tumor), while another part showed low and high signal intensity on T1- and T2-weighted images, respectively (suggestive of a dedifferentiated liposarcoma) (Figure 1). We performed a wide resection for the tumor; however, 3 days later, erythema and increased local temperature were observed over the surgical site (Figure 2A). The patient also had fever and his C-reactive protein (CRP) level and WBC count were 100 mg/l and $13.5 \times 10^9/l$, respectively. These clinical features were suggestive of a postoperative infection. The patient was prescribed cefazolin

twice daily; however, 7 days postoperatively, his CRP level increased to 135 mg/l and WBC count was $18.0 \times 10^9/l$. MRI findings suggested the presence of an infected hematoma and extensive inflammation within vastus intermedius muscle (Figure 2B,C). Thus, we performed a surgical debridement 8 days postoperatively, and also changed the antibiotics to MEPM (Meropenem). However, the wound necrosis progressed rapidly; and 3 days after the debridement (Figure 3A), the WBC count increased to $21.4 \times 10^9/l$ and CRP level remained elevated (148 mg/l). Although the results of bacterial culture of the vastus intermedius muscle hematoma were negative; however, clinical findings still indicated a postoperative infection. On the 4th day after the debridement, we again changed the antibiotics to a combination of LZD (Linezolid) and LVFX (Levofloxacin); however, necrotic ulcers with pain were observed around the surgical site (Figure 3B). The necrotic ulcers enlarged steadily, and we sought a dermatology consultation, and we requested our dermatologist to re-evaluate the patient. The dermatologist performed a skin biopsy, and the histological examination showed non-specific features without any microorganisms on Gram staining. Consequently, a diagnosis of PG was made. The patient received systemic corticosteroids from the 8th day after the debridement. A tapering regimen of methylprednisolone was prescribed as follows: 30 mg, 20 mg, and 10 mg daily for the first, second, and third week, respectively. The necrotic ulcers and CRP level improved dramatically (Figure 4). Finally, the patient received 5 mg methylprednisolone daily, for 2 months. His wound healed completely and no inflammation within vastus intermedius muscle was observed on MRI (Figure 5).

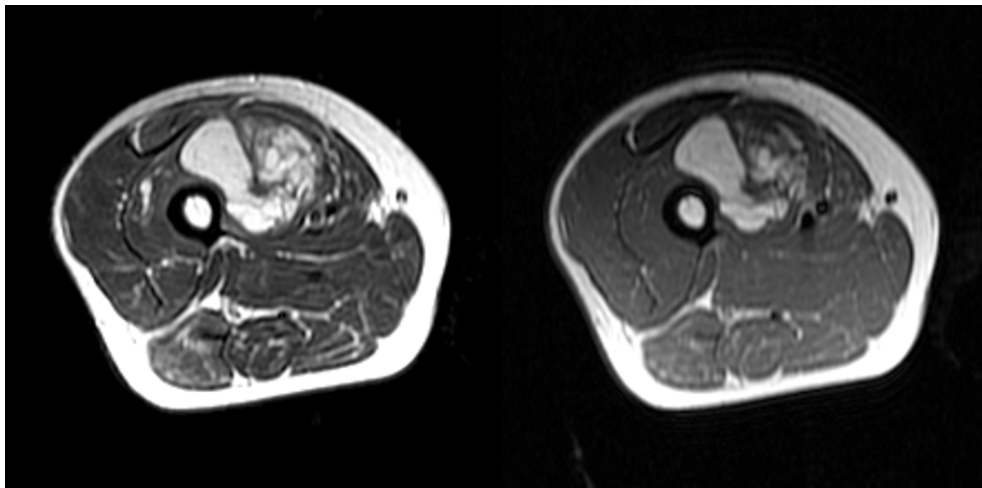


Figure 1: Magnetic resonance images of the right thigh before surgery. A: T1-weighted axial image. B: T2-weighted axial image. One part of the tumor showed high signal intensity in both T1- and T2-weighted images, suggestive of atypical lipomatous tumor, while the other part showed low and high signal intensity on T1- and T2-weighted images, suggestive of dedifferentiated liposarcoma.

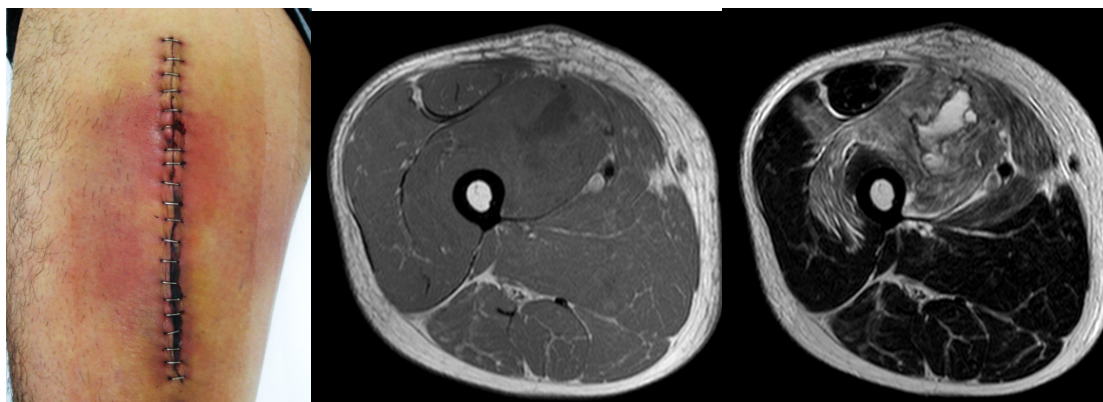


Figure 2: Magnetic resonance images and photograph of the right thigh after tumor resection. A: Photograph of the surgical wound. Erythema and local increase in temperature were observed around the surgical site. B: T1-weighted axial image. C: T2-weighted axial image. MRI findings were suggestive of an infected hematoma and extensive inflammation in the muscle.

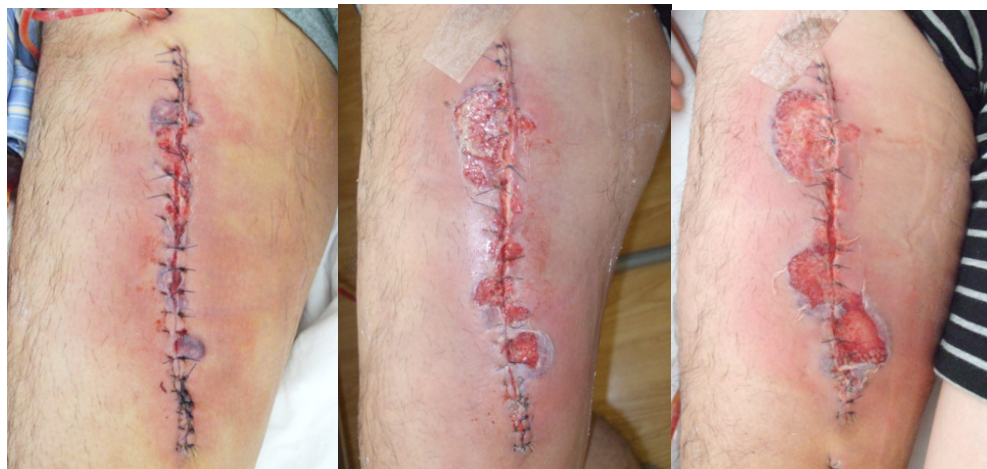

Figure 3: Photographs of the surgical wound. A: 3 days after tumor resection. B: 7 days after tumor resection. C: 7 days after tumor resection. The steady increase in the necrotic area.

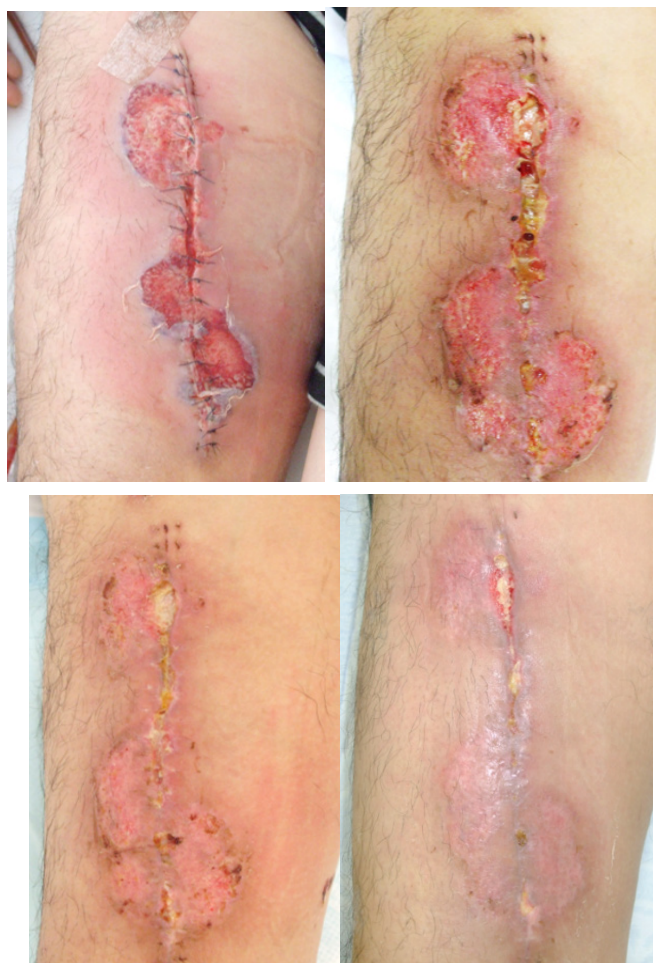


Figure 4: The changes in the necrotic ulcer after corticosteroid administration. A: 8 days after tumor resection, at the time of initiation of corticosteroid therapy. B: 7 days after corticosteroid administration. C: 10 days after corticosteroid administration. D: 16 days after corticosteroid administration.

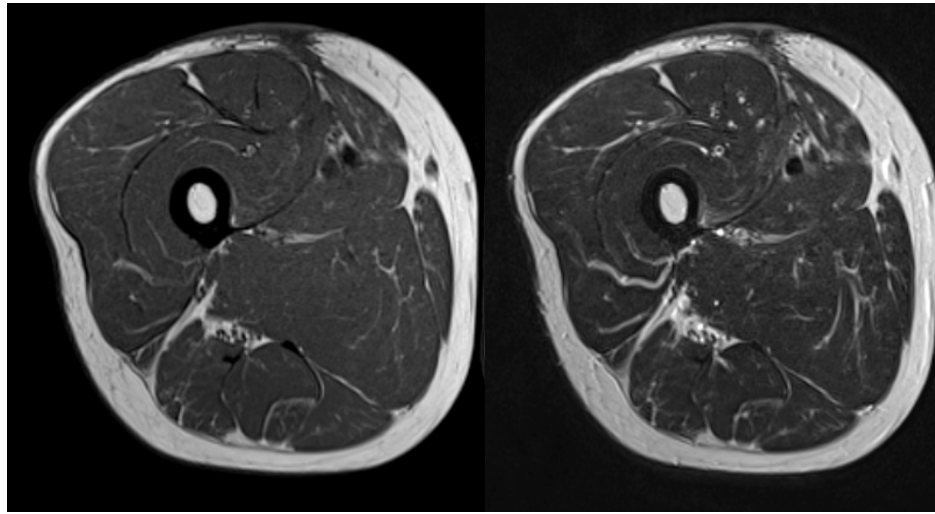


Figure 5: Magnetic resonance images, 3 months postoperatively. A: T1-weighted axial image. B: T2-weighted axial image. There are no signs of inflammation within the muscle.

Discussion

PG is an ulcerative, noninfectious, and neutrophilic skin disorder with an incidence of three to ten cases per million [1]. It is associated with systemic diseases such as inflammatory bowel disease and rheumatoid arthritis in up to 78% of the cases [2], and has a female predilection. Genetic mutations have also been reported as possible etiologies [3]. In our case, there were no serological findings suggestive of connective tissue disease, but the serum creatine kinase level was significantly elevated (500–4000 U/L). Rheumatologists screened the patient, but they could not confirm the diagnosis. Shah reported a case of scrotal PG associated with dermatomyositis; wherein the level of creatine kinase was approximately 500 U/L [4]. Although, our patient was not diagnosed with dermatomyositis, high activity of creatine kinase may be a risk factor for PG. Lower limbs are frequently affected by PG [5,6]. A recent literature review showed that thirty-five percent of patients were associated with postoperative PG, of which 12% were associated with orthopedic surgery [7]. A systematic review of autologous breast reconstruction reported that PG typically presented 5 days after the surgery [8]. In our case, the clinical signs appeared 3 days after the tumor resection. Timely diagnosis by a dermatologist is recommended before performing surgical debridement for a patient with early onset of painful ulcers at the surgical site.

In selected cases where PG is under control, removal of necrotic tissue is helpful to prevent bacterial infection [9].

Negative pressure wound therapy combined with systemic corticosteroid administration may be useful [6,10].

Su et al. reported rapid progression (margin expansion of 1 to 2 cm per day, or a 50% increase in ulcer size within 1 month) of a painful, necrotic ulcer with an irregular, violaceous, and undermined border as a major diagnostic criteria [11]. An enlarging painful skin ulcer refractory to antibiotic therapy could possibly represent PG [12].

In patients receiving immunosuppressive therapy, surgical debridement could prove beneficial in avoiding infection [9]; additionally, negative pressure therapy or skin grafting could be helpful [10,13,14].

A systemic immunosuppression by corticosteroids is the standard treatment, while cyclosporine therapy offers an effective substitute [1,8,13]. Usually, these treatments induce rapid clinical improvement within 24 hours (halting of progression and prevention of new lesion) [15]. In our case too, pain and redness were relieved within 24 hours after corticosteroid therapy. Postoperative PG is a rare pathology that frequently mimics surgical site infection. Although PG has been reported to occur after soft tissue tumor resection, but due to extensive defects resulting from the wide resection of bone and soft tissue sarcomas, the infection rate is very high and diagnosis of PG is important. Therefore, it is better to carefully evaluate its presence before performing surgical debridement.

Declaration of Competing Interest

The authors declare that they have no conflict of interest.

References

1. Ruocco E, Sangiuliano S, Gravina AG, Miranda A, Nicoletti G (2009) Pyoderma gangrenosum: an updated review, *J Eur Acad Dermatol Venereol* 23: 1008-1017.
2. Powell FC, Schroeter AL, Su WP, Perry HO (1985) Pyoderma gangrenosum: a review of 86 patients, *Q J Med* 55: 173-186.
3. Braswell SF, Kostopoulos TC, Ortega-Loayza AG (2015) Pathophysiology of pyoderma gangrenosum (PG): an updated review, *J Am Acad Dermatol* 73: 691-698.
4. Shah M, Lewis FM, Harrington CI (1996) Scrotal pyoderma gangrenosum associated with dermatomyositis, *Clin Exp Dermatol* 21: 151-153.
5. Wollina U (2007) Pyoderma gangrenosum--a review, *Orphanet J Rare Dis* 2: 19.
6. Ebrad S, Severyns M, Benzakour A, Roze B, Derancourt C, et al. (2017) Pyoderma gangrenosum after orthopaedic or traumatologic surgery: a systematic revue of the literature, *Int Orthop*. 42: 239-245.
7. Zuo KJ, Fung E, Tredget EE, Lin AN (2015) A systematic review of post-surgical pyoderma gangrenosum: identification of risk factors and proposed management strategy, *J Plast Reconstr Aesthet Surg* 68: 295-303.
8. Zelones JT, Nigriny JF (2017) Pyoderma Gangrenosum after Deep Inferior Epigastric Perforator Breast Reconstruction: Systematic Review and Case Report, *Plast Reconstr Surg Glob Open* 5: e1239.
9. Reichrath J, Bens G, Bonowitz A, Tilgen W (2005) Treatment recommendations for pyoderma gangrenosum: an evidence-based review of the literature based on more than 350 patients, *J Am Acad Dermatol* 53: 273-283.
10. Tanini S, Calugi G, Russo GL (2017) Combination of negative pressure wound therapy and systemic steroid therapy in postsurgical pyoderma gangrenosum after reduction mammoplasty; a case of proven efficacy and safety, *Dermatol Reports* 9: 7209.
11. Su WP, Davis MD, Weenig RH, Powell FC, Perry HO (2004) Pyoderma gangrenosum: clinicopathologic correlation and proposed diagnostic criteria, *Int J Dermatol* 43: 790-800.
12. Armstrong PM, Ilyas I, Pandey R, Berendt AR, Conlon CP, Simpson AH (1999) Pyoderma gangrenosum. A diagnosis not to be missed, *J Bone Joint Surg Br* 81: 893-894.
13. Pichler M, Thuile T, Gatscher B, Tappeiner L, Deluca J, Larcher L, et al. (2017) Systematic review of surgical treatment of pyoderma gangrenosum with negative pressure wound therapy or skin grafting, *J Eur Acad Dermatol Venereol* 31: e61-e67.
14. Niezgoda JA, Cabigas EB, Allen HK, Simanonok JP, Kindwall EPJ. (2006) Krumenauer, Managing pyoderma gangrenosum: a synergistic approach combining surgical debridement, vacuum-assisted closure, and hyperbaric oxygen therapy, *Plast Reconstr Surg* 117: 24e-28e.
15. Chow RK, Ho VC (1996) Treatment of pyoderma gangrenosum, *J Am Acad Dermatol* 34: 1047-1060.