



## Pneumopericardium after Transbronchial Lung Cryobiopsy in a Patient with Interstitial Lung Disease

Vicente Espinosa<sup>1\*</sup>, Sandor Györik<sup>1</sup>, Carla Puligheddu<sup>2</sup>, Stefano Cafarotti<sup>3</sup>, Maurizio Bernasconi<sup>1</sup>

<sup>1</sup>Division of Pulmonology, Ente Ospedaliero Cantonale, Bellinzona, Switzerland

<sup>2</sup>Department of Radiology, San Giovanni Hospital, Bellinzona, Switzerland

<sup>3</sup>Department of Thoracic Surgery, San Giovanni Hospital, Bellinzona, Switzerland

\***Corresponding author:** Vicente Espinosa, Division of Pulmonology, Ente Ospedaliero Cantonale, Bellinzona, Switzerland

**Citation:** Espinosa V, Györik S, Bernasconi M, Puligheddu C, Cafarotti S (2021) Pneumopericardium after Transbronchial Lung Cryobiopsy in a Patient with Interstitial Lung Disease. Ann Case Report 6: 615. DOI: 10.29011/2574-7754.100615

**Received Date:** 18 January, 2021; **Accepted Date:** 23 January, 2021; **Published Date:** 28 January, 2021

### Abstract

Transbronchial cryobiopsy is a technique used for the histological diagnosis of interstitial lung disease that cannot be classified on the basis of clinical and radiological grounds alone. The main complications of this procedure include bronchial hemorrhage and pneumothorax. We report the case of a rare complication of pneumopericardium following transbronchial cryobiopsy in a patient with suspected idiopathic pulmonary fibrosis.

**Keywords:** Lung cryobiopsy; Pneumopericardium; IPF

**Abbreviations:** CXR: Chest X-Ray; ILD: Interstitial Lung Disease; IPF: Idiopathic Pulmonary Fibrosis; 6MWT: 6 Minute Walking Test; PFT: Pulmonary Function Test; R-CHOP: Chemotherapeutic Regimen Containing Rituximab, Cyclophosphamide, Hydroxydaunorubicin, Oncovin, Prednisone; SLB: Surgical Lung Biopsy; TBLB: Transbronchial Biopsy; c-TBLB: Transbronchial Lung Cryobiopsy; UIP: Usual Interstitial Pneumonia

### Introduction

Transbronchial lung cryobiopsy (c-TBLB) is a technique that has emerged as an alternative to surgical lung biopsy in the diagnosis of interstitial lung diseases (ILD) of unclear etiology. c-TBLB makes it possible to obtain samples of 40–50 mm<sup>2</sup> in size containing peripheral structures of the secondary pulmonary lobules. Specimen size is thus significantly larger compared to forceps transbronchial biopsy (TBB) and has the advantage of overcoming the issue of compression artifacts frequently seen with the latter technique. The histopathological and multidisciplinary discussion-based diagnostic yield is high, ranging from 72 to 98%, [1,2] a value similar to that reported for surgical lung biopsy (SLB) [3]. Lower morbidity and mortality, even in patients with severely impaired lung function, make this technique a promising alternative to SLB. A meta-analysis showed a 2.1% mortality at 30 days after

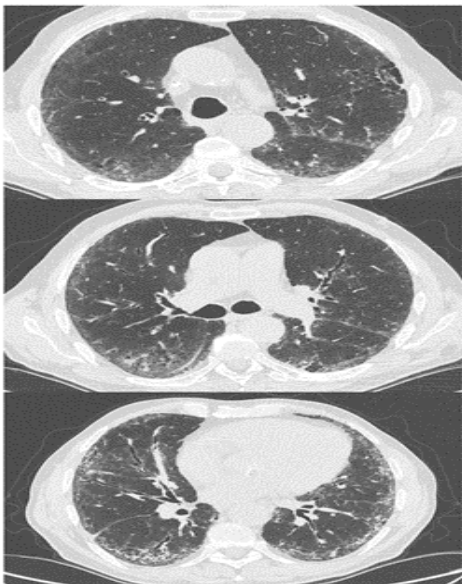
SLB [4] compared to 0.3% after c-TBLB [5], a difference mainly related to the higher incidence of acute exacerbation of pre-existing ILD after SLB. Furthermore, c-TBLB can often be performed with an overnight hospital stay, even in patients with severely impaired lung function in whom SLB would not be considered.

Albeit less invasive than SLB, some complications inherent to c-TBLB have been described, namely bronchial haemorrhage and pneumothorax. Although pneumomediastinum has rarely been reported as a complication of c-TBLB, pneumopericardium has, to our knowledge, not been described in the literature. We report the case of a pneumopericardium following c-TBLB.

### Case report

A 75-year-old man with a history of testicular lymphoma with lymphonodal metastasis treated with R-CHOP was evaluated for progressive dyspnea that arose in the preceding 6 months and presence of interstitial changes on chest radiography. The lymphoma was considered to be in complete remission at the moment of evaluation. Pulmonary function tests showed a restrictive pattern (FEV1 1.9L (70% pred.), FVC 2.6L (71% pred.), FEV1/FVC 0.75, DLCOc 44% pred.) and a significant desaturation during the 6 minute walking test (6MWT) was reported. High resolution CT showed subpleural reticular abnormalities, fibrosis with basal predominance, traction bronchiectasis and bronchiolectasis in the absence of honeycombing or features listed as “alternative diagnosis to idiopathic pulmonary fibrosis (IPF)” (Figure 1) and

was thus interpreted as a probable usual interstitial pneumonia (UIP) pattern according to current guidelines.



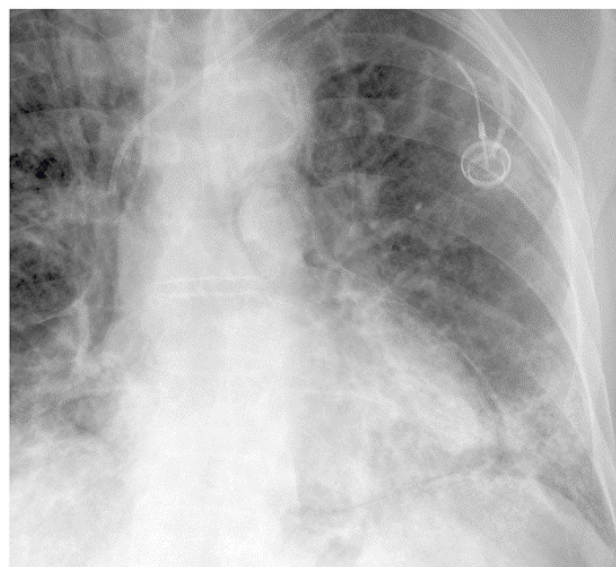
**Figure 1:** High resolution chest CT of the patient showing subpleural reticulation, traction bronchiectasis, and fibrosis with basal predominance.

A total of five transbronchial lung cryobiopsies was performed in the left lower lobe in the anterobasal (segment 8) and laterobasal (segment 9) segments applying the technique previously described in the literature [6]. After intubation with a rigid bronchoscope and placement of a hemostatic balloon in the left lower lobe bronchus, the cryoprobe (1.9 mm diameter, Erbe Elektromedizin GmbH, 72072 Tübingen, Deutschland) was advanced into the target segment up to the parietal pleura and retracted about 10mm under fluoroscopic guidance. Applied freezing time was between 5 and 7 seconds. The general anaesthesia and post interventional period were uneventful, without any symptoms reported or alteration of vital signs. However, the chest X ray (CXR) 4 hours after the procedure showed a pneumopericardium and possibly a small pneumomediastinum (Figure 2). After an uneventful monitoring of 24h, the CXR showed complete resolution of both of these features. Histopathological results showed dense fibrosis with destruction of the alveolar architecture and fibroblastic foci. Idiopathic pulmonary fibrosis (IPF) was the retained diagnosis after multidisciplinary team meeting and an antifibrotic drug was initiated.

## Discussion

This is the first report of iatrogenic pneumopericardium after c-TBLB. Pneumothorax, with a reported incidence of 20%, and

bleeding, are the most frequent reported complications of c-TBLBs [5]. Pneumomediastinum has also been reported after c-TBLBs even without pleural tissue recognized on the collected specimens [7]. This is most likely related to the three-step pathophysiological sequence of traumatic alveolar rupture, air dissection along bronchovascular sheaths, and spreading of this blunt pulmonary interstitial emphysema into the mediastinum (known as the Macklin effect) [8]. This process is most likely furthermore enhanced by the positive pressure ventilation applied during the procedure. Although exceedingly rare, pneumopericardium has been described as a consequence to penetrating or blunt thoracic trauma and to positive pressure ventilation [9]. Iatrogenic pneumomediastinum and pneumopericardium in the setting of pulmonary diagnostic procedure are generally self-limited and resolve spontaneously with the end of positive pressure ventilation.



**Figure 2:** Post c-TBLB chest radiography of the patient showing pneumopericardium.

This case report illustrates an infrequent, most likely benign, but relevant complication of c-TBLB which suggests that performing c-TBLB in segments close to the heart should be avoided if possible and that ventilation should be applied with low plateau pressures. The possible protective value of high frequency jet ventilation (HFJV) in this context warrants further investigation.

## Declaration of competing interest

The authors whose names are listed immediately below certify that they have NO affiliations with or involvement in any organization or entity with any financial interest or non-financial interest in the subject matter or materials discussed in the manuscript titled “Pneumopericardium after transbronchial lung cryobiopsy in a patient with interstitial lung disease”.

## References

1. Hernández-González F, Lucena CM, Ramírez J, Sánchez M, Jimenez MJ, Xaubet A, et al. (2015) Cryobiopsy in the diagnosis of diffuse interstitial lung disease: yield and cost-effectiveness analysis. *Arch Bronconeumol* 51: 261-267.
2. Johannson KA, Marcoux VS, Ronksley PE, Ryerson CJ (2016) Diagnostic Yield and Complications of Transbronchial Lung Cryobiopsy for Interstitial Lung Disease. A Systematic Review and Metaanalysis. *Ann Am Thorac Soc* 13: 1828-1838.
3. Tomassetti S, Wells AU, Costabel U, Cavazza A, Colby TV, Rossi G, et al. (2016) Bronchoscopic Lung Cryobiopsy Increases Diagnostic Confidence in the Multidisciplinary Diagnosis of Idiopathic Pulmonary Fibrosis. *Am J Respir Crit Care Med* 193: 745-752.
4. Nguyen W, Meyer KC (2013) Surgical lung biopsy for the diagnosis of interstitial lung disease: a review of the literature and recommendations for optimizing safety and efficacy. *Sarcoidosis Vasc Diffuse Lung Dis* 30: 3-16.
5. Ravaglia C, Bonifazi M, Wells AU, Tomassetti S, Gurioli C, Piciocchi S, et al. (2016) Safety and Diagnostic Yield of Transbronchial Lung Cryobiopsy in Diffuse Parenchymal Lung Diseases: A Comparative Study versus Video-Assisted Thoracoscopic Lung Biopsy and a Systematic Review of the Literature. *Respiration* 91: 215-227.
6. Hetzel J, Eberhardt R, Herth FJF, Petermann C, Reichle G, Freitag L, et al. (2012) Cryobiopsy increases the diagnostic yield of endobronchial biopsy: a multicentre trial. *Eur Respir J* 39: 685-690.
7. Barisione E, Bianchi R, Fiocca R, Salio M (2018) Pneumomediastinum after transbronchial cryobiopsy. *Monaldi Arch Chest Dis* 88: 909.
8. Wintermark M, Schnyder P (2001) The Macklin effect: a frequent etiology for pneumomediastinum in severe blunt chest trauma. *Chest* 120: 543-547.
9. Bhakta P, McNamara JR, O'Brien B, Plant R (2018) Isolated pneumopericardium caused by positive pressure ventilation: A rare complication. *J Clin Anesth* 49: 5-6.