



Case Report

Comparative Values of B-Mode Ultrasound and Contrast-Enhanced Ultrasonography in Diagnosing Ovarian Torsion in Children

Florian Laclergerie¹, Sandrine Chapuy², Philippe Manzoni², Nicolas Mottet^{3,4}, Marion Lenoir², Frédéric Auber^{1,4}, Taieb Chouikh¹, Eric Delabrousse^{2,4}, Yann Chaussy^{1,4*}

¹Department of pediatric surgery, CHU Besançon, Besançon, France

²Department of radiology, CHU Besançon, Besançon, France

³Department of gynaecology and obstetrics, CHU Besançon, Besançon, France

⁴Nanomédecine, Imagerie, Thérapeutique EA 4662, Université Bourgogne Franche-Comté, Besançon, France

***Corresponding author:** Yann Chaussy, Service de Chirurgie Pédiatrique, CHRU Besançon, 3 Boulevard Fleming, 25030, Besançon Cedex, France. Tel: +33-381219333; Email: yannchaussy@hotmail.com

Citation: Laclergerie F, Chapuy S, Manzoni P, Mottet N, Lenoir M, et al. (2020) Comparative Values of B-Mode Ultrasound and Contrast-Enhanced Ultrasonography in Diagnosing Ovarian Torsion in Children. Ann Case Report 14: 565. DOI: 10.29011/2574-7754/100565

Received Date: 23 October, 2020; **Accepted Date:** 11 November, 2020; **Published Date:** 16 November, 2020

Abstract

Aim: To compare the results of B-Mode ultrasound and contrast-enhanced ultrasonography for the diagnosis of ovarian torsion in children.

Methods: We conducted a retrospective clinical study. Patients under 18 years old referred in emergency with a suspected diagnosis of ovarian torsion and who had undergone both B-Mode ultrasound and contrast-enhanced ultrasonography were included in the study. Data including age, previous medical history, duration of symptoms, physical and radiological findings, surgical findings and final diagnosis were collected.

Results: Between 2007 and 2015, 18 contrast-enhanced ultrasonographies in 17 patients were analyzed and included in our study. Mean age of patients was 11.5 ± 3.6 years. Thirteen patients (72.2%) underwent surgery. Among them, we found ovarian torsion in seven patients (53.8%) and an ovarian lesion without torsion in six (46.2%).

Sensitivity and specificity were respectively 42.9% and 81.8% for B-Mode ultrasound and 100% and 81.8% for contrast-enhanced ultrasonography. Positive and negative predictive values were respectively 60% and 69.2% for B-Mode ultrasound and 77.8% and 100% for contrast-enhanced ultrasonography. Efficiency was 66.7% for B-Mode ultrasound and 88.9% for contrast-enhanced ultrasonography. Positive likelihood ratios were respectively 2.4 and 5.5 for B-Mode ultrasound and contrast-enhanced ultrasonography.

Conclusion: Contrast-enhanced ultrasonography seems to be useful in the early diagnosis of ovarian torsion in children by providing arguments to rule it out and to defer surgery.

Keywords: Children; Contrast-enhanced ultrasonography; Ovarian torsion

Introduction

Acute abdominal pain is a common symptom in the pediatric population, accounting for approximately 10% of all children seen in the emergency unit [1]. It is often associated with other symp-

toms like fever and vomiting [2]. Ovarian torsion is a rare cause of abdominal pain in children but it can lead to the loss of the gonad in case of late diagnosis. Recognized risk factors are the presence of an ovarian mass larger than five centimeters, an ovarian hyperstimulation or pregnancy [3]. Between one and 20 years of age, the incidence of ovarian torsion is five cases for 100 000 girls [4]. It accounts for 2.7% of acute abdominal pain in adult women [5].

The most common sign is the sudden onset of severe, constant, unilateral pain in the lower abdomen or pelvic area, occasionally associated with nausea, vomiting, elevated white blood cell count or fever [2]. These signs are not specific and it is difficult to make a definitive diagnosis with only a physical examination. However, this disease is a real surgical emergency that requires fast diagnosis and surgery to avoid irreversible gonadal damages. Therefore, imaging studies are necessary to confirm or refute the diagnosis of ovarian torsion, but published data are contradictory regarding the predictive value of different imaging modalities [6]. Indeed, it has been shown that it took almost three times as long to transfer a girl with ovarian torsion to the operating room after the onset of pain as compared to a boy with testicular torsion. As a result, the gonad was salvaged in only 14% of the affected girls versus 30% of the boys [7].

Intravenous injection of echogenic contrast agent is likely to improve the predictive value of ultrasound for certain diagnoses. Although Contrast-Enhanced Ultrasonography (CEUS) has already been recommended in the characterization of ovarian tumors [8,9], there is no study assessing the contribution of CEUS in the diagnosis of ovarian torsion in children. However, a study using a canine animal model has demonstrated the value of this imaging technique in diagnosing ovarian torsion [10]. Our objective was to compare the results of B-Mode ultrasound and contrast-enhanced ultrasonography in diagnosing ovarian torsion in children.

Methods

We conducted a retrospective clinical study in the pediatric surgery and gynecology units of our university hospital at Besançon, Bourgogne Franche-Comté, France. Patients under 18 years old referred in emergency with a suspected diagnosis of ovarian torsion and who had undergone both B-Mode ultrasound and CEUS were included in the study. Patients were identified through the registry of the pediatric radiology unit that prospectively records all CEUS performed since December 2003. Charts of included patients were retrospectively reviewed to collect relevant demographic data (age, medical and surgical history, current pregnancy), symptom duration, physical examination, radiological assessment (color Doppler ultrasound, CEUS, abdominopelvic computed tomography), treatment and final diagnosis. The surgeon ascertained the final diagnosis during the surgical procedure for operated patients (presence or absence

of ovarian torsion). For non-operated patients, the final diagnosis was determined by the clinical and ultrasound-scan examination performed one month after their initial medical referral.

B-Mode ultrasounds and CEUS were performed using the Aixplorer ultrasound system (SuperSonic Imagine, Aix-en-Provence) with a 10-2 MHz linear probe and a 6-1 MHz convex probe from June 2014 to the present and the Acuson-Sequoia ultrasound system (Siemens Medical Solutions USA, Inc; Mountain View, CA) with a 9L4 linear array and a 4C1 or 62C curved array transducers from October 2007 to June 2014. All color Doppler ultrasounds and CEUS were reviewed by three radiologists with a high level of expertise in these imaging techniques. In order to standardize the reading of the ultrasound pictures, morphological grid criteria of ovarian torsion were used (Table 1). The final outcome was blinded during this review. The diagnosis determined by ultrasound examination (B-mode or CEUS) after reviewing was binary: twisted ovary or untwisted ovary. Sonography was exclusively performed by abdominal approach, because the vaginal route is not recommended for ultrasound assessment in children. The contrast agent used was SonoVue® (Bracco, Milan, Italy) administrated intravenously. One ml of SonoVue® contains eight µl of sulfur hexafluoride, an inert gas, sparingly soluble in aqueous solutions. Adding sodium chloride to the powder of freeze-dried SonoVue®, followed by vigorous stirring, causes the appearance of microbubbles of sulfur hexafluoride with a diameter of approximately two and a half µm. The interface between the sulfur hexafluoride microbubbles and the aqueous media acts as a reflector of the ultrasound beam, thereby improving the echogenicity of the blood and increasing the contrast between bloods, and surrounding tissues. After injection, sulfur hexafluoride dissolves in the blood. The elimination half-life is 12 minutes, and almost 100% of sulfur hexafluoride is recovered in expired air 15 minutes after injection. This product does not have marketing authorization in pediatrics, so an informed consent sheet was systematically issued and signed by the guardian before imaging was carried out. Institutional review board approval is not required for retrospective chart-review studies in France. Written informed consent was obtained from the parents or legal guardians before each surgical procedure. SonoVue® is a second-generation contrast agent able to respond to ultrasound insonation with harmonic signals at low acoustic pressure. It has been tested worldwide in more than 100 000 patients and is considered to be safe [11].

Patient (number)	B-mode US + doppler	CEUS
Ovary		
Side		
Diameter (mm)		
Cyst (mm)		
Mass (mm)		
Whirl Sign	Y/N	Y/N
Follicles around the periphery	Y/N	Y/N
Free Fluid	Y/N	Y/N
Anormal venous blood flow	Y/N	Y/N
Anormal arterial blood flow	Y/N	Y/N
Delay of contrast enhancement	Y/N	Y/N
Diagnosis		
Ovarian torsion	Y/N	Y/N
Other diagnosis		

Table 1: Morphological grid criteria for ovarian torsion diagnosis (Y: Yes, N: No).

In our study, the dose of the contrast agent was calculated based on the patient's age and weight (usually two or three injections of 1.5 ml for patients from 6 months to 6 years, two injections of 2ml between 6 and 12 years and two injections of 2.4 ml for patients over 12 years old). The contrast agent injection was followed by a saline injection (maximum 10 ml). Children remained under medical supervision for 30 minutes after this administration.

Statistical Analysis

Demographic, clinical and radiological variables were described using means and standard deviations for continuous variables and percentages for qualitative variables. All analyses were performed using IBM® SPSS® Statistics version 20.

Results

Between October 2007 and August 2015, 19 contrast-enhanced ultrasonographies in 18 patients were performed for acute abdominal pain and suspicion of ovarian pathology. One patient was excluded from the analysis because of the absence of follow-up. Finally, 18 contrast-enhanced ultrasonographies in 17 patients were analyzed and included in our study. One patient developed ovarian torsion recurrence two years after a laparoscopic ovarian

detorsion associated with an oophoropexy. Mean and median age of patients was 11.5 ± 3.6 years and 12.5 years respectively. Their mean weight was 42.2 ± 16.9 kg. No patient was pregnant during the study. Among patients referred to the emergency unit for acute abdominal pain and suspected ovarian pathology, 10 (55.6%) presented right iliac fossa pain, five (27.9%) left iliac fossa, four (22.2%) pelvic pain and one (5.6%) peri-umbilical pain. Thirteen patients (72.2%) had pain less than 72 hours, 3 patients (16.7%) less than a week, 1 (5.6 %) less than a month. The remaining patient (5.6%) had intermittent pain for one year with chronic constipation. Initially, 9 children (50%) had vomiting and 5 (27.8%) had fever. Physical examination essentially revealed abdominal tenderness (14 cases; 77.8%), more rarely abdominal guarding (4 cases; 22.2%). An abdominal mass was palpated in only 2 cases (11.1%) (Table 2).

Demographic variables (n=18)	
Mean age (years)	11.5 ± 3.6
Mean weight (kg)	42.2 ± 16.9
Physical examination	
Acute abdominal pain (<72h)	13 (72.2%)
No pain	0 (0%)
Location of pain	
Right iliac fossa	10 (55.6%)
Left iliac fossa	5 (27.8%)
Pelvic	4 (22.2%)
Peri-ombilical	1 (5.6%)
Palpation	
Abdominal mass	2 (11.1%)
Tenderness	14 (77.8%)
Guarding	4 (22.2%)
Contracture	0 (0%)
Vomiting	9 (50%)
Fever	5 (27.8%)

Table 2: Demographic and clinical data.

B-mode ultrasound was performed in all patients. The pathological ovary was left-sided in 9 cases (50%). Its mean diameter was 58.4 ± 29.5 mm. An ipsilateral cyst was identified in 9 cases (50%) and an ovarian mass in 4 cases (22.2%) with a mean lesion diameter of 45.8 ± 38.6 mm. A twisted vascular pedicle was described in 3 cases (16.7%), the presence of follicles positioned around the periphery of the ovary in 5 cases (27.8%) and pelvic fluid in 9 cases (50%). Only 6 color Doppler analyses (33.3%) were found and retrospectively analyzable: two (33.3%) found an

absence of vascular flow, three (50%) a minimal vascular flow, and only one (16.7%) was normal (Table 3).

B-mode ultrasound (n=18)	
Side	
Left-sided	9 (50%)
Right-sided	9 (50%)
Mean pathological ovary diameter (mm)	58.4 ± 29.5
Ovarian lesion	
cyst	9 (50%)
mass	4 (22.2%)
Mean lesion diameter (mm)	45.8 ± 38.6
Pelvic fluid	9 (50%)
Whirl sign	3 (16.7%)
Follicles around the periphery	5 (27.8%)
Doppler ultrasound (n=6)	
Venous flow	
Absent	2 (33.3%)
Minimal	3 (50%)
Normal	1 (16.7%)
Arterial flow	
Absent	2 (33.3%)
Minimal	3 (50%)
Normal	1 (16.7%)
Contrast enhanced ultrasonography (CEUS) : contrast enhancement (n=18)	
Venous time	
Absent	5 (27.8%)
Delayed	5 (27.8%)
Normal	8 (44.4%)
Arterial time	
Absent	5 (27.8%)
Delayed	5 (27.8%)
Normal	8 (44.4%)
Washout time	
Absent	5 (27.8%)
Delayed	5 (27.8%)
Normal	8 (44.4%)

Table 3: B-mode ultrasound, Doppler ultrasound and contrast enhanced ultrasonography results.

CEUS analysis was performed in all cases. Five exams (27.8%) showed an absence of contrast enhancement in the arterial, venous and washout times, five (27.8%) a delay of contrast enhancement, while eight exams (44.4 %) were normal. A twisted vascular pedicle was found in 4 cases (22.2%) (Table 3). Abdominopelvic Computed Tomography (CT) with administration of intravenous contrast was performed (before referral to our hospital center) in only one case (5.6%). It failed to show an ovarian torsion. Surgical exploration was decided in 13 cases (72.2%), 10 (76.9%) by laparoscopy and three (23.1%) by laparotomy (Table 4). The surgical exploration assessed the diagnosis of ovarian torsion in seven patients (53.8%) and ovarian lesion without torsion in six (46.2%).

Type	
Surgical	13 (72.2%)
Medical	5 (27.8%)
Surgery	
Laparoscopy	10 (76.9%)
Laparotomy	3 (23.1%)
Per-operative observation	
No torsion	6 (46%)
Torsion	7 (54%)
With necrosis	3 (23.1%)
Procedure	
Detorsion	5 (38.5%)
Cystectomy	5 (38.5%)
Detorsion + cystectomy	1 (7.7%)
Adnexectomy	2 (15.4%)
Mean follow-up of non-operated patients (month)	
	1

Table 4: Management of patients.

In the ovarian torsion group, 3 ovaries were necrotic (23.1% of operated patients), and 4 presented a twisted vascular pedicle without necrosis (30.8% of operated patients). The procedure performed in this group was detorsion of the twisted ovary in five patients (38.5%), detorsion of the twisted ovary associated with cystectomy in one (7.7%), and adnexectomy in one (7.7%). In the no-torsion group, the procedure performed was cystectomy in five (38.5%), and adnexectomy in one (7.7%) because of a large ovarian tumor with no normal tissue identified. Eight samples (six cysts and two ovaries) were sent to a pathologist. None showed histological criteria of malignancy, and the large tumor was found to be a mature cystic teratoma (dermoid cyst). Five patients did not undergo surgery. All were evaluated clinically and radiologically one month later with no argument in favor of an ovarian torsion.

Ultrasound conclusions were compared to the final diagnosis observed during surgery or at the last follow-up for non-operated patients (Table 5). B-Mode ultrasound identified an ovarian torsion

in 5 cases (27.8%) and the absence of torsion in 13 cases (72.2%). The distribution of True Positive (TP), True Negative (TN), false positive (FP) and False Negative (FN) for B-Mode ultrasound was respectively 3 TP, 9 TN, 2 FP and 4 FN. CEUS identified an ovarian torsion in 9 cases (50%) and the absence of torsion in 9 cases (50%). The distribution of TP, TN, FP and FN for CEUS was respectively 7 TP, 9 TN, 2 FP and 0 FN. A comparison of imaging results and final diagnoses are presented in (Table 6). Sensitivity and specificity were respectively 42.9% and 81.8% for B-Mode ultrasound and 100% and 81.8% for CEUS. Positive and negative predictive values were respectively 60% and 69.2% for B-Mode ultrasound and 77.8% and 100% for CEUS. Efficiency was 66.7% for B-Mode ultrasound and 88.9% for CEUS. Positive likelihood ratios were respectively 2.4 and 5.5 for B-Mode ultrasound and CEUS.

Patients	B-Mode results	CEUS results	Final diagnosis
1	Torsion	Torsion	Absence of torsion (S)
2	Torsion	Torsion	Torsion (S)
3	Absence of torsion	Torsion	Torsion (S)
4	Torsion	Torsion	Torsion (S)
5	Torsion	Torsion	Torsion (S)
6	Absence of torsion	Torsion	Absence of torsion (S)
7	Absence of torsion	Torsion	Torsion (S)
8	Absence of torsion	Torsion	Torsion (S)
9	Absence of torsion	Absence of torsion	Absence of torsion (O)
10	Torsion	Absence of torsion	Absence of torsion (S)
11	Absence of torsion	Absence of torsion	Absence of torsion (O)
12	Absence of torsion	Absence of torsion	Absence of torsion (S)
13	Absence of torsion	Absence of torsion	Absence of torsion (O)
14	Absence of torsion	Absence of torsion	Absence of torsion (S)
15	Absence of torsion	Absence of torsion	Absence of torsion (S)
16	Absence of torsion	Absence of torsion	Absence of torsion (O)
17	Absence of torsion	Absence of torsion	Absence of torsion (O)
18	Absence of torsion	Torsion	Torsion (S)

Table 5: comparison of ultrasound examinations and final diagnoses (S: surgically confirmed, O: confirmed by observation).

	B-mode ultrasound	CEUS
True Positive	3	7
False Positive	2	2
True Negative	9	9
False Negative	4	0
Sensitivity	42.90%	100%
Specificity	81.80%	81.80%
Positive Predictive Value	60%	77.80%
Negative Predictive Value	69.20%	100%
Efficiency	66.7%	88.90%

Table 6: comparison of B-mode and CEUS results.

Discussion

To our knowledge, this is the first study evaluating the comparative values of B-Mode ultrasound and CEUS in the diagnosis of ovarian torsion in children. In our study, B-Mode ultrasound and CEUS had respectively a sensitivity of 42.9% and 100%, a specificity of 81.8% for both, a positive predictive value of 60% and 77.8%, and a negative predictive value of 69.2% and 100%. Therefore, CEUS seems to be a useful tool in ruling out a suspected diagnosis of ovarian torsion in children. We illustrate these findings with 2 figures. The (Figure 1) presents an ovarian torsion with a twisted vascular pedicle which is particularly highlighted on CEUS. On (Figure 2), CEUS demonstrates an absence of ovarian torsion with haemorrhagic cyst: there is no enhancement of the heterogeneous cyst and normal enhancement of the surrounding healthy ovarian tissue.

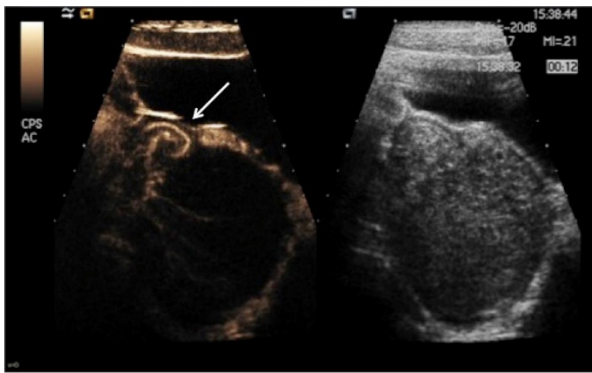


Figure 1: CEUS and B-Mode ultrasound: ovarian torsion with twisted vascular pedicle (arrow), enlarged ovary and abnormal enhancement of the ovarian parenchyma.

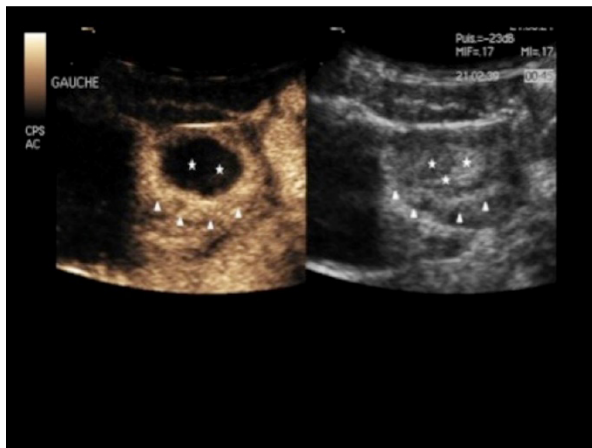


Figure 2: CEUS and B-Mode ultrasound: absence of ovarian torsion and haemorrhagic cyst: no enhancement of the heterogeneous haemorrhagic cyst (asterisk) and normal enhancement of the surrounding healthy ovarian tissue (triangles).

Despite the development of imaging techniques, diagnosing ovarian torsions still remains difficult with a potential risk of losing the affected gonad. Acute abdominal pain is a common reason to go directly to the hospital emergency unit, especially in the case of children [12]. The presence of nonspecific symptoms can delay the initial diagnosis. Piper, et al. have demonstrated that it took almost three times as long to transfer a girl with ovarian torsion to the operating room after the onset of pain as compared to a boy with testicular torsion. Consequently, the gonad was salvaged in only 14% of the affected girls versus 30% in boys [7]. In a recent meta-analysis, Bronstein, et al. reported variability regarding the sensitivity and specificity of different imaging modalities used for diagnosing ovarian torsion [6]. Indeed, morphological criteria given by the B-Mode ultrasound respectively brought an average sensitivity and specificity of 92% and 96%. The color Doppler was moderately specific but lacked sensitivity (87% and 55%

respectively). Finally, the scanner was the least sensitive test (42%). So they concluded that B-Mode ultrasound associated with color Doppler should be performed in any child suspected of having an ovarian torsion [6].

B-Mode ultrasound can assess several interesting elements such as ovarian size compared to the contralateral gonad, presence of a mass or cyst, existence of pelvic fluid or a twist of the ovarian vascular pedicle and follicles positioned around the periphery of the ovary [3]. In a series of 328 pediatric age patients operated for ovarian torsion, the sensitivity of ultrasound was 51% versus 42.9% in our study. The presence of an asymmetric ovarian enlargement greater than five centimeters, frequently due to an underlying mass, was the element that provided the best sensitivity for positive diagnosis [13]. In our series, 6 patients (33.3%) had an ovarian lesion greater than five centimeters and among them, 4 (24%) had an ovarian torsion. Valsky, et al. have demonstrated that the presence of a twisted ovarian pedicle, or “Whirl Sign”, significantly improves the rate of a true positive diagnosis [14]. In our study, this sign was found in 3 patients (16.7%) but only 2 presented a twisted ovarian pedicle confirmed during surgery.

The analysis of ovarian vascularization using color Doppler coupled with ultrasonography and appropriate clinical features can enhance the positive diagnosis of ovarian torsion. In their study including 664 color Doppler ultrasounds for acute abdominal pain in a pediatric population, Naiditch, et al. [15] respectively found sensitivity and specificity of 78.6% and 92.3% as well as positive and negative predictive values of 19% and 99.5%. In the subgroup of 113 patients operated with 21 false positives and 3 false negatives, sensitivity and specificity were respectively 78.6% and 78.8%, and positive and negative predictive values 34.4% and 96.3%. In their study of 323 adult women operated for highly suspected ovarian torsion and who underwent a transabdominal ultrasonography, Rostamzadeh, et al. [16] found respectively a sensitivity and a specificity of 72.1% and 99.6%. Positive and negative predictive values were respectively 96.9% and 95.9%. The absence of vascular flow was significantly associated with the presence of a complete twisted ovary. These differences in predictive values may be due to many causes: differences in diagnostic criteria from one study to another, but also differences in inclusion criteria because positive and negative predictive values depend on the prevalence of the disease studied in a given population. In our series, color Doppler analysis was available in only 6 cases (33.3%). Among the two exams that found an absence of arterial or venous vascular flow, one was associated with ovarian torsion. Among the three tests demonstrating a minimal vascular flow, two were associated with ovarian torsion. The diagnosis of ovarian torsion was based on clinical and radiological arguments. The absence of abnormality on color Doppler should not rule out this diagnosis. Indeed, some authors report a normal color Doppler analysis in 57 to 60% of cases of ovarian torsion surgically confirmed [17,18].

Computed tomography is frequently used in the United States to assess children presenting for abdominal and pelvic pain, especially when acute appendicitis is suspected [19]. In 2008, Sivit, et al. [20] estimated the number of CT exams performed every year in the American pediatric population at three million, representing approximately five to ten percent of all imaging exams performed in children. CT findings in ovarian torsion are broadly similar to the information provided by ultrasound [3]. In their retrospective study, Swenson, et al. [21] compared the sensitivity and specificity of ultrasonography and CT in diagnosing ovarian torsion in adult women, thanks to the interpretation of two radiologists. The authors did not find any significant difference in the contribution of ultrasounds on CT in the diagnosis management of ovarian torsion in adults. Only one CT with administration of a contrast agent was performed in our study and did not show an ovarian torsion. This interpretation was, in fact, a false negative because the patient had a twisted ovary surgically confirmed. Given the low number of adverse events reported after an intravenous injection of contrast agent in children [22], the main risk associated with CT scan is exposure to ionizing radiation. Therefore, ultrasonography must be the imaging modality of choice when an ovarian torsion is suspected in children. CT does not provide any further benefit and is associated with a higher risk because of ionizing radiation exposure. Indeed, children are more sensitive to radiation than adults and are more exposed to radiation-related cancers [23].

Magnetic resonance imaging (MRI) is not commonly used as a first-line imaging technique in suspected ovarian torsion in children but can be very helpful in the characterization of pelvic masses. Remnographic findings are similar to those reported for ultrasonography and CT without ionizing radiation exposure, and sensitivity in analyzing vascular flow is better [24]. However, obtaining an urgent MRI exam remains difficult in some hospital centers.

There are few studies on the use of contrast agents in ultrasonography in the pediatric population and none suggesting what their role should be in the management of ovarian torsions. This is probably explained by the fact that SonoVue® is given to children without marketing authorization. Piscaglia, et al. [25] confirmed the safety of SonoVue® in a retrospective adult study of 23 188 abdominal investigations with only 29 adverse events, including 27 nonserious. In this study, the overall rate of serious adverse events was 0.0086% (less than 1/10 000 patients), lower than that reported for other contrast media (0.09% to 0.25% for CT and 0.005% to 0.2% for MRI) and similar to that of some commonly used drugs such as analgesics or antibiotics (0.005% to 0.015%). Cases of using drugs in pediatrics without marketing authorization are frequent. In 2006, Autret-Leca, et al. [26] demonstrated that off label prescribing in pediatrics represented 94% of prescribed drugs in intensive care units, 67% in hospital and 30% of those prescribed in general practice. Authors recall

that off label prescriptions should be based on a supposed benefit, which would have to be justified if a severe side effect occurred. Kneiling, et al. [27] confirmed the tolerability and safety of CEUS in their retrospective study including 40 pediatric patients and young adults who received ultrasound contrast agents. Rosado, et al. [28] reported also the safety of SonoVue® in their analysis of existing literature regarding the off-label use of ultrasound contrast agents for intravenous applications in children. The use of SonoVue® has been approved by FDA for diagnostic liver imaging in children in the USA [29].

Laparoscopy is the gold standard for the diagnosis of acute pelvic pain in women and the detection of ovarian torsion [30]. It allows full exploration of the peritoneal cavity, localization of any associated lesions, assessment of the contralateral ovary, and an initial peritoneal cytological sample [31,32]. In our study, laparoscopy was performed in 10 patients (76.9%). In case of an incidental intraoperative discovery of an ovarian cystic lesion, cystectomy can be performed. However, in the acute phase of ovarian torsion, it may be technically difficult to identify the cleavage plane and evaluate criteria of benign cysts. Therefore, an untwisting could be carried out and the ovarian mass left in place before complementary assessment [33-35]. In our study, cystectomy was performed in 6 cases (46.2%), and no malignancy was found after pathological examination. During surgery for ovarian torsion, there is no established correlation between the intraoperative macroscopic appearance of the ovary before and after detorsion. Thus, a conservative approach after detorsion of black-bluish ovaries is safe and effective in children except in cases of advanced necrosis [36,37].

Any technological innovation in the medical field is likely to increase the cost of care for patients. In a French multicentric study, Tranquart, et al. [38] assessed the medical and economic impact of intravenous SonoVue® for characterizing hepatic nodular lesions as opposed to using CT or MRI. The main criterion of economic judgment was estimated from the amount of trading in the considered examination, contrast ultrasound, MRI or CT (including the technical package for these two exams). Both the cost of the contrast agent, and the injection procedure, were included in the total cost of each exam. The economic assessment is based on using an average amount of contrast agent, that to say one bottle per patient.

One limitation of our study is its retrospective nature including a selection bias since the patients included had to be underage, presenting abdominal pain, and have had a B-mode ultrasonography necessarily associated with a CEUS. Thus, antenatal diagnosis of torsion and young adults were excluded from the analysis. These inclusion criteria associated with recruitment in a specialized hospital unit inevitably imply a wide selection in our population. Therefore, positive and negative predictive values are affected because they vary depending on

the prevalence of the disease. There is also a bias of comparison because the gold standard for ovarian torsion diagnosis is surgical exploration with intraoperative findings of twisted vascular ovarian pedicle or ovarian necrosis. In our study, this surgical procedure was performed in only 13 cases (72.2%). However, it would seem unethical to perform surgery in patients for whom a positive diagnosis is very unlikely. For non-operated patients, the reference test was an ultrasound examination during the follow-up one month later. The ultrasound exams (B-mode and CEUS) are read and interpreted by three radiologists with a high level of expertise, using a standardized grid containing all relevant diagnostic criteria. However, the performance and interpretation of ultrasound is operator-dependent and may lead to inter-observer and intra-observer reproducibility variations. Only few cases of color Doppler analysis are described in our study because of the lack of data during the collection. Indeed, color Doppler analysis was probably performed before the realization of CEUS but images were not recorded and so not evaluable. Another bias is the fact that the decision to perform a CEUS depends on the choice of the sonographer performing the imaging study. In our study we included only patients who had undergone both types of ultrasound examinations. Therefore, the radiologist's decision may have been influenced by his own habits, because he's used to using certain techniques and feels more confident using them. Such biases are inherent to the retrospective nature of our study. A prospective randomized blind study including a larger number of patients would be necessary to assess the benefits of CEUS for the diagnosis of ovarian torsion in children. However, such a study would be difficult to carry out because of the low prevalence of ovarian torsion in children.

Contrast enhanced ultrasonography is useful in the early diagnosis of ovarian torsion in children due to its high negative predictive value. When CEUS is not in favor of ovarian torsion, it is possible to defer surgery pending the results of a more comprehensive diagnosis procedure. A prospective study is necessary to confirm these preliminary results.

Acknowledgements

We thank Pamela Albert for her assistance for the preparation of this manuscript. This research did not receive any specific grant from funding agencies in the public, commercial, or not-for-profit sectors.

Disclosure

No author has any potential conflict of interest.

References

1. Egan CJ, Aiken JJ, Rudolph CD (2011) Acute abdominal pain. In: Rudolph CD, Rudolph AM, Lister GE, First LR, Gershon AA (Editors). *Rudolph's Pediatrics* (22nd Edition). New York: The McGraw-Hill Companies.
2. Houry D, Abbott JT (2001) Ovarian torsion: a fifteen-year review. *Ann Emerg Med* 38: 156-159.
3. Lourenco AP, Swenson D, Tubbs RJ, Lazarus E (2014) Ovarian and tubal torsion: imaging findings on US, CT, and MRI. *Emerg Radiol* 21: 179-187.
4. Guthrie BD, Adler MD, Powell EC (2010) Incidence and trends of pediatric ovarian torsion hospitalizations in the United States, 2000-2006. *Pediatrics* 125: 532-538.
5. Hibbard LT (1985) Adnexal torsion. *Am J Obstet Gynecol* 152: 456-461.
6. Bronstein ME, Pandya S, Snyder CW, Shi Q, Muensterer OJ (2015) A meta-analysis of B-mode ultrasound, Doppler ultrasound, and computed tomography to diagnose pediatric ovarian torsion. *Eur J Pediatr Surg* 25: 82-86.
7. Piper HG, Oltmann SC, Xu L, Adusumilli S, Fischer AC (2012) Ovarian torsion: diagnosis of inclusion mandates earlier intervention. *J Pediatr Surg* 47: 2071-2076.
8. Sconfienza LM, Perrone N, Delnevo A, Lacelli F, Murolo C, et al. (2010) Diagnostic value of contrast-enhanced ultrasonography in the characterization of ovarian tumors. *J Ultrasound* 13: 9-15.
9. Veyer L, Marret H, Bleuzen A, Simon E, Body G, et al. (2010) Preoperative diagnosis of ovarian tumors using pelvic contrast-enhanced sonography. *J Ultrasound Med* 29: 1041-1049.
10. Brown JM, Taylor KJ, Alderman JL, Quedens-Case C, Greener Y (1997) Contrast-enhanced ultrasonographic visualization of gonadal torsion. *J Ultrasound Med* 16: 309-316.
11. Testa AC, Timmerman D, Exacoustos C, Fruscella E, Van Holsbeke C, et al. (2007) The role of CnTI-SonoVue in the diagnosis of ovarian masses with papillary projections: a preliminary study. *Ultrasound Obstet Gynecol* 29: 512-516.
12. Henderson J, Goldacre MJ, Fairweather JM, Marcovitch H (1992) Conditions accounting for substantial time spent in hospital in children aged 1-14 years. *Arch Dis Child* 67: 83-86.
13. Oltmann SC, Fischer A, Barber R, Huang R, Hicks B, et al. (2009) Cannot exclude torsion--a 15-year review. *J Pediatr Surg* 44: 1212-1216.
14. Valsky DV, Esh-Broder E, Cohen SM, Lipschuetz M, Yagel S (2010) Added value of the gray-scale whirlpool sign in the diagnosis of adnexal torsion. *Ultrasound Obstet Gynecol* 36: 630-634.
15. Naiditch JA, Barsness KA (2013) The positive and negative predictive value of transabdominal color Doppler ultrasound for diagnosing ovarian torsion in pediatric patients. *J Pediatr Surg* 48: 1283-1287.
16. Rostamzadeh A, Mirfendereski S, Rezaie MJ, Rezaei S (2014) Diagnostic efficacy of sonography for diagnosis of ovarian torsion. *Pak J Med Sci* 30: 413-416.
17. Lee EJ, Kwon HC, Joo HJ, Suh JH, Fleischer AC (1998) Diagnosis of ovarian torsion with color Doppler sonography: depiction of twisted vascular pedicle. *J Ultrasound Med* 17: 83-89.
18. Peña JE, Ufberg D, Cooney N, Denis AL (2000) Usefulness of Doppler sonography in the diagnosis of ovarian torsion. *Fertil Steril* 73: 1047-1050.
19. Gittleman AM, Price AP, Goffner L, Katz DS (2004) Ovarian torsion: CT findings in a child. *J Pediatr Surg* 39: 1270-1272.

20. Sivit CJ (2008) Contemporary imaging in abdominal emergencies. *Pediatr Radiol* 38: S675-S678.
21. Swenson DW, Lourenco AP, Beaudoin FL, Grand DJ, Killelea AG, et al. (2014) Ovarian torsion: Case-control study comparing the sensitivity and specificity of ultrasonography and computed tomography for diagnosis in the emergency department. *Eur J Radiol* 83: 733-738.
22. Dillman JR, Strouse PJ, Ellis JH, Cohan RH, Jan SC (2007) Incidence and severity of acute allergic-like reactions to i.v. nonionic iodinated contrast material in children. *AJR Am J Roentgenol* 188: 1643-1647.
23. Brenner DJ, Hall EJ (2007) Computed tomography--an increasing source of radiation exposure. *N Engl J Med* 357: 2277-2284.
24. Kilickesmez O, Tasdelen N, Yetimoglu B, Kayhan A, Cihangiroglu M, et al. (2009) Diffusion-weighted imaging of adnexal torsion. *Emerg Radiol* 16: 399-401.
25. Piscaglia F, Bolondi L (2006) The safety of Sonovue in abdominal applications: retrospective analysis of 23188 investigations. *Ultrasound Med Biol* 32: 1369-1375.
26. Autret-Leca E, Bensouda-Grimaldi L, Le-Guellec C, Jonville-Béra AP (2006) Prescriptions and children. *Arch Pediatr* 13: 181-185.
27. Knieling F, Strobel D, Rompel O, Zapke M, Menendez-Castro C, et al. (2016) Spectrum, Applicability and Diagnostic Capacity of Contrast-Enhanced Ultrasound in Pediatric Patients and Young Adults after Intravenous Application - A Retrospective Trial. *Ultraschall Med* 37: 619-626.
28. Rosado E, Riccabona M (2016) Off-Label Use of Ultrasound Contrast Agents for Intravenous Applications in Children: Analysis of the Existing Literature. *J Ultrasound Med* 35: 487-496.
29. Steitz K, Strobel D (2016) A milestone: approval of CEUS for diagnostic liver imaging in adults and children in the USA. *Ultraschall Med* 37: 229-232.
30. Kupesic S, Plavsic BM (2010) Adnexal torsion: color Doppler and three-dimensional ultrasound. *Abdom Imaging* 35: 602-606.
31. Michelotti B, Segura BJ, Sau I, Perez-Bertholez S, Prince JM, et al. (2010) Surgical management of ovarian disease in infants, children, and adolescents: a 15-year review. *J Laparoendosc Adv Surg Tech A* 20: 261-264.
32. Yuen PM, Yu KM, Yip SK, Lau WC, Rogers MS, et al. (1997) A randomized prospective study of laparoscopy and laparotomy in the management of benign ovarian masses. *Am J Obstet Gynecol* 177: 109-114.
33. Tsafirir Z, Azem F, Hasson J, Solomon E, Almog B, et al. (2012) Risk factors, symptoms, and treatment of ovarian torsion in children: the twelve-year experience of one center. *J Minim Invasive Gynecol* 19: 29-33.
34. Spinelli C, Buti I, Pucci V, Liserre J, Alberti E, et al. (2013) Adnexal torsion in children and adolescents: new trends to conservative surgical approach -- our experience and review of literature. *Gynecol Endocrinol* 29: 54-58.
35. Galinier P, Carfagna L, Delsol M, Ballouhey Q, Lemasson F, et al. (2009) Ovarian torsion. Management and ovarian prognosis: a report of 45 cases. *J Pediatr Surg* 44: 1759-1765.
36. Pienkowski C, Kalfa N (2013) Presumed benign ovarian tumors of childhood and adolescent. *J Gynecol Obstet Biol Reprod Paris* 42: 833-841.
37. Celik A, Ergün O, Aldemir H, Ozcan C, Ozok G, et al. (2005) Long-term results of conservative management of adnexal torsion in children. *J Pediatr Surg* 40: 704-708.
38. Tranquart F, Correas JM, Ladam-Marcus V, Manzoni P, Vilgrain V, et al. (2009) Real-time contrast-enhanced ultrasound in the evaluation of focal liver lesions: diagnostic efficacy and economic issues from a French multicentric study]. *J Radiol* 90: 109-122.