



Case Report

Intestinal Obstruction by Ileosigmoid Knot: Report of Two Cases at Kara Teaching Hospital (Togo)

Dossouvi Tamegnon^{1*}, Kanassoua Kokou¹, Amavi Ayi², Kassegne Iroukora³, Amouzou Efoé-Ga¹, Adabra Komlan², Tchangai Boyodi², Alassani Fousseini², Dosseh Ekoué David²

¹Department of General Surgery, Teaching Hospital of Kara, Togo

²Department of General Surgery, Teaching Hospital of Sylvanus Olympio de Lomé, Togo

³Department of General Surgery, Teaching Hospital of CHR Kara-Tomdè, Togo

***Corresponding author:** Dossouvi Tamegnon, Department of General Surgery, Teaching Hospital of Kara, Po Box: 18, Kara, Togo

Citation: Tamegnon D, Kokou K, Ayi A, Iroukora K, Efoé-Ga A, et al. (2020) Intestinal Obstruction by Ileosigmoid Knot: Report of Two Cases at Kara Teaching Hospital (Togo). J Surg 5: 1327. DOI: 10.29011/2575-9760.001327

Received Date: 10 August, 2020; **Accepted Date:** 15 September, 2020; **Published Date:** 21 September, 2020

Abstract

The authors report two cases of acute intestinal obstruction by an ileosigmoid node. Both patients were young, male, one 24 years old and the other 31 years old. They were admitted in emergency for an acute intestinal obstruction. Abdominal x-ray showed hydroaeric levels in favor of hial and colonic occlusion in the 24-year-old patient while it showed right colonic distension associated with central hialic hydroaeric levels in the denier. A biological examen noted hyperleukocytosis in both cases. Because of the intensity of the pain and the hyperleukocytosis, a laparotomy was performed urgently, allowing an ileosigmoid knot to be found in both cases. In the first case, the imprisoned ileum was necrotic. As defection of the knot was impossible, resection of the ileum and sigmoid was performed followed by an ileo-ileal and colorectal anastomosis. In the second case, a defection of the knot had been performed allowing re-coloring of the ischemic ileum. A dolichomegasigmoid was also noted. Consequently colectomy had been performed. The postoperative period was marked by death in the first patient due to ionic disorders likely due to delayed treatment.

Keywords: Computed tomography; Emergency; Ileosigmoid knot; Occlusion; Togo

Introduction

The Ileosigmoid Knot (ISK) is a double volvulus characterized by a wrapping of the small intestine around the sigmoid base producing the obstruction of the small intestine and colon, which can quickly cause intestinal necrosis [1]. It is a rare cause of acute bowel obstruction described more in Africa, Asia and exceptionally in Europe [2]. It is responsible for a high morbidity and mortality due to the diagnosis delay [2]. Through two clinical observations and a review of the literature, we wanted to describe the diagnostic, therapeutic and prognostic feat of ileosigmoid knotting.

Case 1

Twenty-four-year-old patient, with no specific pathological history, admitted for abdominal pain, vomiting and sudden onset of transit, progressing approximately 24 hours before admission.

On entry, the examination showed good general condition; good hemodynamic status; absence of abdominal scar; distended abdomen, tympanic with elastic resistance; the hernial orifices were free; rectal bulb was empty on digital rectal examination. Elsewhere, the somatic examination was unremarkable. Faced with this occlusive syndrome, an X-ray of the abdomen without preparation carried out revealed hydroaeric levels in favor of the small intestine and the colon; there was no pneumoperitoneum. The biological examination showed hyperleukocytosis at 14,000 leukocytes / mm³. The diagnostic hypothesis of an internal occlusion was raised. In view of the intensity of the pain and the hyperleukocytosis, an exploratory laparotomy was performed allowing to find an ISK with signs of ileum and sigmoid pain (Figure 1). Defecting the knot was impossible due to the degree of tightness and the complexity of the mechanism of winding the ileum around the sigmoid colon. Resection of both the ileum and part of the sigmoid trapped with immediate restoration of digestive continuity. The postoperative effects were marked by death, probably secondary to ionic disorders due to delayed treatment.

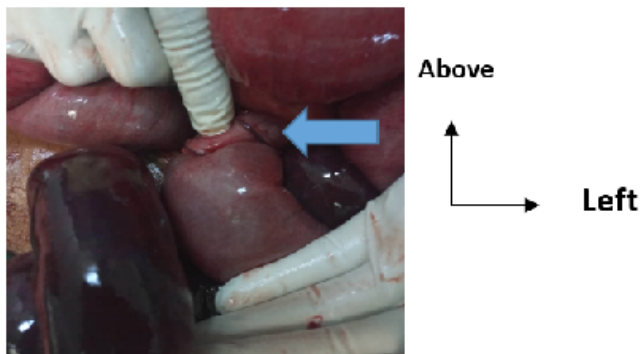


Fig 1: Intraoperative view of ileosigmoid knot (Blue arrow).

Case 2

Thirty-one-year-old patient, with no particular history, admitted for abruptly onset abdominal pain accompanied by vomiting and a transit stop evolving more than six hours before admission. At the admission the physical exam noted: a deterioration in general condition; a state of hemodynamic shock; an enlarged abdomen, tense with generalized defense; free hernial orifices; the empty rectal bulb; elsewhere, the physical examination was normal. We had strongly suspected an internal hernia. A biological exam noted hyperleukocytosis associated with functional renal failure. An unprepared abdominal x-ray performed for diagnostic purposes showed right aerocoly with central hydro-aeric levels. An emergency laparotomy was performed after conditioning the patient. She discovered an ISK with signs of ileum ischemia (Figure 2). A defecation of the knot was performed with a restoration of the ileum color. The exploration revealed a dolichosigmoid that required an ideal sigmoidectomy. The outcome was sample with the patient discharged on 7th day.

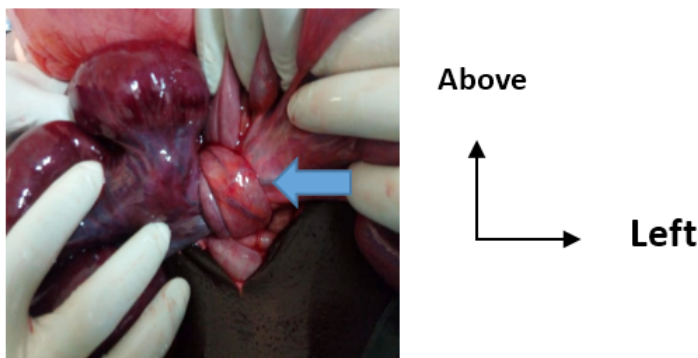


Fig 2: Intraoperative view of ileosigmoid knot (Blue arrow).

Discussion

ISK is a rare cause of acute bowel obstruction [3]. It was first described in 1945 by Parker [4]. The actual incidence of

this condition is unknown [5]. It is often encountered in young, male subjects of the fourth decade [1,2]. This observed male predominance could be explained by the fact that men have a very high mesocolon and a narrow pelvis while women have a wide pelvis and less toned muscles than that of men, which allows spontaneous devolvulation. Nevertheless, during pregnancy, women become more exposed to occlusive accidents especially during the third trimester, postpartum or after gynecological intervention [2,6]. The etiology of this condition remains unknown but several factors have been implicated. In fact, there is an anatomical factor that can be explained by a very active small intestine with an excessively long mesentery and a short root that can wrap around the foot of the sigmoid colon [7]; in addition, there is a dietary factor which says that the rapid repletion of the jejunum in patients eating only one meal per day would promote its twisting around the empty ileum, thus destroying the sigmoid loop [8]. ISK can occur through several mechanisms classified into 4 types. This classification is based on the active digestive segment involved in the torsion. Thus, type I: the ileum is the active segment wrapping around the passive sigmoid; type II: an active sigmoid twist that attracts passive hial; type III: the ileocecal junction which wraps around the sigmoid loop and type IV: it is indeterminate with an impossible differentiation between two digestive segments [9]. In our study, both cases were type I. The typical clinical symptomatology of an NIS associates those of a high occlusion marked by early vomiting and those of a low occlusion characterized by an early stop of transit with sometimes severe meteorism [2]. However, the often observed atypical clinical picture makes preoperative diagnosis difficult [10].

The diagnosis of ISK is sometimes made by imaging represented by abdominal X-ray and the computed tomography of abdomen with low opacification. An unprepared abdominal x-ray will typically but rarely show sigmoid hydro-aeric levels which project upwards at the level of the right hypochondrium and those of slender types can be lateralized to the left [11,12]. The computed tomography of the abdomen will often provide the diagnosis by highlighting a sign of whirlwind with a median deviation of the cecum, the left colon and the superior and inferior mesenteric vessels which will converge towards this whirlwind, an intestinal distension as well as signs of intestinal ischemia such as than parietal pneumatosis [3,11,12]. It has a diagnostic sensitivity of approximately 70% [12].

ISK is a surgical emergency that should not suffer from treatment delay. As soon as the diagnosis is suspected, an emergency laparotomy must be performed to assess the degree of tightening of the knot which can be undone as in our second case without intestinal resection. But often the diagnosis is made intraoperatively with intestinal necrosis requiring ileal resection and / or sigmoid colic with immediate or delayed restoration of

digestive continuity depending on local and general conditions [2,12]. We have performed immediate restoration of digestive continuity because of the absence of bowels's perforation, peritonitis and the difficulties in the management of ostomy in poor countries as Togo [13]. Morbidity from intestinal obstruction by ISK is approximately 25% while mortality is approximately 12% [2,7]. Morbidity is mainly represented by anastomotic fistulas, parietal suppurations with evisceration and septicemia [2]. The prognosis of this condition depends mainly on the time of admission, the general condition of the patient, the presence or not of loop necrosis and the circumstances of the surgery [2].

Conclusion

ISK is a rare cause of acute double bowel obstruction of the small bowel and sigmoid, which is often encountered in young adults of the fourth decade. It poses the problem of its diagnosis, which is often made late intraoperatively. Knowing its mechanism of occurrence and the characteristic radiological lesions will allow early diagnosis and treatment, guaranteeing a good prognosis.

References

1. Arthur V, Pascal A, Hubert R, Chagnaud C, Le Treut Y-P (2007) Le nœud ileosigmoïdien: une cause improbable d'occlusion intestinale primitive par strangulation bifocale. *Gastroenterol Clin Biol* 31: 975-977.
2. James Didier L, Chaibou MS, Adama S, Idé K, Abdoulaye MB, et al. (2017) Les occlusions intestinales par nœud ileo-Sigmoïdien : aspects diagnostiques, thérapeutiques et pronostiques. *European Scientific Journal* November 33: 254-264.
3. Elhattabi K, Fadil A, Benissa N, Lefriyekh R, Khaiz D, et al. (2012) Zerouali O.N. Le nœud ileosigmoïdien: à propos de 2 cas. *Pan Afr Med J* 11: 43.
4. Parker E (1845) Case of intestinal obstruction: sigmoid flexure strangulated by the ileum. *Edinb Med Surg J* 64: 306-308.
5. Zahid F, Majdoub KI, Lamrani J, Mazaz K (2009) Ileosigmoid knot strangles the sigmoid. *Journal of Emergencies, Trauma, and Shock* 2: 3.
6. Hind Boukhalit, Oujidane Zamani, Jroundi L (2019) Un cas de nœud iléo-sigmoïdien chez une femme en postpartum. *Pan Afr Med J* 32: 106.
7. Atamanalp SS, Ören D, Başoğlu M, Yıldırğan MI, Balık AA, et al. (2004) Ileosigmoidal knotting: outcome in 63 patients. *Dis Colon Rectum* 47: 906-910.
8. Shepherd JJ (1967) Ninety-two cases of ileosigmoid knotting in Uganda. *Br J Surg* 54: 561-566.
9. Alver O, Oren D, Tireli M, Kayabaşı B, Akdemir D (1993) Ileosigmoid knotting in Turkey: review of 68 cases. *Dis Colon Rectum* 36: 1139-1147.
10. Machado NO (2009) Ileosigmoid knot: A case report and literature review of 280 cases. *Ann Saudi Med* 29 : 402-406.
11. Lee SH, Park YH, Won YS (2000) The ileosigmoid knot: CT findings. *AJR Am J Roentgenol* 174: 685-687.
12. Hind Boukhalit, Oujidane Zamani, et Laila (2019) Un cas de nœud iléo-sigmoïdien en postpartum. *Pan Afr Med J* 32: 106.
13. Ayite A, Dosseh DE, Katakoo G, Tékou HA, James K (2006) Traitement chirurgical des perforations non traumatiques uniques de l'intestin grêle : excision-suture ou résection-anastomose. *Ann Chir* 13: 91-95.