



## Case Report

# Acute Motor Axonal Neuropathy in a Patient with Metastatic Pancreatic Neuroendocrine Tumor Receiving Chemotherapy with Capecitabine and Temozolomide: A Case Report

Magdalena Pircher<sup>1\*</sup>, Bettina Schreiner<sup>2</sup>, Ivette Engel-Bicik<sup>3</sup>, Elmira Far<sup>4</sup>, Karl Andreas Nowak<sup>4</sup>, Ulf Petrausch<sup>1</sup> Thomas Winder<sup>5</sup>, Daniel Helbling<sup>1</sup>

<sup>1</sup>Onkzentrum Zürich, Switzerland

<sup>2</sup>Department of Neurology, University Hospital Zurich, Switzerland

<sup>3</sup>Department of Nuclear Medicine, University Hospital Zurich, Switzerland

<sup>4</sup>Department of Clinical Pharmacology and Toxicology, University Hospital Zurich, Switzerland

<sup>5</sup>Swiss Tumor Molecular Institute, Switzerland

\*Corresponding author: Magdalena Pircher, Onkzentrum Zürich, Seestrasse 259, 8038 Zurich, Switzerland

**Citation:** Pircher M, Schreiner B, Engel-Bicik I, Far E, Nowak KA, et al. (2020) Acute Motor Axonal Neuropathy in a Patient with Metastatic Pancreatic Neuroendocrine Tumor Receiving Chemotherapy with Capecitabine and Temozolomide: A Case Report. Ann Case Report 14: 482. DOI: 10.29011/2574-7754.100482

**Received Date:** 25 September, 2020; **Accepted Date:** 01 October, 2020; **Published Date:** 06 October, 2020

### Abstract

We report a case of a 37-year old female patient with metastatic pancreatic neuroendocrine tumor that developed acute motor axonal neuropathy after receiving chemotherapy with capecitabine and temozolomide. She had repeatedly progressed after several surgical resections of her liver metastases, other hepatic directed procedures, several sessions of peptide receptor radionuclide therapy and two systemic treatment lines. When we started a third line therapy with capecitabine (1500 mg absolute twice daily, day 1-14) and temozolomide (360 mg absolute in two divided doses on day 1-5) in a 28 days long cycle, she unexpectedly developed a progressive weakness of the upper and lower limbs and dysphagia. The diagnosis of acute motor axonal neuropathy was confirmed by nerve conduction studies. The patient's condition improved rapidly after chemotherapy was stopped and plasma exchange (nine sessions) as well as a maintenance therapy with intravenous immunoglobulins was started. She was almost asymptomatic seven months after onset of symptoms. This case describes a previously unreported association between acute motor axonal neuropathy and chemotherapy with capecitabine and temozolomide.

**Keywords:** Acute motor axonal neuropathy; Capecitabine; Pancreatic neuroendocrine Tumor; Temozolomide

### Introduction

Pancreatic Neuroendocrine Neoplasms (pNENs) represent a rare tumor type arising from the neuroendocrine cell system of the pancreas and are subdivided in "functional" and "nonfunctional" tumors depending on whether they release peptide hormones leading to specific clinical syndromes [1]. pNENs are classified into well-differentiated Neuroendocrine Tumors (NETs) (G1 to G3) and poorly differentiated Neuroendocrine Carcinomas (NECs) (always G3), according to morphology and proliferation rate [2]. Prognosis is generally poor with reported median overall survival rates varying between 12 and 43 months, depending on

stage and grade [3]. Surgery is the mainstay of treatment in low to intermediate grade pNENS with curative intent and may still be indicated for palliative debulking to decrease tumor burden or help control hormone production [2]. Furthermore, metastasectomy of liver lesions is recommended if complete resection or debulking of <90% is feasible [4].

Other hepatic directed procedures include ablative therapy, Transarterial Embolization (TAE), Transarterial Chemoembolization (TACE) and Selective Internal Radiation Therapy (SIRT) [5]. Systemic therapy options include somatostatin analogs, Peptide Receptor Radionuclide Therapy (PRRT), low dose interferon, everolimus, sunitinib, bevacizumab and cytotoxic regimens [2]. The alkylating substances streptozotocin and temozolomide appear to have the strongest antitumor

activity in pancreatic NENs [6]. The Combination of the Oral Fluoropyrimidine Cytotoxic Agent Capecitabine and the Oral Alkylating Agent Temozolomide (CAPTEM) has been shown to be an effective treatment regimen in patients with advanced pNENs, resulting in high objective response rates (70%) and considerably low toxicity.

The most frequently observed severe toxicities (grade 3-4) are blood and lymphatic system disorders, mucositis, diarrhea and nausea [6,7]. Acute Motor (Axonal) Neuropathy (AMAN) is considered an immune-mediated variant of Guillain-Barré Syndrome (GBS) and it is characterized by acute flaccid symmetrical paralysis without sensory deficit that can often be complicated by respiratory failure. Most AMAN patients have *Campylobacter jejuni* (*C. jejuni*)-reactive and various anti-ganglioside antibodies, suggesting a strong link between microbial pathogens and the disease initiation [8]. So far, it has rarely been observed that GBS or any of its variants can complicate chemotherapy [9-15]. To the best of our knowledge, this is the first report of AMAN in a patient receiving chemotherapy with CAPTEM.

## Case Report

In this case a 37-year old female was diagnosed with a nonfunctional pancreatic NET G2 (Ki 67: 10%, 10 mitoses/ 10 HPF) with strong expression of Somatostatin Receptors (SSTR2 A) and extensive liver metastases. She presented initially with epigastric pain, nausea and sporadic diarrhea. The Gallium-68-DOTA-TATE (DOTA-[Tyr3] Octreotate, SST analog) PET/CT showed only a weak uptake of DOTATATE in the pancreas and in contrast a high uptake in the liver metastases. Therefore, primary surgery was performed with pancreatectomy, splenectomy and segmentectomy of liver segment V, in order to remove the radionuclide-insensitive part of the disease. The patient overcame surgery very well, and all symptoms passed off. In a next step, we started a PRRT with Lutetium-177-DOTA-TATE. After four cycles of Lutetium-177-DOTA-TATE (7400 MBq per cycle) the patient showed a good radiological response in the liver MRI and the Gallium-68-DOTA-TATE PET/CT restaging 12 weeks later revealed partial remission.

We initiated a systemic therapy with the somatostatin analog lanreotide in order to reach prolonged disease stabilization. Simultaneously, radioablation of the four most critically located liver metastases in liver segment III and VIII was performed, allowing a hemihepatectomy on a later time-point. Radiological staging (MRI abdomen) after four months showed a stable disease in the liver. Because of the young age of the patient and the very good performance status, we decided to follow an aggressive strategy regarding the liver metastases and a left sided hemihepatectomy with atypical resection of liver segments VIII, VII, V and radio-ablation in liver segment VII was performed. The therapy with lanreotide was continued for 15 months under

regularly serologic (tumor marker, liver enzymes) and radiological (MRI abdomen) controls.

Then, the tumor marker chromogranin A was rising from former normal levels at 119 µg/l and liver MRI revealed progression of the liver metastases. Systemic therapy was switched to everolimus (10 mg orally once daily). However, after only one month, progressive disease in the liver was diagnosed via MRI abdomen and Gallium-68-DOTA-TATE PET/CT. Therefore, four more cycles of PRRT with Lutetium-177-DOTA-TATE (two cycles with 7400 MBq, two cycles with 7200 MBq) were conducted, resulting in regression of the liver metastases. Lanreotide was reactivated as maintenance therapy. Five months later the Gallium-68-DOTA-TATE PET/CT showed progression of the liver metastases and suspicion of a new peritoneal metastasis in the Douglas cavity. As the liver metastases were still the leading problem, we opted for a local therapy in form of a TACE with doxorubicin (150 mg) and continuation of lanreotide. Nevertheless, only three months later, liver MRI revealed two progressive and one stable liver lesion in liver segments V and VI. Thus, the patient underwent microwave ablation of the three liver metastases.

At the same time, a liver biopsy was taken in order to go for molecular testing. The OncoPrint Tumor Mutation Load Assay showed no molecular targets suitable for a targeted therapy, maybe necessary in the later course of the disease. Actually, Gallium-68-DOTA-TATE PET/CT after three months stated progressive disease in the liver, the bone and the peritoneum. Therefore, further local therapies were no choice and we planned another session of four cycles PRRT. Because of the fulminant progression, we initiated a bridging systemic therapy with CAPTEM (oral capecitabine, 1500 mg absolute twice daily, day 1-14 and temozolomide, 360 mg absolute in two divided doses on day 1-5 in a 28 days long cycle) before the start of another PRRT. Unexpectedly, already two days after therapy start, the patient developed a progressive weakness of the upper limbs, followed by a weakness of the lower limbs and dysphagia on the other day. Chemotherapy was discontinued.

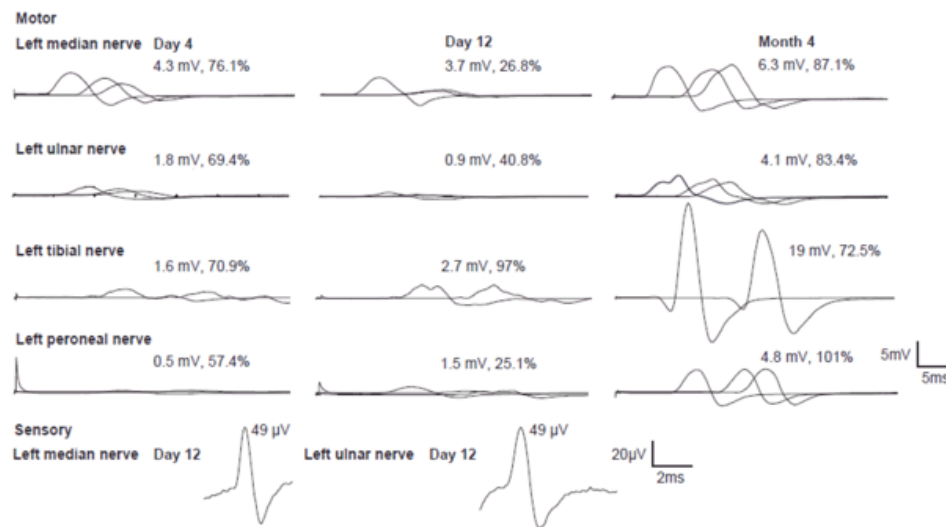
The neurological examination found mostly symmetrical greater proximal paresis of the upper limbs and greater distal paresis of the lower limbs without impairment of the sensory modalities. The muscle-self reflexes were reduced. MRI scan of the brain and the cervical and thoracic spine were unremarkable. Nerve Conduction Studies (NCS) and needle Electromyography (EMG) were performed. NCS included motor conduction studies in median, ulnar, tibial and peroneal nerves, along with sensory NCS in median and ulnar nerves. They revealed an axonal motor polyneuropathy with reduced Compound Muscle Action Potential (CMAP) amplitudes especially in the lower limbs and prolonged distal motor latencies four days after clinical onset. Motor conduction blocks in the ulnar and the median nerve as well as in the peroneal nerve on the left side and absent F-waves were found eight days later. Repetitive nerve stimulation tests of the

ulnar nerve and sensory nerve conduction studies were normal (Figure 1).

Cerebrospinal fluid (CSF) analysis performed four days after clinical onset showed no pathologies especially the white cell count and protein were within normal range. CSF glucose and lactate were normal. The routine diagnostic workup at admission including serum potassium, Creatine Kinase (CK) and infection serology were either normal or negative. Anti-ganglioside antibodies, anti-CNS antibodies (including anti-Hu, Ri, Yo, amphiphysin, CV2 (CRMP5), Ta/Ma2, Ma1, SOX1, GAD65, ZIC4 and Tr) and anti-voltage-gated calcium channel (VGCC) antibodies were negative. The clinical and electrodiagnostic findings altogether led to the diagnosis of a tetraparetic AMAN. A nerve biopsy was not performed because the patient's condition improved considerably within the next weeks. The patient was admitted to the neurologic Intensive Care Unit (ICU) and treated

with nine sessions of plasma exchange.

After the third plasma exchange, she already showed increasing muscle strength in the lower limbs. After nine sessions she showed remarkable recovery and when she was discharged home (after one month), she was able to eat and walk independently again. Afterwards, a maintenance therapy with intravenous Immunoglobulins (IVIg) was established and is still going on after seven months (IVIg 2g/kg over five days per cycle per month). Four months after clinical onset (and during the third cycle of IVIg), the NCS were repeated and showed a pronounced improvement with partially recovered or even normalized CMAP amplitudes paralleling the clinical recuperation. The signs of conduction blocks had disappeared (Figure 1). Accordingly, the IVIg dose per cycle could be reduced without clinical relapse. Now, seven months later, the only symptom the patient complains of is a slight weakness in both arms.



**Figure 1:** NCS on day 4, day 12 and after 4 months.

## Discussion

Our patient fulfills the clinical and electrodiagnostic criteria for the AMAN variant of GBS, appearing shortly after initiation of chemotherapy with CAPTEM for metastatic pNET [16]. GBS or any of its variants is an acute inflammatory polyradiculoneuropathy, characterized by the acute onset of peripheral and cranial nerve dysfunction. The typical clinical picture is an acute flaccid paralysis, characterized by symmetrical ascending weakness of the limbs, and hyporeflexia or areflexia, which reaches a maximum severity within four weeks. Myelin or the axons of peripheral nerves can be primarily injured, resulting in demyelinating or axonal forms of GBS: Acute Inflammatory Demyelinating Polyneuropathy (AIDP) or Acute Motor Axonal

Neuropathy (AMAN), or other variants. In the pure motor form AMAN, the axonal polyneuropathy is not accompanied by sensory deficits at clinical and electrophysiological examination.

Owing to axonal degeneration, usually the disease progresses more rapidly than in AIDP and a prolonged recovery is typical. The diagnosis of GBS is a clinical one, but additional investigations can be helpful or even needed for confirmation. Examination of CSF excludes other causes of weakness, associated with an increase in CSF cell count. Typical for GBS is the cytoalbuminologic dissociation: the combination of a normal cell count and increased protein level. However, normal protein levels (especially when determined in the first week after onset of disease) do not make the diagnosis unlikely or even exclude GBS [8,17]. Actually,

our patient had no cytoalbuminologic dissociation at the initial evaluation four days after clinical onset. A lumbar puncture was not repeated at a later time point because of the favourable clinical course. Furthermore, Nerve Conduction Studies (NCS) can help to support the diagnosis of GBS and to differentiate between the axonal and the demyelinating subform. Features of AMAN are decreased motor amplitudes, but - similar to the case presented here - transient conduction blocks and slowing have been described in some patients as well.

They are possibly caused by impaired conduction at the nodes of Ranvier [18]. GBS is thought to result from an immune response to a preceding respiratory or gastrointestinal infection or an immunization which cross-reacts with peripheral nerve components because of molecular mimicry. *C. jejuni* is hereby the predominantly described infection with 25-50 %. Other associated infections are Cytomegalovirus (CMV), Epstein Barr Virus (EBV), influenza A virus, *Mycoplasma pneumoniae*, *Haemophilus influenzae*, hepatitis E, zika- and chikungunya virus. Regarding immunization, GBS was observed after vaccination with Semple rabies vaccine and various types of influenza A virus vaccine [8,17]. Notably our patient did not report any infection or immunization within the preceding four weeks. According to the obvious temporal association between AMAN and chemotherapy initiation, the issue mostly meriting discussion is whether AMAN was triggered by CAPTEM chemotherapy or if it was just a coincidence. This is particularly of concern, as the first neurological symptoms occurred only two days, after the CAPTEM chemotherapy was started.

It also points to a mechanism of injury different from the classic concept of “molecular mimicry” as the interval seems too short for the generation of cross-reactive B and T cell responses. GBS as a complication of chemotherapy has rarely been observed. There exist few reports of GBS manifestation in cancer patients treated with platinum compounds, nab-paclitaxel, vincristine, cytarabine or cladribine and only one case of a pure AMAN was reported [9-15]. However, in all of these cases it was not possible to verify a clear correlation between AMAN and the administration of chemotherapy and the underlying mechanisms remain unclear. Notably, all these substances are known to induce neurotoxicity in form of peripheral polyneuropathy and it was assumed that maybe other types and mechanisms of neurotoxicity exist for these drugs, which are not common and have not been recognized yet [12]. Thus, it was suggested that nab-paclitaxel induced an increase in proinflammatory cytokines leading to an immune-mediated insult in the axolemma, triggering AMAN. As another explanation, it was assumed that taxane-based chemotherapy induced macrophage infiltration and injury in the axolemma at the nodes of Ranvier [19].

In support of this, pathologically, AMAN is a pure motor axonopathy without demyelination as a result of inflammatory

mononuclear infiltrates and evidence of macrophage-mediated phagocytosis on the axolemma [20]. In contrast, neurotoxicity is not frequently described in CAPTEM chemotherapy [6,7]. A global search of the WHO pharmacovigilance database VigiBase® for temozolomide reveals 15.207 Individual Case Safety Reports (ICSRs) since 1997, of which 2.780 (18.3%) are categorized under the System Organ Class (SOC) “nervous system disorders” [21]. 54 (1.9%) ICSRs have been labelled with the primary term “neuropathy peripheral”. Only one case documented an axonal neuropathy with a reaction onset latency of approximately four months. Pharmacovigilance reporting for capecitabine encompasses 61.905 ICSRs globally, 7.814 ICSRs (12.6%) under SOC: “nervous system disorders” including 161 cases (2.1%) of peripheral neuropathies, specifying one case of axonal neuropathy. Unfortunately, the case details of capecitabine leading to axonal neuropathy do not contain a reaction time onset [21].

Temozolomide is a prodrug of the alkylating agent Monomethyl-Triazen-Imidazol-Carboxamid (MTIC). After administration, temozolomide is quickly absorbed ( $T_{max}$  0.5 - 1.5 h) in the intestine, roughly 10-20 % are protein bound and activation occurs non-enzymatically by hydrolysis. With a mean elimination half-life of approximately 1.8 hours, most of the applied substance is excreted as metabolites by the kidney. Capecitabine itself is non-toxic and readily bioavailable when ingested. After initial hepatic transformation to 5'-desoxy-5-fluorocytidine and further (preferred tumor-specific) activation to the antimetabolite 5-Fluorouracil (5-FU), it inhibits protein-biosynthesis. Detoxification is initiated by the enzyme Dehydropyrimidine-Dehydrogenase (DPD), which determines the speed of elimination. A lack of DPD or a, not all that unusual, mutation in the DPYD-allele (i.e. DPYD\*2A) can lead to elevated toxicities, hence pharmacogenetic testing prior to exposure is recommended. Notably, our patient was not harbouring such a mutation.

In healthy subjects, elimination half-life of capecitabine is short with approximately 0.85 h, though the metabolite  $\alpha$ -Fluoro- $\beta$ -Alanin (FBAL) has an elimination half-life of 3.23 hours. Both temozolomide and capecitabine respectively their active metabolites, are eliminated quite rapidly, raising doubt whether the observed neurotoxicity might be mediated by the substances, their metabolites, or rather triggered by an immunogenic response [21]. The standardized case causality assessment of WHO-UMC (Uppsala Monitoring Centre) describes adverse drug reactions as rarely specific to a drug and diagnostic tests are often missing. Repeated administration of the substance (re-challenge) is usually not ethically justified [22]. To narrow down the possible causes a combination of intrinsic (pharmacologic aspects of the case history) and extrinsic (documentation in literature and databases) parameters serve to verify causality. Beside of CAPTEM chemotherapy the tumor itself could potentially trigger AMAN in form of a praneoplastic neurological syndrome. To our knowledge,

there has been described only one case of paraneoplastic AMAN in anal cancer [23].

Neuroendocrine Neoplasms (NENs) are in fact frequently associated with paraneoplastic syndromes, but usually in form of metabolic disorders that are attributed to the neoplastic secretion of functional peptides, hormones, cytokines and growth factors. Neurological paraneoplastic syndromes are not typical for NENs and only one case of paraneoplastic Eaton- Lambert myasthenic syndrome in an undifferentiated small cell carcinoma of the larynx has been reported so far [24]. However, in our case the simultaneous beginning of the symptoms with the start of CAPTEM therapy and the lack of any neurological symptoms before CAPTEM initiation are strong arguments against a paraneoplastic syndrome. IVIg and plasma exchange are effective treatment strategies for all types of GBS [17]. Our patient improved during plasmapheresis and IVIg treatment, which could point to an inflammatory mechanism for the development of AMAN here, or be unrelated.

## Conclusion

We believe that our patient developed AMAN as a result of CAPTEM. It remains unclear which mechanism caused AMAN and if only one drug or both drugs contributed to this disease. By describing this previously unreported association, we want to raise awareness of a possible relationship between them.

## Authors' Contributions

DH, UP, TW, BS, IEB, KN and EF followed the patient. MP, DH, BS, IEB, KN and EF wrote the paper. All authors reviewed and approved the final manuscript.

## Ethics Approval and Consent to Participate

Samples were obtained in accordance with the principles of the Declaration of Helsinki. Informed consent was obtained from the patient.

## Consent for Publication

Consent was provided by the patient for publication of this case.

## Data Availability

The datasets used and/ or analyzed during the current study are available from the corresponding author on reasonable request.

## Conflict of Interest

All authors declare to have no conflict of interest.

## Funding

This research received no specific grant from any funding agency in the public, commercial or not-for-profit sectors.

## References

1. Baur AD, Pavel M, Prasad V, Denecke T (2016) Diagnostic imaging of pancreatic neuroendocrine neoplasms (pNEN): tumor detection, staging, prognosis, and response to treatment. *Acta Radiol* 57: 260-270.
2. Oronsky B, Ma PC, Morgensztern D, Carter CA (2017) Nothing but NET: A Review of Neuroendocrine Tumors and Carcinomas. *Neoplasia* 19: 991-1002.
3. Dasari A, Shen C, Halperin D, Zhao B, Zhou S, et al. (2017) Trends in the Incidence, Prevalence, and Survival Outcomes in Patients With Neuroendocrine Tumors in the United States. *JAMA Oncol* 3: 1335-1342.
4. Basuroy R, Srirajaskanthan R, Ramage JK (2012) A multimodal approach to the management of neuroendocrine tumour liver metastases. *Int J Hepatol* 2012: 819193.
5. Grozinsky-Glasberg S, Kaltsas G, Kaltsatou M, Lev-Cohain N, Klimov A, et al. (2018) Hepatic intra-arterial therapies in metastatic neuroendocrine tumors: lessons from clinical practice. *Endocrine* 60: 499-509.
6. Lu Y, Zhao Z, Wang J, Lv W, Lu L, et al. (2018) Safety and efficacy of combining capecitabine and temozolomide (CAPTEM) to treat advanced neuroendocrine neoplasms: A meta-analysis. *Medicine (Baltimore)* 97: e12784.
7. Strosberg JR, Fine RL, Choi J, Nasir A, Coppola D, et al. (2011) First-line chemotherapy with capecitabine and temozolomide in patients with metastatic pancreatic endocrine carcinomas. *Cancer* 117: 268-275.
8. Willison HJ, Jacobs BC, van Doorn PA (2016) Guillain-Barre syndrome. *Lancet* 388: 717-727.
9. Litsardopoulos P, Bikas C, Dimitropoulou D, Lykoura C, Anastopoulou GG, et al. (2019) Fatal, paraparetic acute motor axonal neuropathy, early complicating chemotherapy with nab-paclitaxel. *Anticancer Drugs* 30: 422-424.
10. Yoon JY, Nam TS, Kim MK, Hwang JE, Shim HJ, et al. (2018) Acute inflammatory demyelinating polyradiculoneuropathy in a patient receiving oxaliplatin-based chemotherapy. *Asia Pac J Clin Oncol* 8: 201-204.
11. Re D, Schwenk A, Hegener P, Bamborschke S, Diehl V, et al. (2000) Guillain-Barre syndrome in a patient with non-Hodgkin's lymphoma. *Ann Oncol* 11: 217-220.
12. Christodoulou C, Anastasopoulos D, Visvikis A, Mellou S, Detsi I, et al. (2004) Guillain-Barre syndrome in a patient with metastatic colon cancer receiving oxaliplatin-based chemotherapy. *Anticancer Drugs* 15: 997-999.
13. Johnson NT, Crawford SW, Sargur M (1987) Acute acquired demyelinating polyneuropathy with respiratory failure following high-dose systemic cytosine arabinoside and marrow transplantation. *Bone Marrow Transplant* 2: 203-207.
14. Moudgil SS and Riggs JE (2000) Fulminant peripheral neuropathy with severe quadriparesis associated with vincristine therapy. *Ann Pharmacother* 34: 1136-1138.

15. Sarmiento MA, Neme D, Fornari MC, Bengio RM (2000) Guillain-Barre syndrome following 2-chlorodeoxyadenosine treatment for Hairy Cell Leukemia. *Leuk Lymphoma* 39: 657-659.
16. Asbury AK and Cornblath DR (1990) Assessment of current diagnostic criteria for Guillain-Barre syndrome. *Ann Neurol* 27: S21-S24.
17. van den Berg B, Walgaard C, Drenthen J, Fokke C, Jacobs BC, et al. (2014) Guillain-Barre syndrome: pathogenesis, diagnosis, treatment and prognosis. *Nat Rev Neurol* 10: 469-482.
18. Kokubun N, Nishibayashi M, Uncini A, Odaka M, Hirata K, et al. (2010) Conduction block in acute motor axonal neuropathy. *Brain* 133: 2897-2908.
19. Peters CM, Jimenez-Andrade JM, Jonas BM, Sevcik MA, Koewler NJ, et al. (2007) Intravenous paclitaxel administration in the rat induces a peripheral sensory neuropathy characterized by macrophage infiltration and injury to sensory neurons and their supporting cells. *Exp Neurol* 203: 42-54.
20. Hafer-Macko C, Hsieh ST, Li CY, Ho TW, Sheikh K, et al. (1996) Acute motor axonal neuropathy: an antibody-mediated attack on axolemma. *Ann Neurol* 40: 635-644.
21. VigiBase WHO- UMC
22. The use of the WHO-UMC system for standardised case causality assessment. The Uppsala Monitoring Centre.
23. Lopez JL, Amezcua S, Pascual J, Algara M (2011) Acute motor axonal neuropathy associated with anal carcinoma: Paraneoplastic neurological syndrome or coincidence? *Rep Pract Oncol Radiother* 16: 54-57.
24. Medina JE, Moran M, Goepfert H (1984) Oat cell carcinoma of the larynx and Eaton-Lambert syndrome. *Arch Otolaryngol* 110: 123-126.