



## Case Report

### Jejunal Stenosis as a Late Complication of Superior Mesenteric Vein Thrombosis: Overview and Case Report

Ana Karen García-Ávila\*, Luis Eduardo Casasola-Sánchez, Karina Sánchez-Reyes and Patricio Sánchez-Fernández

Department of General Surgery, Specialty Hospital, XXI Century National Medical Center, Mexico

**\*Corresponding author:** Ana Karen García-Ávila, Department of General Surgery, Specialty Hospital, XXI Century National Medical Center, Av. Cuauhtémoc 330, Doctores, Cuauhtémoc, 06720, Mexico City, Mexico

**Citation:** García-Ávila AK, Casasola-Sánchez LE, Sánchez-Reyes K, Sánchez-Fernández P (2020) Jejunal Stenosis as a Late Complication of Superior Mesenteric Vein Thrombosis: Overview and Case Report. J Surg 5: 1324. DOI: 10.29011/2575-9760.001324

**Received Date:** 30 July, 2020; **Accepted Date:** 07 August, 2020; **Published Date:** 11 August, 2020

#### Abstract

Ischemic bowel stenosis is an infrequent late complication of chronic ischemia in a patient with thrombosis of the Superior Mesenteric (SMV) and portal vein (PV) and there are only few cases reported. Abdominal Computed Tomography scan (CT scan) is the preferred radiologic test for this disease. Close follow-up of each patient is essential even after treatment for MSV thrombosis for an early diagnosis and treatment of this complication. We present a case of ischemic jejunal stenosis subsequent to SMV thrombosis and anticoagulant treatment, as well as a literature overview

**Keywords:** Bowel ischemia; Jejunal stricture; Superior mesenteric vein thrombosis

#### Introduction

Mesenteric ischemia refers to intestinal hypoperfusion which can be due to occlusive obstruction of the venous mesenteric outflow, it can be classified as acute, sub-acute or late ischemia due to time of onset [1]. Acute thrombotic occlusion of one or more mesenteric veins reduce the perfusion pressure due to the increased resistance in the mesenteric venous bed. As stasis begins, venous pressure increases leading to fluid overflow toward tissues, causing intestinal wall edema, which can produce submucosal bleeding. If the venous arches and the rectal vessels are involved and the venous flow is completely occluded, it will cause intestinal infarction or, if it reperfuses, an ischemic stenosis [2].

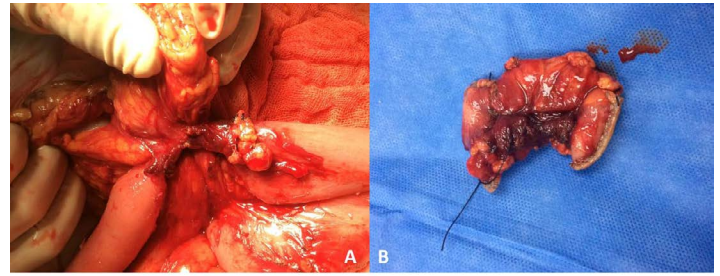
Small bowel stenosis due to ischemia is a late complication in patients with thrombosis of the Superior Mesenteric Vein (SMV) and/or the Portal Vein (PV) [3,4]. Post ischemic stenosis can present as a segmental circumferential ulcer and tubular segmental stenosis [5]. Abdominal Computed Tomography (CT) is the standard diagnostic method for the initial assessment as well as for determining location, possible etiology and extent of the pathology. We report a case of ischemic proximal jejunal stenosis in a patient with history of SMV thrombosis due to Oral Contraceptives (OC) and management with Oral Anticoagulant (OA), as well as a literature review.

#### Case Report

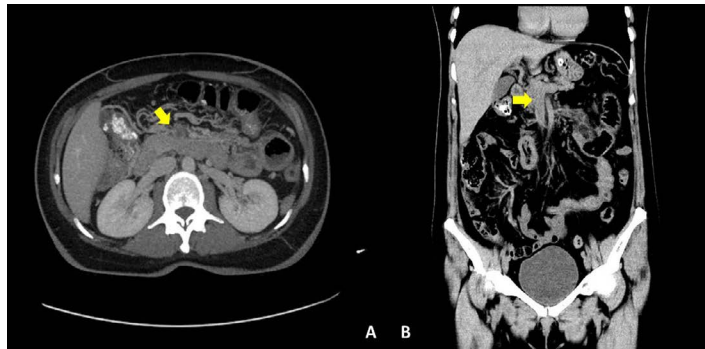
A 49 year old female attended the emergency department with vague abdominal pain of three weeks duration, progressive oral intolerance and abdominal distention. Examination revealed abdominal distention with palpable bowel loops, diffuse abdominal tenderness and normal digital rectal examination. Her past medical history included SMV thrombosis one month previously (Figure 1) currently under OA therapy with a factor Xa inhibitor. She had history of OC chronic intake. On admission a nasogastric tube was placed, obtaining abundant high intestinal output with later symptoms improvement. Biochemical studies revealed no alterations, leucocytes count of 5,200 / $\mu$ L. High outlet obstruction syndrome was diagnosed and a small intestine follow through was performed, which revealed an increased diameter at the proximal jejunum, up to 52 mm, and a subsequent transition zone (Figure 2A). Due to her medical history of thrombosis an abdominal CT angiography was performed which showed significant stomach dilatation as well as the duodenum and proximal jejunum with a transition zone at the present site (Figure 2B) features of mechanical small bowel obstruction. The previously thrombus in the SMV had resolved. Enteroscopy was also performed and revealed a significant decrease in jejunal caliber, 40 to 50 cm after Treitz angle, due to stenosis presented with ulcerated edges covered with fibrin, impassable, with 3mm diameter, a tissue sample was taken (Figure 3). Based on the previous findings, surgical team decided to perform an exploratory laparotomy where a stenosis was found at 50 cm of Treitz angle of approximately 70 mm that conditioned

the transtion zone (Figure 4), segmental resection was performed with lateral-lateral anastomosis. She was discharged five days later, currently under follow-up, without apparent complications.

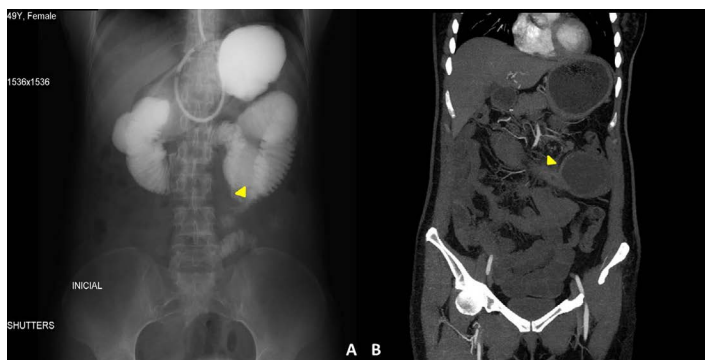A small bowel segment measuring 75 x 35 x 20 mm was received in the pathology department, with dark brown serosa, violaceous patches and a stenosis zone of 2 mm in diameter with loss of folds, smooth and reluctant texture. Histopathological diagnosis of abscessed stenosis with fibrous areas and abundant granulation tissue (Figure 4).



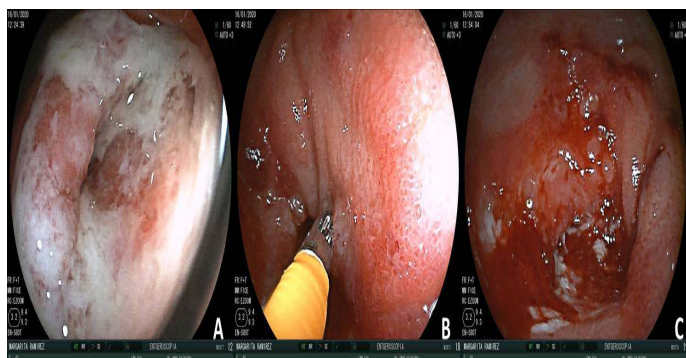
**Figure 4**



**Figure 1**



**Figure 2**



**Figure 3**

## Discussion

Mesenteric Venous Trombosis (MVT) is responsible of 5 to 15% of all the mesenteric thrombosis cases; it can be primary or idiopathic, spontaneous with no identified cause, or secondary when it has a predisposing risk factor. It is more common in men aged between 40 to 60 years and is has an acute presentation in 6 to 9% of the cases [6]. The incidence has increased due to early diagnosis by imaging methods, mortality exceeds the 20% and the initial symptom is diffuse abdominal pain. In the 89% of the cases the SMV is involved and in 11% the inferior mesenteric vein. The diagnosis is ideally by CT, which has a sensitivity greater than 90% and by biochemical studies usually with lactate and amylase (< 1,000) elevation. The gold standard is mesenteric and portal vein angiography although it is an invasive study reserved if other imaging studies are not conclusive. Subacute thrombosis is most often asymptomatic or with mild diffuse abdominal pain [6,7]. Treatment is aimed at relieving symptoms and preventing progression to acute ischemia, OA therapy is the mainstay treatment, which should be continue after the patient discharge. Thrombolysis and thrombectomy are useful therapeutic options for acute cases with significant ischemia. Surgery is reserved for those cases where there is no improvement or there is an installed bowel acute ischemia. It has been found secondary arterial vasospasm in some patients with venous thrombosis, which worsens ischemia when there are no venous collaterals [6,7].

Among the possible etiologies, OC consumption is responsible for 4 to 5 % of the mesenteric vein thrombosis (MVT), the mechanism is not completely understood: changes in endothelium, antifibrinolytic activity and prothrombotic activity have been associated but not related. The incidence of MVT in relation to the total of patients who consume OC (18% of the population in developing countries) is sporadic, our cases the second reported in the world [8]. After a complete bibliographic research in Pubmed and Lilacs we found nine reported cases of jejunal stenosis after MVT. In two the complete paper and patient data could not be obtained, so only seven cases were assessed, which are described in (Table 1).

	Case	Time between MVT and stenosis	Thrombosed vessel	Treatment	Cinical Clinical presentation	Surgical Treatment
Eugéne et al. (1995) [9]	Male 36 years	1 month	Porta y VMS	Heparine	High obstruction	Segmental resection at 30 cm Treitz
	Male 46 years	NA	SMV	Heparine	High obstruction in 2 cases	Segmental resection 20 and at 30 cm Treitz
	Male 54 years	2 months	PV	OA	Abdominal pain	Jejunal segmental resection
Uribe, et al. (1999) [10]	Female 36 years (OC)	1 month	PV & SMV	OA	High obstruction	Segmental resection at 40 and 75 cm Treitz
Antoch, et al. (2001) [11]	Male 35 years	1 month	PV & SMV	OA	Abdominal pain	Segmental resection at 100 cm Treitz
	Male 43 years	1 month	SMV	Thrombolysis + OA	Abdominal pain	Segmental resection at 30 cm Treitz
Yang, et al. (2012) [12]	Male 64 years	1 month	SMV	Thrombolysis + OA	High obstruction	Segmental resection at 50 cm Treitz
Huh, et al. (2002) [13]	2 cases	NA	SMV	NA	NA	Segmental resection

**Table 1:** Jejunal stenosis characteristics due to mesenteric vein thrombosis in reported cases from 1995 to 2020.

In (Table 1) is relevant the case of a woman with medical history of consuming OC such as our patient. The mean time of development stenosis post thrombosis venous was one month in most of the reported patients and segmental resection was performed in all cases. The likelihood of developing intestinal ischemia depends upon the adequacy of systemic perfusión perfusion and colateral collateral circulation, the number and caliber of the affected vessels and the duration of the ischemic insult. Intestinal injury is caused both by tissue hipoxia hypoxia and reperfusion. The cause of the stenosis is not well understood and it is believed that venous thrombosis generates ischemia to the affected loop but not enough to generate necrosis, ischemia is present and chornically chronically responds with fibrosis of the involved tissues, therefore generating a fibrotic strand, stenosis, and subsequent intestinal occlusion.

The management of the bowel stenosis in all the reviewed cases was surgical resection with anastomosis, however, the standard treatment of the thrombosis event has not been defined but OA is generally accepted as the standard treatment, as in our case, or more advanced therapies such as thrombolysis as mentioned by

Rawla, et al. [8] which mentions a successful treatment without late complications. At the Shangdon Provincial Hospital, Xu, et al. [14] performed a retrospective study from 2016 to 2017, finding nine patients who presented acute venous thrombosis and necrosis of the affected segment who underwent surgical resection and anastomosis at the acute event and balloon-assisted thrombectomy in the same procedure with recanalization in the 10% of the patients. This technique can be successful in conjunction with long term treatment of OA, although there is still insufficient evidence to determine the optimal treatment and results in these patients.

## Conclusion

Ischemic jejunal stenosis is a rare late complication of mesenteric venous thrombosis, of which there must be high clinical suspicion for the early diagnosis and treatment of thrombosis and close monitoring for the development of stenosis weeks after the thrombotic event. There is no standardized treatment and once stenosis is diagnosed, the recommended treatment is segmental resection with anastomosis and long-term anticoagulation.

## References

1. Tilsed J, Casamassima A, Kurihara H, Mariani D, Martinez I, et al. (2016) ESTES guidelines: acute mesenteric ischaemia. *European Journal of Trauma and Emergency Surgery* 42: 253-270.
2. Johnson C, Baggenstoss A (1949) Mesenteric vascular occlusion; study of 99 cases of occlusion of veins. *Proc Staff Meet Mayo Clin* 24: 628.
3. Rhee RY, Gloviczki P (1997) Mesenteric venous thrombosis. *Surg Clin North Am* 77: 327-338.
4. Chen M, Brown MC, Willson RA, Nicholls S, Surawicz CM (1996) Mesenteric vein thrombosis. Four cases and review of the literature. *Dig Dis* 14: 382-389.
5. Kim J, Kim H, Hong S, Park S, Lee J, et al. (2017) Post-Ischemic Bowel Stricture: CT Features in Eight Cases. *Korean Journal of Radiology* 18: 936-945.
6. Sulger E, Dhaliwal H, Goyal A, Gonzalez L (2020) Mesenteric Venous Thrombosis, *StatPearls NCBI Bookshelves* 2020: 1-4.
7. Harnik I, Brandt L (2010) Mesenteric Venous Thrombosis, *Vasc Med* 15: 406-418.
8. Rawla P, Pradeep-Raj J, Chaitanya-Thandra K, Bandaru S (2017) Superior Mesenteric Vein Thrombosis in a Patient on Oral Contraceptive Pills, *Gastroenterol Res* 10: 380-382.
9. Eugène C, Valla D, Wesenfelder L, Fingerhut A, Bergue A, et al. (1995) Small Intestinal Stricture complicating superior mesenteric vein thrombosis. A study of three cases *Gut. Case Reports* 37: 292-295.
10. Uribe S, Feres E, Flores C (1999) Estenosis segmentaria de Intestino Delgado luego de trombosis de vena mesentérica superior. *Caso clínico Rev Med Chile* 127: 1369-1374.
11. Antoch G, Hansen O, Pourhassan S, Stock W (2001) Ischemic jejunal stenosis complicating portal and mesenteric vein thrombosis: a report or two cases, *Our J Gastroenterol Hepatol. Case Reports* 13: 707-710.
12. Yang J, Shen L, Zheng X, Zhu Y, Liu Z (2012) Small Bowel stricture complicating Superior Mesenteric Vein Thrombosis. *Case Reports* 32: 146-148.
13. Huh S, Kim D, Lee B (2002) Superior Mesenteric Thrombosis Associated with Small Bowel Stricture. *Case Reports* 43: 895-897.
14. Xu R, Tang L, Wang X, Zhang T, Zhou Z, et al. (2019) Hybrid Therapy consisting of Bowel Resection and Fluoroscopic-assisted Balloon Thrombectomy for Small Bowel Infarction caused by Acute Mesenteric Venous Thrombosis, *Ann Vasc Surg* 59: 202-207.