



## Case Report

# Simultaneous Transaortic Transcatheter Aortic Valve Implantation, Off-Pump Coronary Artery Bypass Grafting and Pulmonary Vein Isolation

Sho Ogiso<sup>1\*</sup>, Tadashi Kitamura<sup>1</sup>, Kentaro Meguro<sup>2</sup>, Junya Ako<sup>2</sup>, Kagami Miyaji<sup>1</sup>

<sup>1</sup>Department of Cardiovascular Surgery, Kitasato University School of Medicine, Kanagawa, Japan

<sup>2</sup>Department of Cardiovascular Medicine, Kitasato University School of Medicine, Kanagawa, Japan

\***Corresponding author:** Sho Ogiso, Department of Cardiovascular Surgery, Kitasato University School of Medicine, 1-15-1 Kitasato, Minami, Sagami-hara, Kanagawa 252-0374, Japan. Tel: +81 42 778 8111; Fax: +81 42 778 9840; Email: ab43cd11a@gmail.com

**Citation:** Ogiso S, Kitamura T, Meguro K, Ako J, Miyaji K (2020) Simultaneous Transaortic Transcatheter Aortic Valve Implantation, Off-Pump Coronary Artery Bypass Grafting and Pulmonary Vein Isolation. Ann Case Report 14: 308. DOI: 10.29011/2574-7754/100308

**Received Date:** 13 January, 2020; **Accepted Date:** 28 April, 2020; **Published Date:** 03 May, 2020

### Abstract

We report the case of an 84-year-old man who presented with severe aortic stenosis, coronary artery in-stent stenosis, atrial fibrillation and significant aortoiliac disease. The patient was successfully treated with simultaneous transaortic transcatheter aortic valve implantation, coronary artery bypass grafting and pulmonary vein isolation through median sternotomy without the use of cardiopulmonary bypass.

**Keywords:** Off-Pump Coronary Artery Bypass; Pulmonary Vein Isolation; Transcatheter Aortic Valve Implantation

### Objective

Ageing of the population has led to an increase in degenerative aortic stenosis in the elderly. Patients of advanced age often have multiple comorbidities and should be treated on a case-by-case basis.

### Introduction

Aortic Stenosis (AS) incidence in moderate- to high-risk elderly patients is increasing. Elderly patients tend to have other comorbidities including coronary artery disease or Atrial Fibrillation (AF), and the treatment strategy has to be planned on a case-by-case basis. We report a case with severe AS complicated by coronary artery disease, AF and significant aortoiliac disease. The patient was treated with simultaneous transaortic Transcatheter Aortic Valve Implantation (TAVI), Off-Pump Coronary Artery Bypass Grafting (OPCAB) and Pulmonary Vein Isolation (PVI) through median sternotomy.

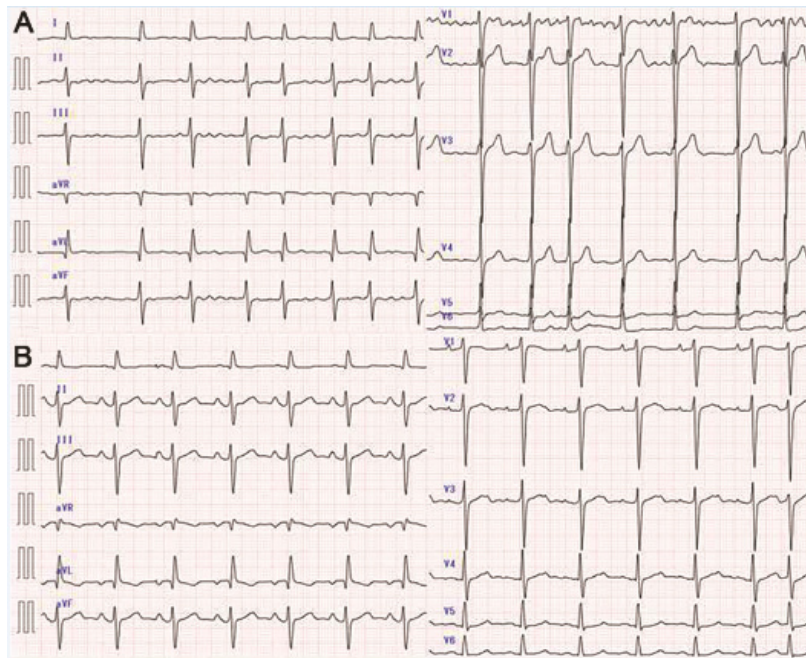
### Case Report

An 84-year-old man, who underwent multiple Percutaneous

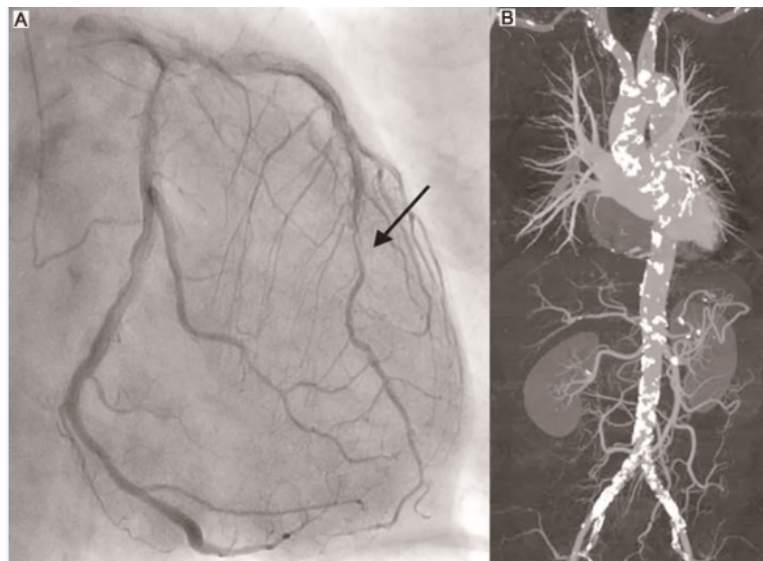
Coronary Interventions (PCI) 10 years before, presented with dyspnoea. Three years before, he was diagnosed with severe AS with a maximum transvalvular Velocity (Vmax) of 4.1 m/s, an Aortic Valve Area (AVA) of 0.6 cm<sup>2</sup> and a Left-Ventricular Ejection Fraction (LVEF) of 73%, but the patient declined surgery at the time. This time, AF was apparent with a heart rate of 90 bpm on the electrocardiogram; Echocardiography showed that Vmax was 3.2 m/s, AVA was 0.7 cm<sup>2</sup> and LVEF was 50% (Figure 1A). Coronary angiography revealed 99% in-stent stenosis in the Left Anterior Descending artery (LAD) (Figure 2A). Computed Tomography Angiography (CTA) showed significant aortoiliac stenosis with severe calcification (Figure 2B). The minimum internal diameter of the iliac artery was 5.0 mm, with full-circumferential calcification, on the right side and 3.9 mm on the left side. The ankle-brachial pressure index was 1.01 on the right side and 0.97 on the left side. The STS predicted risk of mortality score was 4.794%, the EuroSCORE II was 5.15% and the Japan SCORE was 6.2%.

After a detailed discussion with the patient and his family, about the possible treatment options, including the significant risk of postoperative pacemaker implantation, off-pump surgery including transaortic TAVI, OPCAB and PVI was scheduled. After median sternotomy, balloon valvotomy was performed using a transaortic approach under rapid ventricular pacing and a 29-mm

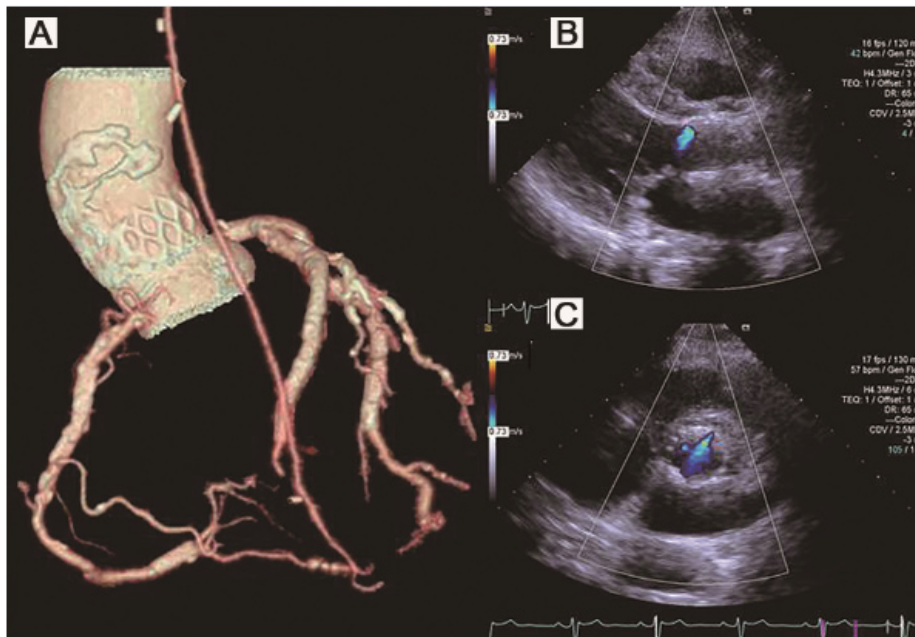
TAVI device (EvolutR, Medtronic, Minneapolis, MN, USA) was positioned over an extra-stiff guidewire under controlled pacing. Subsequently, the Left Internal Mammary Artery (LIMA) was harvested and bilateral PVI was performed using a radiofrequency ablation device (Atricure, Mason, OH, USA). The Left Atrial Appendage (LAA) was suture-closed and the LIMA was anastomosed to the LAD. The patient recovered uneventfully. CTA confirmed the patent bypass graft (Figure 3A). and echocardiography showed a mild paravalvular leak (Figure 3B and 3C). At six months postoperatively, the patient resumed his normal daily activities in NYHA functional class I and remained in sinus rhythm without oral anti-arrhythmic medication (Figure 1B).



**Figure 1:** A Preoperative electrocardiogram showing atrial fibrillation and B electrocardiogram three months after surgery showing sinus rhythm.



**Figure 2:** Preoperative coronary angiogram showing severe in-stent stenosis of the left anterior descending artery (arrow) and B Preoperative Computed Tomography Angiogram (CTA) showing severe aortoiliac disease with calcification.



**Figure 3:** Postoperative coronary CTA showing a patent left internal mammary artery graft. and postoperative echocardiogram showing mild paravalvular leak (B. long axis, C. short axis).

## Discussion

TAVI is a less invasive and very effective alternative to surgical Aortic Valve Replacement (AVR) for high-risk patients, and there is a drive to expand the use of TAVI for treatment of intermediate-risk patients, too; however, there are reports that argue against this expansion [1, 2]. AF, which is also very common in the elderly, is associated with an increased risk of stroke and there are several reports on the efficacy of surgical PVI against AF [3, 4]. When our heart team discussed the present case, proposed strategies included surgical AVR with concomitant coronary bypass and ablation, transapical TAVI with concomitant OPCAB and closure of LAA, transapical TAVI with PCI and catheter ablation, etc. The key discussion points were whether to use cardiopulmonary bypass, and whether to perform median sternotomy. Use of cardiopulmonary bypass would be necessary to perform surgical AVR.

Right side pulmonary vein ablation would be difficult during transapical TAVI through left minithoracotomy. PCI would have low success rate because it was in-stent restenosis. From our recent experience with minimally invasive surgical aortic valve replacement through right mini-thoracotomy, OPCAB and TAVI, off-pump surgery through median sternotomy was chosen as the treatment modality because performing concomitant bilateral PVI through an accustomed approach was thought to be advantageous for the patient. Simultaneous transaortic TAVI and OPCAB is

reported to be a safe and reasonable option for high-risk patients and median sternotomy allows more variations in treatment for AF [5].

## Conclusion

Severe AS, coronary disease and AF in an intermediate-risk patient were successfully treated with simultaneous transaortic TAVI, OPCAB and PVI through median sternotomy. In cases with complex pathology, a heart team approach is essential to assess the risks and benefits of each treatment option.

## Acknowledgement

The authors declare that they have no conflict of interest.

## References

1. Mack MJ, Leon MB, Smith CR, Miller DC, Moses JW, et al. (2015) 5-year outcomes of transcatheter aortic valve replacement or surgical aortic valve replacement for high surgical risk patients with aortic stenosis (PARTNER 1): a randomised controlled trial. *Lancet* 385: 2477-2484.
2. Barili F, Freemantle N, Folliguet T, Muneretto C, De Bonis M, et al. (2017) The flaws in the detail of an observational study on transcatheter aortic valve implantation versus surgical aortic valve replacement in intermediate-risk patients. *Eur J Cardiothorac Surg* 51: 1031-1035.
3. Wolf PA, Abbott RD, Kannel WB (1991) Atrial fibrillation as an independent risk factor for stroke: the Framingham Study. *Stroke* 22: 983-988.

4. Takai H, Miyata H, Motomura N, Sasaki K, Kuniyama T, et al. (2017) Comparison of early outcomes of surgical ablation procedures for atrial fibrillation concomitant to non-mitral cardiac surgery: a Japan Adult Cardiovascular Surgery Database study. *Gen Thorac Cardiovasc Surg* 65: 500-505.
5. Kobayashi J, Shimahara Y, Fujita T, Kanzaki H, Amaki M, et al. (2016) Early Results of Simultaneous Transaortic Transcatheter Aortic Valve Implantation and Total Arterial Off-Pump Coronary Artery Revascularization in High-Risk Patients. *Circ J* 80: 1946-1950.