



## Case Report

# Improving Diagnosis of Dyspnea During Labor using Transesophageal Echocardiography

Chi-An Chen<sup>1</sup>, Hao Tan<sup>1</sup>, Kuang - <sup>1</sup> Cheng<sup>1,2</sup>, Gwo-Ching Sun<sup>1,2\*</sup>

<sup>1</sup>Department of Anesthesiology, Department of Anesthesiology, Kaohsiung Medical University Hospital, Taiwan

<sup>2</sup>Faculty of Medicine, College of Medicine, Kaohsiung Medical University, Taiwan

\***Corresponding author:** Gwo-Ching Sun, Assistant Professor, Department of Anesthesiology, Faculty of Medicine, College of Medicine, Kaohsiung, Medical University, Tzyou 1st Road Kaohsiung 80756, Taiwan. Tel: 886-7-3121101/7033; Fax: 886-7-3217874; Email: gcsun39@yahoo.com.tw

**Citation:** Chen CA, Tan H, Cheng KI, Sun GC (2020) Improving Diagnosis of Dyspnea During Labor using Transesophageal Echocardiography. Ann Case Report 14: 351. DOI: 10.29011/2574-7754/100351

**Received Date:** 14 March, 2020; **Accepted Date:** 21 April, 2020; **Published Date:** 26 April, 2020

### Abstract

**Objective:** Amniotic Fluid Embolism (AFE) is a catastrophic obstetric syndrome which might occur during or after labor with dyspnea. Using Transesophageal Echocardiography (TEE) can improve diagnosis of dyspnea during labor.

**Case Report:** A 25-year old pregnant woman with current episodes of asthma exacerbation, undergoing cesarean section. During the operation, the patient suddenly became respiratory distress combined with bilateral wheezing. The patient was intubated and TEE showed massive pulmonary embolism in Main Pulmonary Artery (MPA). Cardiac surgeon was consulted for possible activation of extra-corporeal membrane oxygenation at that time. However, no emboli were found over MPA under TEE 20 minutes later. The patient successfully recovered, and was discharged in stable condition.

**Conclusion:** The case demonstrates the rare occurrence of AFE in pregnant woman with pre-existing uncontrolled asthma. The case provides the prompt assessments and making an accurate distinction between acute asthma exacerbation and AFE through intraoperative monitoring with TEE during labor.

**Keywords:** Amniotic Fluid Embolism; Asthma; Dyspnea; Echocardiography; Transesophageal

### Introduction

Since Amniotic Fluid Embolism (AFE) was presumably first described in a medical journal eight decades ago, the pathophysiology and prognosis of AFE remain controversial. AFE is a rare but potentially catastrophic obstetric emergency where AFE occurs in two to seven per 100,000 deliveries [1]. AFE is life-threatening which causes death of sudden shock in up to 86% women with AFE during labor [2]. AFE remains unpredictable and unavoidable characters and the new look and novel hypothesis of immunological theory on the pathogenesis of AFE is still unclear and uncertain [2]. Retrospective studies of AFE have confirmed that more than half of the cases did not find the existence of relevant risk factors [3]. AFE is complex in its wide spectrum of clinical manifestations, which often goes unrecognized or misdiagnosed as asthma-related dyspnea or anaphylactic shock [4]. Likewise,

the distinction between causal and non-causal associations is inconsistent and frequently blurred in the medical literature on AFE [3].

AFE still remains a fatal condition unique to obstetrics because of lack of uniform diagnostic criteria, the difficulty of establishing the AFE diagnosis, and insufficient information regarding the clinical condition of women with AFE through any specific diagnostic laboratory tests [3]. When unexpected hemodynamic instability or hypoxemia persistently occurred on pregnant women who have shown poor response to conventional treatment, intraoperative Transesophageal Echocardiography (TEE) can monitor cardiac function and provide effective pathological differential diagnosis and monitoring of cardiac function [5]. We report a 25-year old pregnant woman with current episodes of asthma exacerbation, undergoing cesarean section in an operating room. During the operation, her respiratory condition deteriorated and respiratory distress occurred. We describe the prompt assessments and making an accurate differential diagnosis

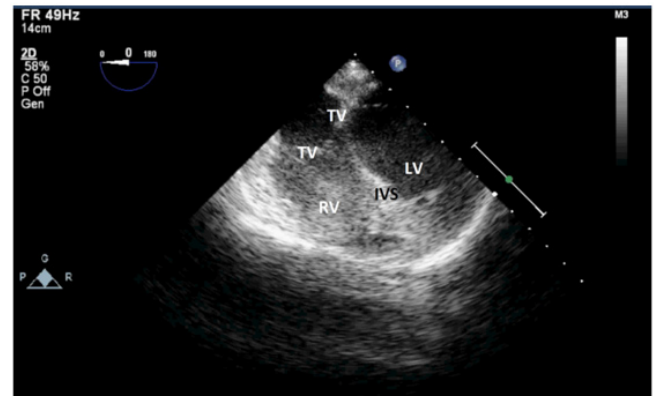
of acute asthma exacerbation and AFE through intraoperative monitoring with TEE during operation. Informed consent was obtained from the patient for publication of this case report.

## Case Report

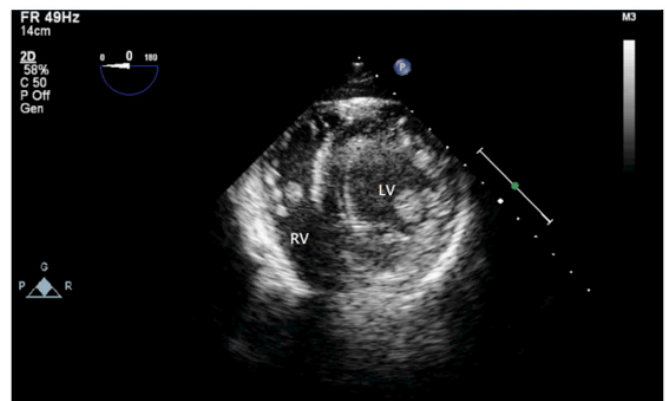
A 25-year-old woman (G3P2A0) with pregnancy age of 38<sup>+</sup>5 weeks admitted to accept planned cesarean section, which had been done on 2012 and 2013. Tracing back her medical history, she is a hepatitis B virus carrier and has asthma without regular medication control. She also denied any allergy history and drug use. This patient had regular prenatal examination at our hospital without any fetus abnormally founded. Standard physiological monitors were set preoperatively. Epidural anesthesia (Lumbar two-three) was provided with total medication dose of two % lidocaine 300 mg epidurally (including 60 mg test dose) with the analgesia level around the sixth thoracic dermatome (by both thermoception and pinprick test) to make adequate operation condition. The operation started smoothly and this patient remained spontaneous ventilation with nasal cannula oxygen (two L/min) supply under stable condition.

A male baby was born with the APGAR score 8<sup>'</sup>-9<sup>'</sup>. 15 minutes after the delivery of placenta, dyspnea combined with hypoxia (SpO<sub>2</sub> from 98% to 90%) and hypotension (NIBP from 120/55 mmHg to 50/30 mmHg), associated with obvious tachycardia (HR 90 bpm to 120 bpm), followed by conscious loss of this woman. Emergent endotracheal intubation was done before central venous catheter and invasive radial artery catheter insertion. Arterial blood gas revealed respiratory acidosis, high arterial-alveolar CO<sub>2</sub> gradient and hypoxemia (pH: 7.30, PaCO<sub>2</sub>: 79.4 mmHg, HCO<sub>3</sub><sup>-</sup>: 24.9 mmol/L, EtCO<sub>2</sub>: 27 mmHg, PaO<sub>2</sub>: 62.3 mmHg, SaO<sub>2</sub>: 81.2%). Due to condition above, FiO<sub>2</sub> was adjusted to 100% with infusion of norepinephrine and epinephrine. Salbutamol three puff through endotracheal administration and hydrocortisone 100 mg intravenously were given according to bilateral wheezing was auscultated and the underlying disease of asthma.

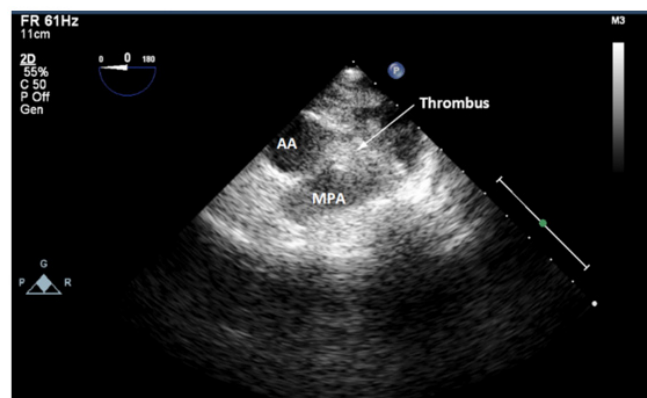
To make clear differential diagnosis and sure current treatment plan, TEE was used. No obvious regional wall motion abnormality was found but dilation over Right Ventricle (RV) and Main Pulmonary Artery (MPA) were discovered, a fluffy mass was also found in MPA (Figure 1-3). Cardiac surgeon was consulted for the suspicion of pulmonary embolism (AFE or thromboemboli) and possible activation of Extra-Corporeal Membrane Oxygenation (ECMO). The catastrophic condition had become hemodynamic stable with follow-up arterial blood gas analysis reported no abnormal finding. No emboli were found over MPA under TEE 20 minutes later (Figure 4). We then used sevoflurane to maintain adequate anesthesia level. No any adverse events were recorded till the end of the surgery.



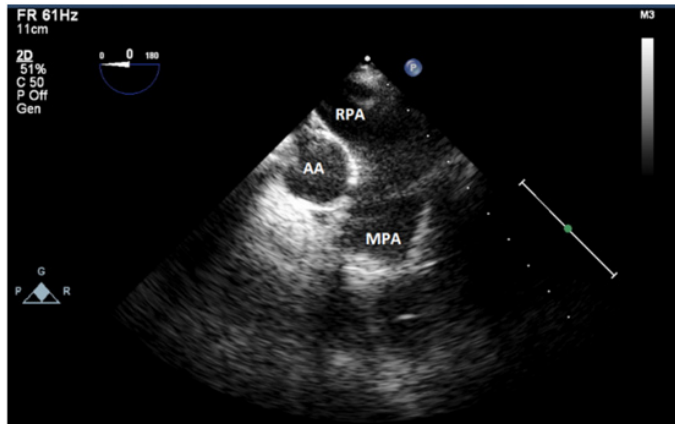
**Figure 1:** 2D TEE mid-esophageal four-chamber view showing RV dilation with IVS deviation. Note the dilated RV with IVS bulging toward the LV. RV: Right Ventricle; LV: Left Ventricle; IVS: Intraventricular Septum; TV: Tricuspid Valve.



**Figure 2:** 2D TEE transgastric short axis view showing RV hypokinesia. Note the adequate LV wall motion but impaired RV motion with RV dilation. RV: Right Ventricle; LV: Left Ventricle.



**Figure 3:** 2D TEE midesophageal ascending aortic short-axis view of the MPA showing a large pulmonary embolus. A large thrombus measuring 10 by 10 mm was visualized in the MPA. AA: Ascending Aorta; RPA: Right Pulmonary Artery; MPA: Main Pulmonary Artery.



**Figure 4:** 2D TEE midesophageal ascending aortic short-axis view. After 20 minutes and successful resuscitation, no obvious thrombus was noted over MPA. AA: ascending aorta; MPA: main pulmonary artery; RPA: Right Pulmonary Artery.

Patient was transferred to Intensive Care Unit (ICU) for further care after resuscitation. Disseminated Intravascular Coagulation (DIC) profile such as D-dimer, Fibrin Degradation Products (FDPs) were negative, and International Normalized Ratio (INR) were also within normal range both intra- and post-operatively. Bedside Transthoracic Echocardiogram (TTE) reported no emboli over MPA and other region during ICU stay as well as computed tomography angiography reported no overt radiological evidence of thromboembolism in the main trunk of the pulmonary arteries. The image survey was consistent with our intraoperative TEE findings after successful resuscitation. This patient transferred to general ward three days later and discharged after a week. No adverse event was noted at outpatient department follow up.

## Discussion

This patient did not match the common risk factors of AFE, such as older than 35 y/o, no C/S, instrumental or vacuum-assisted vaginal delivery, placental previa, preclampsia and fetal distress [6]. However, some study had concluded that C/S and multiple pregnancy had strong association with AFE [7]. In addition, specific delivery methods like induction with prostaglandin had increased six times risk of AFE and two times risk if prostaglandin was used during labor [6]. Interestingly, obstetrician in our hospital use prostaglandin for induction and oxytocin to promote uterine contraction and control post-partum hemorrhage. All of the intervention above increased AFE mortality and morbidity. Early recognition and intervention raise the survival of patient with AFE [2]. Besides, it's challenging since there was no specific pathological or serological marker of AFE and we could make the diagnosis for excluding other common diseases [3]. The triad of

AFE includes acute respiratory distress, hemodynamic collapse and coagulopathy but those symptoms were not sensitive or specific [3].

Therefore, AFE was considered after excluding other diagnosis. Moreover, AFE also comes with acute pulmonary hypertension induced ventilation/perfusion mismatch and cardiogenic/non-cardiogenic pulmonary edema, both worsening dyspnea and tachypnea, wheezing and crackles [2]. It is struggle for physicians to make diagnosis especially in patients with pre-existing airway disease such as asthma. During the operation, bilateral wheezing was noted on this case, which might originate from either bronchospasm or pulmonary edema. The possible causes could be asthma acute attack or bronchospasm induced negative intrathoracic pressure which decreases pulmonary interstitial pressure. An increase in the pressure gradient originates from filtration of edema fluid into the lung, leading to pulmonary edema. Wheezing might also have originated from AFE induced pulmonary edema, in addition. Without intraoperatively TEE examination, this patient might be treated as status asthmaticus.

By this case, we consider higher prevalence of AFE induced pulmonary edema and the following bronchospasm. However, TEE is not always sufficient to confirm the location of the thrombus, since it may have moved after the initial positive result. Although it is believed that active bleeding is the main character of AFE, all patients who survive from AFE have either clinical or laboratory evidence of a consumptive coagulopathy, many in vitro studies proved that clear amniotic fluid was not enough to trigger obvious clinically intravascular coagulation [8]. In the contrast, Harnett et al, who used thromboelastography analysis to demonstrate that the addition of amniotic fluid on blood causes significantly accelerated coagulation related to the procoagulant activity of amniotic fluid and enhanced platelet activation [8]. Thus there is still uncertain whether AFE comes with coagulopathy.

## Conclusion

AFE is a catastrophic obstetric syndrome which might occur during or after labor with acute onset shortness of breath or cardiovascular collapse. In women with a history of asthma who expressed dyspnea, TEE contributes to make the accurate distinction between acute asthma exacerbation and AFE. Moreover, TEE also help us understand the pathophysiological change and further treatment. In conclusion, TEE has become a real-time and trustful diagnosis tool for AFE.

## Conflicts of Interest

We declare no conflicts of interest to declare.

## Acknowledgement

No.

## Author Contributions

C.A. Chen and H. Tan acquired the data and drafted the manuscript. G.C. Sun and K.I. Cheng conceived the study and revised the manuscript for important intellectual content. All authors read and approved the final manuscript.

## Reference

1. Knight M, Tuffnell D, Brocklehurst P, Spark P, Kurinczuk JJ, et al. (2010) Incidence and risk factors for amniotic-fluid embolism. *Obstet Gynecol* 115: 910-917.
2. Kaur K, Bhardwaj M, Kumar P, Singhal S, Singh T, et al. (2016) Amniotic fluid embolism. *J Anaesthesiol Clin Pharmacol* 32: 153-159.
3. Shamshirsaz AA and Clark SL (2016) Amniotic Fluid Embolism. *Obstet Gynecol Clin North Am* 43: 779-790.
4. Romero R, Kadar N, Vaisbuch E, Hassan SS (2010) Maternal death following cardiopulmonary collapse after delivery: amniotic fluid embolism or septic shock due to intrauterine infection? *Am J Reprod Immunol* 64: 113-125.
5. Katz J, Shear TD, Murphy GS, Alspach D, Greenberg SB, et al. (2017) Cardiovascular Collapse in the Pregnant Patient, Rescue Transesophageal Echocardiography and Open Heart Surgery. *J Cardiothorac Vasc Anesth* 31: 203-206.
6. Fitzpatrick KE, Tuffnell D, Kurinczuk JJ, Knight M (2016) Incidence, risk factors, management and outcomes of amniotic-fluid embolism: a population-based cohort and nested case-control study. *BJOG* 123: 100-109.
7. Knight M, Berg C, Brocklehurst P, Kramer M, Lewis G, et al. (2012) Amniotic fluid embolism incidence, risk factors and outcomes: a review and recommendations. *BMC Pregnancy Childbirth* 12: 7.
8. Harnett MJ, Hepner DL, Datta S, Kodali BS (2005) Effect of amniotic fluid on coagulation and platelet function in pregnancy: an evaluation using thromboelastography. *Anaesthesia* 60: 1068-1072.