



Benefit of Long-Term Adjunctive Low-Carbohydrate Diet with Intranasal Perillyl Alcohol Therapy in the Progression-Free Survival of a Patient with Glioblastoma: A Case Report and Literature Review

Juliana Guimarães Santos^{1*}, Wanise Maria Souza Da Cruz², Axel H Schönthal³, Cristina Asvolinsque Pantaleão Fontes⁴, Thereza Quirico-Santos⁵ and Clovis Orlando da Fonseca^{6*}

¹Graduate Program in Medical Sciences, Universidade Federal Fluminense, Niterói, RJ, Brazil

²Department of Nutrition, Universidade Federal Fluminense, Niterói, RJ, Brazil

³Department of Molecular Microbiology & Immunology, Keck School of Medicine, University of Southern California, Los Angeles, USA

⁴Service of Radiology, Department of Radiology, Antonio Pedro University Hospital, Universidade Federal Fluminense, Niterói, RJ, Brazil

⁵Department of Cellular and Molecular Biology, Institute of Biology, Universidade Federal Fluminense, Niterói, RJ, Brazil

⁶Service of Neurosurgery, Department of General and Specialized Surgery, Antonio Pedro University Hospital, Universidade Federal Fluminense, Niterói, RJ, Brazil

*Corresponding author(s): Juliana Guimaraes Santos, Universidade Federal Fluminense, Niterói, Rio de Janeiro, Brazil

Clovis Orlando da Fonseca, Service of Neurosurgery, Department of General and Specialized Surgery, Antonio Pedro University Hospital, Universidade Federal Fluminense, Niterói, RJ, Brazil

Citation: Santos JG, Da Cruz WMS, Schönthal AH, Fontes CAP, Quirico-Santos T, et al. (2020) Benefit of Long-Term Adjunctive Low-Carbohydrate Diet with Intranasal Perillyl Alcohol Therapy in the Progression-Free Survival of a Patient with Glioblastoma: A Case Report and Literature Review. J Surg 5: 1292. DOI: 10.29011/2575-9760.001292

Received Date: 22 February, 2020; **Accepted Date:** 04 March, 2020; **Published Date:** 09 March, 2020

Abstract

Introduction: Glioblastoma (GB) remains difficult to treat with patient survival at around 14 months. Standard treatment consists of surgery, radiation and chemotherapy with Temozolomide (TMZ). This approach to GB disrupts the glutamate-glutamine cycle, enhancing the availability of glutamine and glucose in the GB microenvironment. The presence of these two metabolites induces rapid growth of GB. Dietary calorie restriction, i.e. low glycemic index nutritional intervention, is proposed to simultaneously reduce glucose and glutamine availability for GB cells, and thus should exert therapeutic efficacy. Our previous clinical studies indicated that this dietary intervention, when associated with intranasal Perillyl Alcohol (POH), may reduce glucose available while increase the concentration of ketone bodies, which are neuroprotective and non-fermentable.

Case Presentation: A 26-year-old woman was newly diagnosed with GB in August/2013. The methylation status of MGMT was negative. She underwent standard of care therapy, but treatment with TMZ induced adverse effects and therefore was suspended in September/2014. Thus, the patient starts therapeutic strategy combining Low Carbohydrate Diet (LCD) with POH via the intranasal route. Her progress was monitored by clinical reviews, periodic Magnetic Resonance (MR) exams and quality of life questionnaires.

Results: The combination of dietary intervention with inhaled POH was well-tolerated. After 5 years of continued administration of this strategy, the patient presented with progression-free survival, absence of seizures, improved quality of life, reduced body weight by about 15%, and no requirement for corticosteroids. Follow-up MRI showed no tumor progression.

Conclusion: Due to the huge percentage of GB relapse following standard therapy, it is plausible to credit the response obtained in this case to this innovative therapeutic strategy. Further clinical studies of GB patient's refractory to standard treatment are needed to prove the effectiveness of this therapeutic strategy.

Keywords: Glioblastoma; Intranasal; Low carb diet; Metabolic therapy; Perillyl alcohol; Quality of life

Introduction

Glioblastoma (GB) has the highest mortality rates among brain tumors with an incidence of 3.2/100,000 population/year [1]. Median life expectancy following newly-diagnosed GB is short. Patients who are robust enough to participate in clinical trials, such as the landmark “Stupp trial” that introduced the combination of radiation with Temozolomide (TMZ) [2,3] show median Overall Survival (OS) of about 15 months. However, many patients are frail and/or very old and therefore unable to receive all aspects of standard of care. As a result, the median OS for the entirety of GB patients seen in the clinic is significantly lower, and is estimated at about 1 year after diagnosis [4,5]. Studies exploring new treatments are urgently required. It has been recognized that ablation surgical intervention and radiation therapy induce extensive hypoxia and necrosis in the GB tumor microenvironment [6]. As well, GB patients are known to have significant immune deficient status at time of diagnosis [7] and this immunosuppression is worsened by TMZ treatment [8]. Lawrence et al. studied patients with high-grade gliomas that were treated with surgery followed by chemoradiation and established that early toxicity predicted poorer overall survival in these patients [9]. GB invariably recurs as a highly infiltrative and aggressive phenotype, with the majority of recurrences within the area targeted by radiation treatment. Further, these authors showed that surgical resection and radiotherapy cause damage in the tumor microenvironment, which will increase the glycolytic rate for the remaining glial tumor cells, promoting tumor growth and resistance to therapy through hyperglycolysis [10].

The tumor-induced brain edema routinely requires the prescription of corticosteroid dexamethasone together with conventional treatment. While it has shown inhibitory effects on GB cell proliferation and migration [11], dexamethasone further increases blood glucose levels, as well as glutamine levels by inducing glutamine synthetase activity [12]. In this context, studies indicate that both carbohydrate glucose and the amino acid glutamine are fermentable fuels that create an environment favorable to the rapid growth of most tumors, including GB [13]. Other studies have indicated that the survival of GB patients with higher blood glucose levels is lower than in GB patients with lower glucose levels [14]. These studies suggested that GB could be considered a metabolic disease.

Among the striking features of GB is its high invasiveness, which takes place by diffuse parenchymal invasion through Virchow-Robin space [15]. These invasive pathways involve complex interactions between GB cells, extracellular matrix and white matter. In this way, the high potential for infiltration and

invasion makes most current therapies ineffective and facilitates GB recurrence. Therefore, to further improve GB treatment, it is necessary to fully understand the key features of the GB microenvironment and explore it as a therapeutic target.

Given the above, our group has been investigating a non-toxic therapeutic strategy that targets GB-specific metabolic defects and reduces edema and inflammation of the microenvironment. In particular, we have been developing a therapeutic regimen that combines a low-carbohydrate diet with administration of POH through the nasal route. The rationale behind significantly reduced carbohydrate intake lies in the expectation that lowering glucose levels will suppress the Warburg effect and, at the same time, will elevate ketone bodies that cannot be metabolized to energy in tumor cells, due to their defects in the mitochondrial structure [16]. POH is a non-toxic, naturally-occurring monoterpene with inherent anticancer properties [17,18]. POH is an amphipathic molecule with a high partition coefficient; it has been suggested that its interaction along the acyl-lipid tails of the cell membrane lipid bilayer disrupts the integrity and biophysical properties of this membrane, leading to the inhibition of cellular signal transduction [19]. Also POH exhibits cytotoxicity against TMZ-resistant glioma cells, regardless of the methylation status of the O6-methylguanine-methyltransferase gene [20], which encodes a key DNA repair enzyme that provides resistance to TMZ [21]. Clinical studies in patients with gliomas treated with intranasal POH have shown encouraging results, indicating therapeutic activity along with good tolerance and no long-term severe adverse events, even after years of administration on a daily basis [22-24]. Our previous clinical study suggests therapeutic response to intranasal POH combined with low-carbohydrate diet in patients with recurrent gliomas [25]. Here, we report the case of a patient with GB who has been treated for 5 years with this therapeutic combination

Case Presentation

Fluminense Federal University approved the present study (CAAE: 14613313.8.0000.5243), which was performed at the University Hospital Antonio Pedro. A written informed consent form was signed by the patient before enrollment. Formulation of POH for intranasal delivery was accomplished by Laboratories of Pharmaceutical Sciences at the Rio de Janeiro Federal University. Administration of POH to the patient was by inhalation from a nebulizer 4 times daily. Each dose was 55 mg (0.3% v/v), totaling 220 mg/day. A 26-year-old Caucasian woman with no significant prior medical record or family history of brain tumor or neurological disorders presented with symptoms of intracranial hypertension in September/2013. A magnetic resonance (MR) brain scan revealed a space-occupying lesion located in the mid-frontal region measuring approximately 6.1 x 5.7 cm that was enhanced with gadolinium (Figure 1).

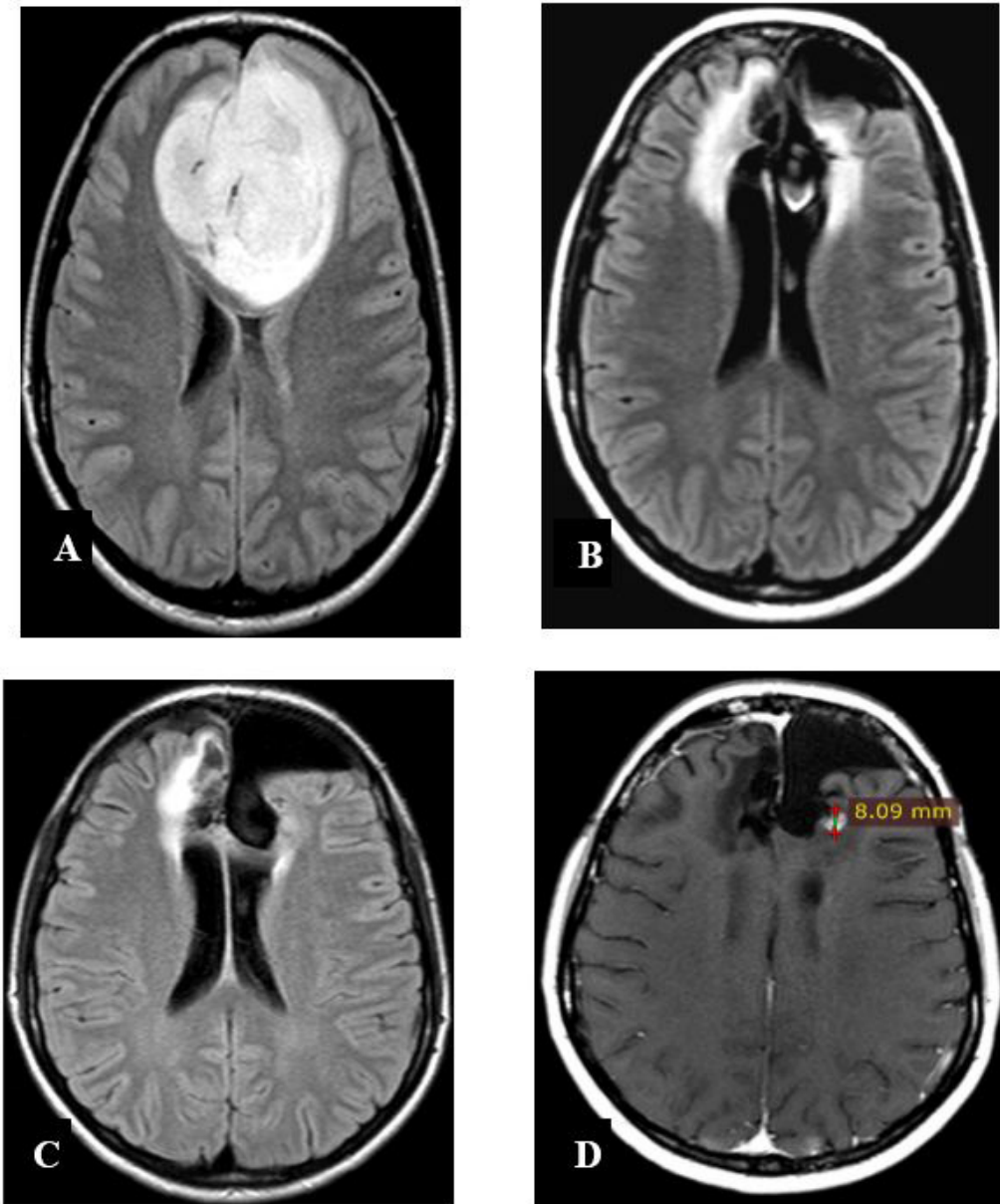


Figure 1: Brain MRI. In A, the diagnostic exam in Sep/2013 with axial FLAIR shows an ill-defined frontal mass that compresses the corpus callosum, measuring approximately 6.1 x 5.7 cm. In B, a follow-up exam was performed in Aug/2014, at the time when the standard treatment with TMZ was withdrawn. In C, an exam in Sep/2019 shows reduction of tumor volume after 5 years of low carb diet combined with intranasal POH. In D, follow-up Axial T1 with contrast exam performed in Jan/2020, the lesion persists with the same dimensions, but the contrast enhancement is less homogeneous.

The patient underwent a bifrontal craniotomy with radical resection of the primary brain tumor in October 2013. After the surgical procedure, an MR scan was used to confirm tumor resection. The diagnosis of malignant glioma was confirmed based on complex histological features characterized by ischemic necrosis and glomeruloid microvascular proliferation. Immunohistochemical analysis of tumor tissue turned out negative for MGMT promoter methylation. The patient underwent radiation therapy (59.4 Gy total) concomitant with TMZ-based chemotherapy (75 mg every day) over the course of 6 weeks. After conclusion of concomitant chemo-radiation intervention, the patient received TMZ only (150-200 mg) during the adjuvant phase, based on the standard 28-day cycle (5 days on/23

days off), for a total of 6 cycles. Thereafter, the MR scan showed a reduction in the tumoral lesion (Figure 1). However, the treatment with TMZ was withdrawn when the patient had thrombocytopenia and leukopenia.

In September/2014, the patient was enrolled in a new clinical trial where adjunctive LCD therapy was combined with intranasal POH. The LCD was composed of the following: energy (25 kcal/kg); 1.5 g/kg protein; 25% carbohydrate; and 50% lipids (cholesterol=200 mg/day; saturated fat<7%; polyunsaturated fat<10%, monounsaturated fat <20%, and fibers between 20-30 g/day). The amount of ketone bodies was measured in the urine throughout the course of treatment and shown to remain between 5-15 mg/dl, thus confirming adherence to the LCD. Overall, the diet combined with daily intranasal POH was well-tolerated; there was a reduction in body weight by about 15%, and no adverse events were reported. After 5 years of daily administration of this therapeutic regimen (LCD + POH), the patient remains in excellent health, with no steroid medication and no anti-seizure medication. Her Karnofsky score is at 100%. Follow-up resonance imaging for verification of tumor volume was conducted every three months for five years and revealed reduction of the enhancing lesion with no tumor recurrence (Figure 1).

Discussion

The current case report describes a favorable therapeutic response of a patient with GB treated with adjunctive low-carbohydrate diet therapy combined with intranasal POH continuously over five years without side effects. Clinical data showed that the patient had progression-free survival, improved quality of life, and is not taking corticosteroids and anticonvulsants. Control MRs evidenced reduction of the lesion, which remained controlled and showed no progression of the tumor. Before starting this combination therapy, the patient had favorable response to temozolomide chemotherapy over 7 months, but then developed severe thrombocytopenia that required discontinuation of TMZ. The currently used standard chemotherapy for GB patients is TMZ, which usually is orally administered. In fact, the oral route is the most comfortable for the administration of chemotherapy patients. However, for the pharmacological treatment, it is essential for drugs to reach the brain in their bioactive form. Yet, the therapeutic agent has to overcome several biological barriers when orally administered, such as enzymatic degradation, first-pass metabolism, and blood brain barrier [26]. In contrast, the intranasal route of administration, potentially presents several advantages over the oral route for administering chemotherapeutic drugs [27]. In this context, our group has been developing for two decades the innovative formulation of intranasal POH, an inhibitor of the angiogenic process and potent modulator of ROS activity [17], aiming for treatment of GB [19,22-24].

Here is what Seyfried said about current GB treatment stage: “A recent reevaluation found that overall survival for GB (8-14 months) is woefully similar to that reported by Bailey and Cushing almost a century ago” [28]. This assertion, while true, is extremely worrying. The question is, what can the modern science offer in terms of increased survival for patients with GB? In this context, authors discovered that surgical ablation and radiotherapeutic intervention resulted in significant necrosis and hypoxia within the microenvironment of the tumor [29,30]. It is noteworthy that newly-diagnosed GB patients are known to have significant immune dysfunction [31]. This immunosuppression is worsened by standard TMZ chemotherapy [32]. Also, prolonged TMZ chemotherapy does not significantly increase progression-free survival or overall survival in patients with new GB [26]. As well, it is reasonable to consider the presence of edema as an additional factor to be taken into account when mapping out strategies for the treatment of malignant gliomas. Peritumoral edema is thought to occur due to extravasation of plasma liquid and macromolecules through an altered blood-brain barrier [27,33], but the exact mechanism by which it occurs is poorly understood. Studies established that in order to sustain rapid growth, GB cells modify their metabolic activity by increasing glycolysis even when ample oxygen is present, requiring high levels of glucose uptake, known as the Warburg effect [34]. At this crucial point, several studies demonstrated that calorie restriction and low-carbohydrate, high-fat diet reduces the glucose needed to drive the Warburg effect, while at the same time elevating ketone bodies that cannot be metabolized for energy in tumor cells, due to their defects in mitochondrial structure and function [35,36]. Therefore, it is reasonable to expect that dietary modifications and related pharmacological interventions could potentially become effective treatment additions that might synergize with classical cytotoxic treatments or with molecularly targeted therapies. In fact, our clinical studies with recurrent GB patients [25] suggested clinical benefit of nutritional interventions, when ketogenic or low-glycemic diets were combined with intranasal POH. In this present case report, we show that this strategy correlated with an absence of GB relapse.

It is particularly noteworthy that tumor tissue from this patient tested negative for MGMT promoter methylation, indicating expression of MGMT protein. MGMT is a DNA repair protein that effectively repairs, and thus neutralizes, the main toxic event of TMZ, i.e., DNA methylation at the O6-position of guanine. A large number of studies established that MGMT-expressing tumor cells are highly resistant to TMZ *in vitro* and *in vivo* [37], and it is commonly observed in the clinic that GB patients with unmethylated MGMT promoter face significantly poorer prognosis than those with silenced MGMT [38]. For example, the landmark “Stupp trial” established median overall survival of 12.6 months vs. 23.4 months for GB patients with unmethylated vs.

methylated MGMT promoter and receiving radiotherapy + TMZ [2,3]. In comparison, the GB patient described in this case study is still alive at 6 years post initial diagnosis. Encouraged by this promising result in connection with our new treatment strategy, we suggest further research to dietary intervention and intranasal POH to the available regimens of GB treatment.

References

- Ostrom QT, Gittleman H, Liao P, Rouse C, Chen Y, et al. (2014) CBTRUS statistical report: primary brain and central nervous system tumors diagnosed in the United States in 2007-2011. *Neuro-Oncol* 16: iv1-63.
- Stupp R, Hegi ME, Mason WP, van den Bent MJ, Taphoorn MJ, et al. (2009) Effects of radiotherapy with concomitant and adjuvant temozolomide versus radiotherapy alone on survival in glioblastoma in a randomised phase III study: 5-year analysis of the EORTC-NCIC trial. *Lancet Oncol* 10: 459-466.
- Stupp R, Mason WP, van den Bent MJ, Weller M, Fisher B, et al. (2005) Radiotherapy plus concomitant and adjuvant temozolomide for glioblastoma. *N Engl J Med* 352: 987-996.
- Johnson DR, O'Neill BP (2012) Glioblastoma survival in the United States before and during the temozolomide era. *J Neurooncol* 107: 359-364.
- SEER, Surveillance, Epidemiology, and End Results (SEER) Program.
- Monteiro AR, Hill R, Pilkington GJ, Madureira PA (2017) The Role of Hypoxia in Glioblastoma Invasion. *Cells* 6: 45.
- Mohme M, Schliffke S, Maire CL, Rüniger A, Glau L, et al. (2018) Immunophenotyping of Newly Diagnosed and Recurrent Glioblastoma Defines Distinct Immune Exhaustion Profiles in Peripheral and Tumor-infiltrating Lymphocytes. *Clin Cancer Res* 24: 4187-4200.
- Campian JL, Piotrowski AF, Ye X, Hakim FT, Rose J, et al. (2017) Serial changes in lymphocyte subsets in patients with newly diagnosed high grade astrocytomas treated with standard radiation and temozolomide. *J. Neurooncol* 135: 343-351.
- Lawrence YR, Wang M, Dicker AP, Andrews D, Curran WJ Jr, et al. (2011) Early toxicity predicts long-term survival in high-grade glioma. *Br J Cancer* 104: 1365-1371.
- Duan C, Yang R, Yuan L, Engelbach JA, Tsien CI, et al. (2019) Late effects of radiation prime the brain microenvironment for accelerated tumor growth. *Int J Radiat Oncol Biol Phys* 103: 190-194.
- Marta Cenciarini, Mario Valentino, Silvia Belia, Luigi Sforma, Paolo Rosa, et al. (2019) Dexamethasone in Glioblastoma Multiforme Therapy: Mechanisms and Controversies. *Front Mol Neurosci* 12: 65.
- Wong ET, Lok E, Gautam S, Swanson KD (2015) Dexamethasone exerts profound immunologic interference on treatment efficacy for recurrent glioblastoma. *Br J Cancer* 113: 232-241.
- Marquez J, Alonso FJ, Mates JM, Segura JA, Martín-Rufián M, et al. (2017) Glutamine addiction in gliomas. *Neurochem Res* 42: 1735-1746.
- Tieu MT, Lovblom LE, McNamara MG, Mason W, Laperriere N, et al. (2015) Impact of glycemia on survival of glioblastoma patients treated with radiation and temozolomide. *J. Neurooncol* 124: 119-126.
- Kwee RM, Kwee TC (2007) Virchow-Robin Spaces at MR Imaging 27: 1071-1086.
- Winter SF, Loebel F, Dietrich J (2017) Role of Ketogenic Metabolic Therapy in Malignant Glioma: A Systematic Review. *Crit Rev Oncol Hematol* 112: 41-58.
- Chen TC, Fonseca CO, Schönthal AH (2015) Preclinical development and clinical use of perillyl alcohol for chemoprevention and cancer therapy. *Am J Cancer Res* 5: 1580-1593.
- Gomes AC, Mello AL, Ribeiro MG, Garcia DG, Da Fonseca CO, et al. (2017) Arch Immunol Ther Exp (Warsz). Perillyl alcohol, a pleiotropic natural compound suitable for brain tumor therapy, targets free radicals 65: 285-297.
- Da Fonseca CO, Khandelia H, Salazar MD, Schönthal AH, Meireles OC, et al. (2016) Perillyl alcohol: Dynamic interactions with the lipid bilayer and implications for long-term inhalational chemotherapy for gliomas. *Surg Neurol Int* 5: 7-1.
- Cho HY, Wang W, Jhaveri N, Torres S, Tseng J, et al. (2012) Perillyl alcohol for the treatment of temozolomide-resistant gliomas. *Mol Cancer Ther* 11: 2462-2472.
- Hegi ME, Diserens AC, Gorlia T, Hamou MF, de Tribolet N, et al. (2005) MGMT gene silencing and benefit from temozolomide in glioblastoma. *N Engl J Med* 352: 997-1003.
- Da Fonseca CO, Schwartsmann G, Fischer J, Nagel J, Futuro D, et al. (2008) Preliminary results from a phase I/II study of perillyl alcohol intranasal administration in adults with recurrent malignant gliomas. *Surg Neurol* 70: 259-267.
- Da Fonseca CO, Simão M, Lins IR, Caetano RO, Futuro D, et al. (2011) Efficacy of monoterpene perillyl alcohol upon survival rate of patients with recurrent glioblastoma. *J Cancer Res Clin Oncol* 137: 287-293.
- Da Fonseca CO, Teixeira RM, Silva JC, DE Saldanha DA, Gama Fischer J, et al. (2013) Long-term outcome in patients with recurrent malignant glioma treated with Perillyl alcohol inhalation. *Anticancer Res* 33: 5625-5631.
- Santos JG, Souza Da Cruz WM, Schonthal AH, Salazar MD, Fontes CA, et al. (2018) Efficacy of a ketogenic diet with concomitant intranasal perillyl alcohol as a novel strategy for the therapy of recurrent glioblastoma. *Oncol Lett* 15: 1263-1270.
- Gilbert MR, Wang M, Aldape KD, Stupp R, Hegi ME, et al. (2013) Dose-dense temozolomide for newly diagnosed glioblastoma: A randomized phase III clinical trial. *J Clin Oncol* 31: 4085-4091.
- Alphandéry E (2018) Glioblastoma Treatments: An Account of Recent Industrial Developments. *Front Pharmacol* 13: 9-879.
- Seyfried TN, Shelton L, Arismendi-Morillo G, Kalamian M, Elsakka A, et al. (2019) Provocative Question: Should Ketogenic Metabolic Therapy Become the Standard of Care for Glioblastoma? *Neurochem Res* 44: 2392-2404.

29. Lawrence YR, Blumenthal DT, Matcyevesky D, Kanner AA, Bokstein F, et al. (2011) Delayed initiation of radiotherapy for glioblastoma: how important is it to push to the front (or the back) of the line? *J Neurooncol* 105: 1-7.
30. Laws ER Jr, Goldberg WJ, Bernstein JJ (1993) Migration of human malignant astrocytoma cells in the mammalian brain: Scherer revisited. *Int J Dev Neurosci* 11: 691-697.
31. Mohme M, Schliffke S, Maire CL, Rüniger A, Glau L, et al. (2018) Immunophenotyping of Newly Diagnosed and Recurrent Glioblastoma Defines Distinct Immune Exhaustion Profiles in Peripheral and Tumor-infiltrating Lymphocytes. *Clin Cancer Res* 24: 4187-4200.
32. Campian JL, Piotrowski AF, Ye X, Hakim FT, Rose J, et al. (2017) Serial changes in lymphocyte subsets in patients with newly diagnosed high grade astrocytomas treated with standard radiation and temozolomide. *J Neurooncol* 135: 343-351.
33. Arismendi-Morillo G, Castellano A (2005) Tumoral micro-blood vessels and vascular microenvironment in human astrocytic tumors. A transmission electron microscopy study. *J Neurooncol* 73: 211-217.
34. Lu J, Tan M, Cai Q (2015) The Warburg effect in tumor progression: mitochondrial oxidative metabolism as an anti-metastasis mechanism. *Cancer Lett* 356: 156-164.
35. Zhou W, Mukherjee P, Kiebish MA, Markis WT, Mantis JG, et al. (2007) The calorically restricted ketogenic diet, an effective alternative therapy for malignant brain cancer. *Nutr Metab* 21: 4-5.
36. Maroon JC, Seyfried TN, Donohue JP, Bost J (2015) The role of metabolic therapy in treating glioblastoma multiforme. *Surg Neurol Int* 6: 61.
37. Kaina B, Christmann M (2019) DNA repair in personalized brain cancer therapy with temozolomide and nitrosoureas. *DNA Repair (Amst)* 78: 128-141.
38. Silber JR, Bobola MS, Blank A, Chamberlain MC (2012) O(6)-methylguanine-DNA methyltransferase in glioma therapy: promise and problems. *Biochim Biophys Acta* 1826: 71-82.