



Case Report

Asymptomatic Chronic Ischemic Penumbra from Middle Cerebral Artery Occlusion: A Case Report and Literature Review

Alexander J Sweidan* and Wengui Yu

Department of Neurology, University of California, Irvine, USA

*Corresponding author: Alexander J Sweidan, Department of Neurology, 200 S. Manchester Ave., Suite 206, Orange, CA 92868, USA. Email: asweidan@uci.edu

Citation: Sweidan AJ and Yu W (2020) Asymptomatic Chronic Ischemic Penumbra from Middle Cerebral Artery Occlusion: A Case Report and Literature Review. Ann Case Report 14: 337. DOI: 10.29011/2574-7754/100337

Received Date: 16 February, 2020; Accepted Date: 05 March, 2020; Published Date: 11 March, 2020

Abstract

Acute Middle Cerebral Artery (MCA) occlusion typically causes large hemispherical infarct within hours. However, cellular viability can be maintained in part of the brain tissue for days or months if there is good collateral circulation. We report a case of asymptomatic chronic ischemic penumbra from right MCA occlusion.

Introduction

Acute occlusion of the Middle Cerebral Artery (MCA) leads to permanent tissue damage and neurological deficit that are proportional to the duration of occlusion [1-3]. A cerebral blood flow of 8-23 ml/100 gram/min may be sufficient for cellular viability but insufficient for normal tissue function. Such potentially salvageable ischemic penumbra was originally described by Astrup et al [1]. Currently, CT perfusion imaging is routinely used to differentiate infarct core from ischemic penumbra [4-6]. The ischemic core is defined by matched decrease in both Cerebral Blood Flow (CBF) and Cerebral Blood Volume (CBV), whereas the ischemic penumbra is defined by a mismatch between CBF and CBV (i.e., delay in Mean Transit Time (MTT) and Time to Peak (TTP), and reduced CBF but normal or even increased CBV). CBV increases in the salvageable tissue due to auto-regulatory vasodilation (Table 1). Here we report a case of asymptomatic chronic ischemic penumbra.

Measurement	Core	Penumbra
Time to peak	▲▲	▲
Mean transit time	▲▲	▲
Cerebral blood flow	▼▼	▼
Cerebral blood volume	▼	▲ or ◀▶
Flow: volume Ratio	Matched	Unmatched

Case

A 50-year-old male presented with left sided numbness and mild hand weakness. Symptom onset was a day prior, approximately 21.5 hours ago. Initial NIHSS score was 2. Non-contrast CT of the head showed a small area of hypodensity in the right posterior insular cortex and a hyperdense right MCA (Figure 1 A and B). CT Angiogram of the brain and neck revealed right proximal MCA occlusion with excellent collaterals (Figure 1 C). CT perfusion delineated a small area of decreased CBV in the posterior insular cortex and a large area of delayed TTP, suggestive of a small ischemic core and a large ischemic penumbra (Figure 1 D and E). MRI Brain confirmed the acute infarct in MCA distribution on diffusion weighted imaging (Figure 1 F).

The patient was not indicated for endovascular thrombectomy due to minor deficit and excellent collaterals. Extensive workup was unremarkable except for mild hypercholesterolemia with a total cholesterol level of 209 and LDL 127. The etiology of the stroke was likely intracranial atherosclerotic disease. Patient improved during hospitalization with only residual left sided numbness. Repeat CT perfusion on day 5 showed persistent mismatch between CBV and TTP, indicative of chronic ischemic penumbra. He was treated with maximal medical therapy with aspirin, clopidogrel, and atorvastatin daily. He was discharged with outpatient physical therapy and occupation therapy. The patient

did not meet requirements inpatient rehabilitation therapy. He has been doing well without any new symptoms in the last 3 years.

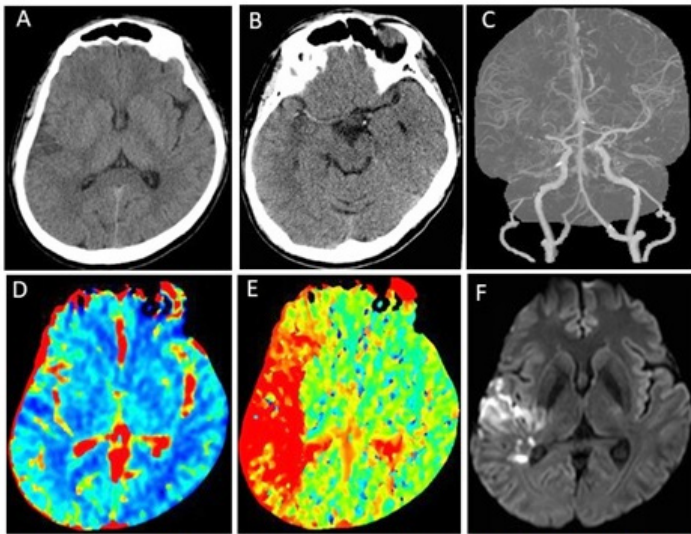


Figure 1: Non-contrast CT showed an area of hypodensity in the right insular cortex (A) and a hyperdense right MCA (B). CT angiogram revealed right M1 occlusion with excellent collaterals (C). CT perfusion demonstrated a small infarct core in the right posterior insular cortex (D) and a large area of the Time to Peak (TTP) prolongation, indicative of ischemic penumbra. A MRI brain scan confirmed acute infarction in the R MCA distribution (F).

Discussion

In recent years, 10 randomized controlled trials demonstrated powerful efficacy of Endovascular Thrombectomy (EVT) for acute ischemic stroke from large vessel occlusion with 6-24 hours of symptom onset [7]. However, the treatment is not without risk of complication. The inclusion criteria in most of the recent studies were NIHSS ≥ 6 . Our patient had minor deficit from MCA occlusion. CT perfusion showed large ischemic penumbra and excellent collateral circulation. This appears to be the first case report of a patient with documented chronic ischemic penumbra from MCA occlusion and excellent long-term outcome from medical therapy. Hypothetically, the patient may also do well

with endovascular therapy due to presence of excellent collaterals [8]. Differentiating between benign oligemia and penumbra will always be a challenge [9]. Cerebral blood flow measurement and other perfusion surrogates are estimates at a given moment and thus our ability to separate benign oligemia, penumbra and core are prone to error [10]. Further studies are warranted to investigate chronic ischemic penumbra and endovascular therapy for patients with minor deficit from MCA occlusion [11].

References

1. Astrup J, Siesjö BK, Symon L (1981) Thresholds in cerebral ischemia - the ischemic penumbra. *Stroke* 12: 723-725.
2. Olsen TS (1986) Regional cerebral blood flow after occlusion of the middle cerebral artery. *Acta Neurol Scand* 73: 321-337.
3. Hakim AM (1987) The cerebral ischemic penumbra. *Can J Neurol Sci* 14: 557-559.
4. Murphy BD, Fox AJ, Lee DH, Sahlas DJ, Black SE, et al. (2006) Identification of penumbra and infarct in acute ischemic stroke using computed tomography perfusion-derived blood flow and blood volume measurements. *Stroke* 37: 1771-1777.
5. Bivard A, Spratt N, Levi C, Parsons M (2011) Perfusion computer tomography: imaging and clinical validation in acute ischaemic stroke. *Brain* 134: 3408-3416.
6. Bivard A, Spratt N, Miteff F, Levi C, Parsons MW (2018) Tissue Is More Important than Time in Stroke Patients Being Assessed for Thrombolysis. *Front Neurol* 9: 41.
7. Yu W and Jiang W (2019) A Simple Imaging Guide for Endovascular Thrombectomy in Acute Ischemic Stroke: From Time Window to Perfusion Mismatch and Beyond. *Front Neurol*
8. Miteff F, Levi CR, Bateman GA, Spratt N, McElduff P, et al. (2009) The independent predictive utility of computed tomography angiographic collateral status in acute ischaemic stroke. *Brain* 132: 2231-2238.
9. Alawneh JA, Jones PS, Mikkelsen IK, Cho TH, Siemonsen S, et al. (2011) Infarction of 'non-core-non-penumbra' tissue after stroke: multivariate modelling of clinical impact. *Brain* 134: 1765-1776.
10. Goyal M, Menon BK, Derdeyn CP (2013) Perfusion Imaging in Acute Ischemic Stroke: Let Us Improve the Science before Changing Clinical Practice. *Radiology* 266: 16-21.
11. Fisher M (2004) The ischemic penumbra: identification, evolution and treatment concepts. *Cerebrovasc Dis* 17: 1-6.