

Case Report

Cavernous Sinus Thrombophlebitis Complicating Pansinusitis and Malignant Staphylococcal Disease of the Face

Soufiane Elhatimy, Malika benfdil, Reda Ait El abdia, Youssef Rochdi, Hassan Nouri, Abdelaziz Raji

Otorhinolaryngology Department, Arrazi Hospital, CHU MOHAMMED VI, Marrakech, Morocco

***Corresponding author:** Soufiane Elhatimy, Department of Otorhinolaryngology, Arrazi Hospital, CHU MOHAMMED VI, Marrakech, Morocco. Tel: +212668589703; Email: hatimi30@gmail.com

Citation: Elhatimy S, Elfakiri M, Rochdi Y, Nouri H, Raji A (2020) Cavernous Sinus Thrombophlebitis Complicating Pansinusitis and Malignant Staphylococcal Disease of the Face. A Case Report. Ann Case Report 14: 329. DOI: 10.29011/2574-7754/100329

Received Date: 23 January, 2020; **Accepted Date:** 07 February, 2020; **Published Date:** 12 February, 2020

Abstract

Cavernous sinus thrombophlebitis, a rare but serious disease, is infectious in most cases. The notion of a neglected or late-treated ORL sphere infectious focus is frequently found. The diagnosis, in front of a classically noisy picture, must evoke the diagnosis without delay and trigger the indication of radiological exploration which, correlated to the clinical signs, makes it possible to confirm the diagnosis and to urgently initiate a therapeutic protocol including antibiotic therapy, broad spectrum and anticoagulant treatment associated with general measures.

We report the case of post infectious cavernous sinus thrombophlebitis (maxillary sinusitis, ethmoid) in a 66-year-old male patient who presented a manipulated boil 8 days ago of his admission the patient consulted the emergency room for atypical headache, palpebral edema with exophthalmos, pain in the left orbital region in a febrile context with impaired general condition. The indication of the cerebral tomography made it possible to confirm the diagnosis of sinus-cavernous attack, and to support the cerebro-meningeal complications. Appropriate treatment has made it possible to curb this serious neurovascular damage to the base of the skull of infectious ORL sphere and dermatological origin.

Conclusion: Thrombophlebitis of the cavernous sinus is often the translation of an infectious cause, frequently of the O.R.L sphere or of the face, neglected or treated late. The clinical picture and computed tomography make it easy to confirm the diagnosis.

Keywords: Antibiotherapy; Cavernous Sinus; Heparinother; Rhinosinusic Infection; Thrombophlebitis

Introduction

Cavernous sinus thrombophlebitis, a rare but serious disease, is infectious in most cases. The notion of an infectious focus of the O.R.L or cutaneous neglected or late treated sphere is frequently found. The diagnosis, in front of a classically noisy picture, must evoke the diagnosis without delay and trigger the indication for computed tomography exploration which, correlated to the clinical signs, makes it possible to confirm the diagnosis and to urgently initiate a therapeutic protocol including antibiotic therapy. Broad spectrum and anticoagulant treatment associated with general measures [1].

Patient and Observation

We report the case of a 66-year-old diabetic patient on Anti-diabetic oral for 18 years poorly followed, who presents for 8 days of his admission a left jugular boil which was manipulated the evolution was marked 3 days later, by 1 appearance of an inflammatory cupboard of the left hemiface with ptosis and homolateral left exophthalmos evolving in a context of unencrypted fever and deterioration of health Condition, without neurological signs associated in particular no meningeal sign. On clinical examination, we note the presence of a inflammatory erythematous skin lesion of the left hemiface, extending from the cheek to the internal angle of the left eye centered by crusting lesions in the homolateral jugale (Figure 1 and 2).

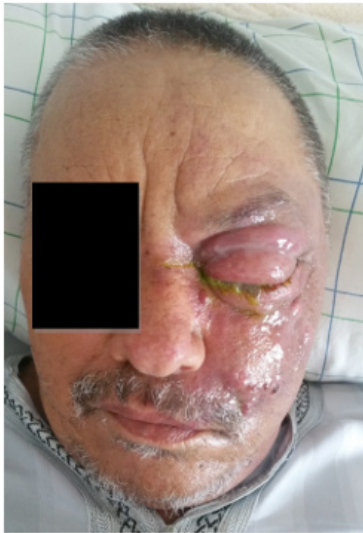

Figure 1: edema and inflammatory erythematous skin lesion of the left hemiface associated with a homolateral exophthalmos, front view (iconography of our department).

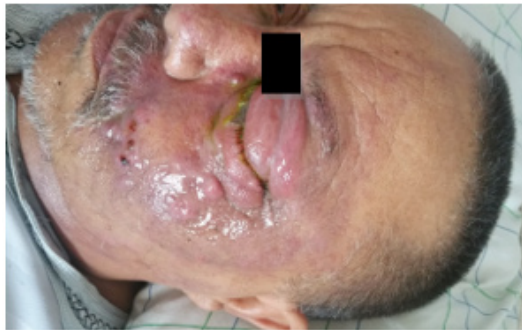

Figure 2: edema and inflammatory erythematous skin lesion of the left hemiface associated with a homolateral exophthalmos, side view (iconography of our department).

The ophthalmological examination showed a left exophthalmos with inflammatory palpebral edema and chemosis, eye redness and a decrease in visual acuity on the left side with at the back of the eye (funduscopy examination): presence of pupillary hyperemia. The biological assessment revealed a biological inflammatory syndrome with a CRP at 236.8 mg / l, PNN GB hyperleukocytosis: 16,000 elements / mm³. Encephalic and facial scanner showed a grade III left exophthalmos with dilation of the superior ophthalmic vein, a left cavernous sinus widens the site of an opacification defect, filling of the left maxillary sinus upstream of a polypoid thickening of the ostio region -infundibular with significant densification of the bone walls, edematous infiltration of the infra-temporal fossa and of the face, the whole evoking a left exophthalmos on a thrombosis of the cavernous sinus complicating a chronic maxillary sinusitis. MRI

with angio-MRI: bulging of the lateral wall of the left cavernous compartment which is opacified in a heterogeneous manner with a hyposignal aspect of the thrombosed veins. The whole is in favour of thrombophlebitis of the left cavernous sinus complicating pansinusitis (Figure 3, 4, 5).

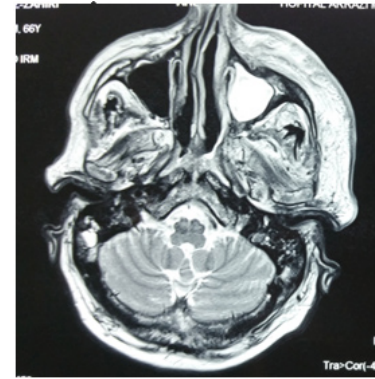


Figure 3: Facial MRI in axial sections showing the appearance of maxillary sinusitis.

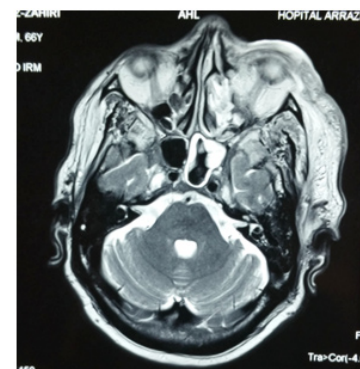


Figure 4: Facial MRI in axial sections showing the appearance of sphenoid sinusitis.

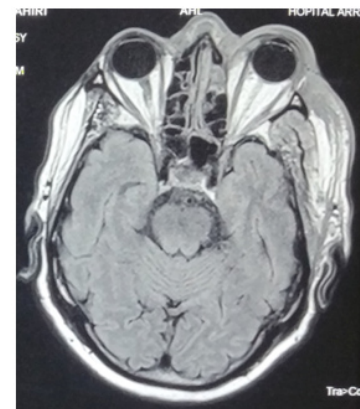


Figure 5: MRI axial slices showing the appearance of thrombophlebitis of the cavernous sinus.

The patient was initially put on triple antibiotic C3G (meningeal dose) + Metronidazole + Gentamycin combined with an anticoagulant treatment with a curative dose enoxaparin (lovenox * 0.6 x 2) then relayed by Acenocomarole (sintron * 4mg) is monitored by INR with a therapeutic objective of INR between 2 and 3. The evolution was marked by clinical improvement (regression of exophthalmos with conservation of visual acuity) and biological improvement by regression of local and general signs and normalization of CRP and INR (Figure 6 and 7).

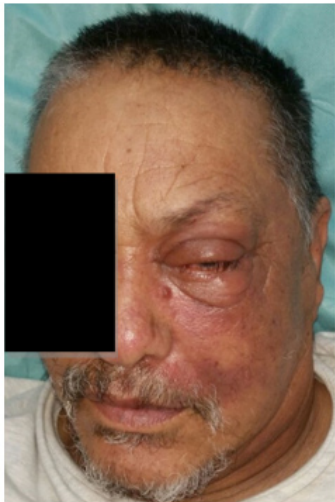

Figure 6: regression of inflammatory signs and exophthalmos after treatment.

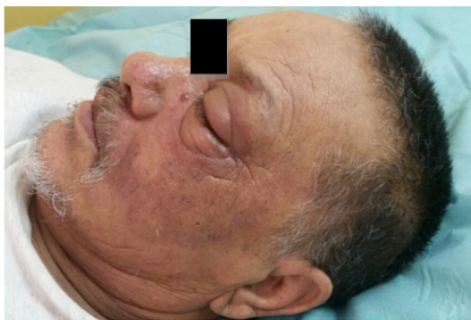

Figure 7: regression of inflammatory signs and exophthalmos after treatment. Profile view.

Discussion

Cavernous Sinus Thrombophlebitis (CST) is a particularly serious condition, the prognosis of which depends on early diagnosis and prompt treatment [1]. There are multiple etiologies, including: coagulopathies, severe dehydration, tumor invasions, cranio-facial trauma, sickle cell disease, otomastoiditis, paranasal sinus infection and other severe infections, including severe septicaemia [2]. The infectious origin is the most frequent cause,

the usual route of contamination is therefore of a regional nature, sometimes of systemic origin. The warning signs respond to a compressive inflammatory phenomenon that obstructs the cranial nerves, mainly the oculomotor nerves and the trigeminal nerves, as well as the venous system of orbital drainage. The usual clinical picture is characterized by the coexistence of ocular signs (exophthalmos, ophthalmoplegia, palpebral swelling), localized facial pain and headache.

This clinical procession of orientation, by itself, is suggestive of a cavernous syndrome. A febrile context, often marked, is usually associated with this local symptomatology, which first evokes a meningeal infectious syndrome, more so than other signs such as photophobia and vomiting, complete the initial picture or coexist at the start. The diagnosis of Malignant Staphylococcal Disease of the face (MSD) is generally clinical. The gateway is generally a boil of the face; the germs being transported by venous route. The onset is brutal, by the installation of purplish erythema without peripheral bead with an often visible venous network, an edema of the face, septicemic state, thrombosis of the cavernous sinuses and risk of subarachnoid involvement. General impairment is the rule with disturbances of consciousness going to restless and febrile coma. Despite a therapeutic arsenal in time, malignant staphylococcal disease of the face remains very poor prognosis especially in diabetics, only prevention by avoiding any manual manipulation of facial lesions could avoid its relentless course.

Thrombophlebitis of the cavernous sinus is linked to a direct extension of a thrombophlebitis from the submucosal venous networks of the sinus. This extension is favored by the absence of valves of the drainage veins in its territories [3]. Thrombophlebitis of the cavernous sinus can also occur hematogenously [4]. It most commonly affects humans between the ages of 20 and 30 [5]. The relatively late pneumatization of these sinuses explains the rarity of this pathology in children [6]. The clinical signs are mainly due to the obstruction of the upper ophthalmic vein: painful exophthalmos, chemosis and periorbital edema, this is the case for our patient. Paralysis of the oculomotor nerves or the trigeminal nerve may be associated [4]. The contralateral side appears late and signals the spread of the infection through the inter-cavernous sinuses [5]. In fact, the clinical picture of thrombophlebitis of the cerebral veins is variable, these symptoms can be isolated or associated, minor or major, rendering the diagnostic complex [2, 3, 5, 6]. In addition to these semiological particularities, the rarity of the disease only facilitates diagnostic errors [7].

The delay in diagnosis is linked to the rarity of the disease, knowing that the clinical manifestations of sphenoid sinusitis are variable and may lack specificity [2, 6, 7]. In our case, the infectious syndrome with the deterioration of the general status was simply correlated at the start with sinusitis and malignant staphylococcal disease of the face. The late diagnosis of CTS

was guided by the sudden onset of local ocular and facial signs, but without neurological signs indicative of meningoencephalic involvement. *Staphylococcus aureus* is frequently involved in sphenoid sinusitis. It is found in 48% of cultures [8]. Its involvement in septic thrombosis has been reportedly widened and should always be suspected [5]. Other germs such as streptococci and *Haemophilus influenzae* have been reported [5, 9]. Nevertheless, the bacteriological examination was negative in 33 to 50% of the cases. In our case, no germ was isolated. One of the causes of sinusitis complications is antibiotic resistance [6].

Nosocomial sinusitis is generally seen in the midst of intensive care and is linked to nasotracheal intubation [10, 11]. Computed Tomography (CT) and Magnetic Resonance Imaging (MRI) are the main morphological examinations in the diagnosis of thrombophlebitis of the cavernous sinus [12]. More accessible in emergencies, CT is requested as a first line [13, 14]. It can be performed without injecting contrast media. In this case, it shows an image of spontaneous hyperdensity linked to the presence of a thrombus. Sometimes it is normal despite the presence of an authentic TSC [14, 15]. CT with contrast agent injection is more sensitive and represents the examination of choice in emergency [12, 13]. CT in this case highlights direct signs including a lack of opacification, a heterogeneous enhancement or filling of the cavernous cavity, enlargement with bulging of its lateral edge with sometimes an image of homogeneous opacity of the sphenoid sinus and possibly indirect orbital signs (exophthalmos, densification of intraorbital fat, dilation of the ophthalmic vein, the clouding of which may be incomplete in the event of thrombosis).

The analysis in bone windows of the naso-sinus cavities and of the rocks must be systematic. It makes it possible to confirm the starting point of the infection and to specify its locoregional anatomical extension [3, 6, 13,16]. MRI is currently the gold standard because it is more sensitive than CT [15]. The difficulty is its reduced availability in emergencies. Consequently, it is generally requested as a second intention. MRI is indicated in case of doubt, failure of CT or to look for infectious and intracranial vascular complications [13]. After injection of contrast medium, an enhancement of the non-thrombosed part of the cavernous cavity and of the meningeal walls appears [9, 10]. This examination allows the detection of intracranial infectious complications (extension to the pituitary gland, pachymeningitis, epi or subdural empyema, brain abscess) and vascular (thrombosis of other dural sinuses, parenchymal arterial and / or venous ischemia) [9, 10]. Carrying out an arterial angio-MRI sequence is necessary. It makes it possible to look for abnormalities in the internal carotid artery: narrowing, occlusion, aneurysmal dilation or carotid-cavernous fistula [11, 12].

In our patient, the question arose as to the sphenoid or facial origin of the condition. But the overall analysis suggests a much

more likely facial origin, that is, *Staphylococcus aureus*. Then there is the anatomical logic of the upper palpebral venous drainage through the ophthalmic vein initially assuming a thrombophlebitis of the facial vein (significant palpebral and facial edema), causing the cavernous sinus. The combination of these two locations, judged to have a poor prognosis, as is the Glasgow Score less than 9, this would explain the particularly desperate course of the disease during the few weeks of treatment. The evolution was favourable in our patient after medical treatment [2, 8] (Figure 3 and 4). The treatment of Thrombophlebitis of the cavernous sinus is based on intravenous antibiotic therapy, first probabilistic and then adapted to the antibiogram [17]. The use of anticoagulants in the treatment of CST is a subject of controversy because of the risk of onset or worsening of a cerebral hemorrhage, of propagation of a septic embolism [1, 4, 18].

Currently, the efficacy of the use of unfractionated heparin or Low Molecular Weight Heparin (LMWH) in the acute phase followed by oral anticoagulants after stabilization of the disease on the reduction of morbidity and mortality is widely reported in adults. The principle is to prevent the spread of the thrombus, to potentiate the effect of the antibiotic after re-certification and to avoid recurrence. However, the terms of prescription vary from one author to another. In adults, the duration of treatment is 3 to 6 months depending on the case. The prescribed dose is adjusted according to the activated partial Thromboplastin Time Ratio (TCA) (or the rate of the International Normalized Ratio [INR]) which should be 1.5-2.5 and 2-3 respectively [3, 18]. The indications for anticoagulant therapy are variable. Some recommend its use for any TSC as soon as a cerebral hemorrhage has been ruled out by CT [19]. Others reserve its prescription for cases of extensive thrombophlebitis despite antibiotic therapy [18].

LMWH was prescribed in our patient at a curative dose with a relay by the sintron and a therapeutic objective between 2 and 3. The sphenoidotomy by the endoscopic route is sometimes necessary [1, 3, 20]. Overall, resuscitation measures could support antibiotic therapy in the management of certain cases of thrombophlebitis of the cavernous sinus. Surgical treatment is often offered in combination with medical treatment. It can be a sphenoidotomy in case of sphenoiditis and mastoidectomy in case of mastoiditis. Venous cerebral thrombosis previously had a poor prognosis [3]. The evolution of TSC is variable with a mortality rate of 0 to 30% [5]. Southwick et al reported a mortality rate reaching 30% in the 1980s [7]. The morbidity rate remains high and it is between 50 to 60% of cases [5]. The situation has improved considerably in recent years, with all-cause mortality at 4.3% in the acute phase, while neurological sequelae are observed in 10.6% of cases and recurrences in 2 % of cases [10, 2]. Sequelae of decreased visual acuity or blindness have been reported. Other authors mention the occurrence of ophthalmoplegia, hemiplegia, epilepsy [21-23].

Conclusion

Cavernous sinus thrombophlebitis developed here in a particular area of immunosuppression. It is a priority to make a positive diagnosis of the condition in good time, with the support of imagery. The overall analysis of this case suggests a facial origin much more likely than a sinus etiology of thrombophlebitis of the cavernous sinus in our patient.

Conflicts of Interest

Authors do not declare any conflict of interest

Author Contributions

HE the corresponding author, diagnosed the patient

SE, YR, HN and AR, treated the patient.

SE obtained the family's consent.

HE wrote the majority of the manuscript and the iconography.

ME and HN contributed to the writing of the clinical case and to the iconography.

AR and HN critically reviewed the manuscript.

References

- Gobron C, Guichard JP, Chabriat H (2004) Thrombose du sinus caverneux. *Mini revue. Sang Thrombose Vaisseaux* 16: 130-138.
- Gilain L (2003) Sinusites sphénoïdales *Encycl Med Chir (Editions Scientifiques et Médicales Elsevier SAS, Paris), Oto-Rhino-Laryngologie* 20-430-E-10: 6 p.
- F-A Hunald, A-M Riel, et al. (2011) Thrombophlébite du sinus caverneux chez l'enfant. *science directe, Archives de Pédiatrie* 18: 529-532.
- Rohana AR, Rosli MK, Nik Rizal NY, Shatriah I, Wan Hazabbah WH (2008) Bilateral ophthalmic vein thrombosis secondary to nasal furunculosis. *Orbit* 27: 215-217.
- Bayonne E, El Bakkouri W, Kania R (2007) Complications crâniennes et endocrâniennes des infections nasosinusiennes. *Encycl Med Chir (Elsevier Masson SAS Paris). Oto-Rhino-Laryngologie*, 20-445-A-10: Pg No: 9.
- Reid JR (2000) Complications of pediatric paranasal sinusitis. *Pediatr Radiol* 34: 933-942.
- Maezawa M, Seki T, Imura S, Hotta M, Yuasa Y (1991) Steroid-responsive painful ophthalmoplegia in childhood: sphenoid sinusitis presenting as Tolosa-Hunt syndrome. *Brain Dev* 13: 279-282.
- Hnatuk LA, Macdonald Re, Papsin BC (1994) Isolated sphenoid sinusitis: The Toronto hospital for sick children experience and review of the literature. *J Otolaryngol* 1: 36-41.
- Lew D, Southwick FS, Montgomery WW, Weber AL, Baker AS (1983) Sphenoid sinusitis. A review of 30 cases. *N Engl J Med* 309: 1149-1154.
- Lamas G, Tankere F, Rouby JJ, Soudant J (2000) Etude bactériologique des sinusites nosocomiales sphénoïdales. *Med Mal Infect* 30: 118-121.
- Caplan ES, Hoyt N (1982) Nosocomial sinusitis. *JAMA* 247: 639-641.
- Tang Y, Booth T, Steward M, Solbach T, Wilhelm T (2010) The imaging of conditions affecting the cavernous sinus. *Clin Radiol* 65: 937-945.
- Nagi S, Kaddour C, Jeribi R, Marrakchi-Turki Z, Ben Yahmed A (2008) Thrombose de la loge caverneuse secondaire a` une sinusite. *J Radiol* 89: 803-805.
- Naggara O, Ben Hadj Yahia B, Guarnieri G, Rodrigo S (2006) Thrombophlébite cérébrale. *Feuill Radiol* 2006; 46:155-160.
- Broussier MG (1999) Cerebral venous thrombosis: nothing, heparin, or local thrombolysis. *Stroke* 30:481-483.
- Babin E, Ndyaye M, Bequignon A, Vadillo M, Moreau S, et al. (2003) Otogenic cavernous sinus thrombophlebitis. A case report. *Ann Otolaryngol Chir Cervicofac* 120: 237-243.
- Hytoinen M, Atula T, Pitkaranta A (2000) Complications of acute sinusitis in children. *Acta Otolaryngol* 543: 154-157.
- Bhatia K, Jones NS (2002) Septic cavernous sinus thrombosis secondary to sinusitis: are anticoagulants indicated? A review of the literature. *J Laryngol Otol* 116: 667-676.
- Levine SR, Twyman RE, Gilman S (1988) The role of anticoagulation in cavernous sinus thrombosis. *Neurology* 38: 517-522.
- Goldman A (2003) Complications of sphenoid sinusitis. *Head Neck Surg* 14: 216-218.
- Amat F (2010) Complications des sinusites bactériennes du grand Enfant. A propos d'un cas et revue de la littérature. *Arch Pediatr* 17: 258-262.
- Chen HW, Su CP, Su DH, Chen HW, Chen YC (2006) Septic cavernous sinus thrombosis: an unusual and fatal disease. *J Formos Med Assoc* 105: 203-209.
- Jacques C, Bogorin A, Kindo S (2001) Quand et comment nous recherchons une thrombophlébite cérébrale. *Feuill Radiol* 41: 431-442.