

## Case Report

### Peripheral Nerve Stimulation for Treating Superior Gluteal and Sciatic Neuropathies

Pankaj Satija<sup>1</sup>, Alaa Abd-Elseyed<sup>2</sup>, Niek Vanquathem<sup>3\*</sup>

<sup>1</sup>Pain & Headache Centers of Texas, USA

<sup>2</sup>Wisconsin School of Medicine and Public Health, USA

<sup>3</sup>Vice President of Clinical Affairs, Stimwave Technologies, USA

\*Corresponding author: Niek Vanquathem, Vice President of Clinical Affairs, Stimwave Technologies, USA.

**Citation:** Satija P, Abd-Elseyed A, Vanquathem N (2020) Peripheral Nerve Stimulation for Treating Superior Gluteal and Sciatic Neuropathies. Chron Pain Manag 4: 121. DOI: 10.29011/2576-957X.100021

**Received Date:** 11 December, 2019; **Accepted Date:** 07 January, 2020; **Published Date:** 13 January, 2020

#### Abstract

**Objective:** Surgically induced peripheral neuropathy occurs in 10-50% of patients after surgery. Peripheral neuropathy pain can be very challenging to treat. We set out to evaluate the efficacy of a minimally invasive wireless neuromodulation device to treat pain as a result of superior gluteal and sciatic neuropathy.

**Methods:** Our patient was a 62-year old man with left gluteal pain following a surgical excision of tissue from the left piriformis muscle. Patient was diagnosed with superior gluteal and sciatic neuropathies. This patient failed medications and procedures and a decision was made to proceed with a peripheral nerve stimulator trial which was successful and was followed by permanent implant.

**Results:** Patient reported 75% pain relief at 12 months follow up without complications.

**Conclusion:** This system is a novel, neurostimulation device, void of extensions and implantable battery, with a minimally invasive percutaneous technique, which makes it suitable for peripheral nerve stimulation (PNS). Peripheral nerve stimulation should be considered for treating peripheral neuropathic pain resistant to conservative management.

**Keywords:** Wireless neurostimulation; Superior gluteal neuropathy; Sciatic neuropathy

#### Introduction

The superior gluteal nerve originates from the sacral plexus, L4, L5 and S1. It passes through the greater sciatic foramen above the piriformis muscles and innervates the tensor fasciae latae, the gluteus minimus and gluteus medius muscles [1].

The sciatic nerve is a large nerve originating from L4-S3; it begins in the low back, runs through the buttock region, underneath the piriformis muscle and then down the lower extremity. The nerve passes through the greater sciatic foramen as it exits the pelvis [2,3].

It is obvious from the anatomical descriptions that surgeries in the buttocks region, specifically on the piriformis muscle, can very well cause irritation or injury to both the superior gluteal and sciatic nerves. This can be associated with severe pain in areas supplied by those nerves.

Management of superior gluteal and sciatic neuropathy can be very challenging and can be resistant to all non-pharmacological, pharmacological and procedural modalities. Peripheral nerve stimulation is one of the evolving effective modalities for treating peripheral neuropathies resistant to conservative management. We present a case of a patient with severe pain due to superior gluteal and sciatic neuropathies that failed non-pharmacological, pharmacological, procedural and spinal cord stimulation modalities, but was successfully treated with peripheral nerve stimulation.

#### Case Report

Our patient was a 62-year-old man with a history of right knee replacement, followed by a left total hip replacement, which required a revision due to staph infection after surgery. The surgical debridement required removal of significant muscle mass from the left piriformis, and the patient has had extreme pain in the left buttock/hip ever since that averages a 7-8/10 on VAS. In addition, the patient had a history of low back pain which was generally well controlled with a spinal cord stimulator and medication.

The patient presented to our clinic with left gluteal pain radiating to the left lower extremity. Patient was diagnosed at our clinic with causalgia of the left lower extremity, specifically neuralgia of the superior gluteal and sciatic nerves. The patient tried oral opiates, Non-Steroidal Anti-Inflammatory Drugs (NSAIDs), neuroleptics, fentanyl patch, physical therapy and several nerve blocks without satisfactory pain control. After discussing options with the patient, a decision was made to perform a trial of a StimQ (Stimwave, Pompano Beach, FL, USA) Peripheral Nerve Stimulator (PNS). Patient was referred for a psychological evaluation, which approved the patient to proceed with the trial.

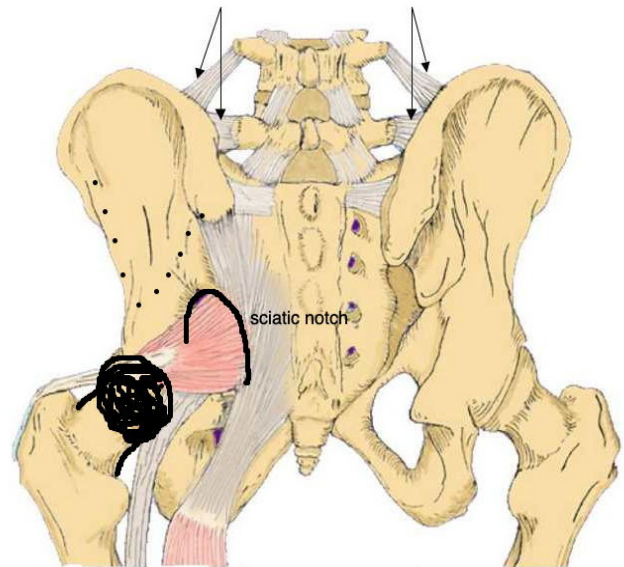
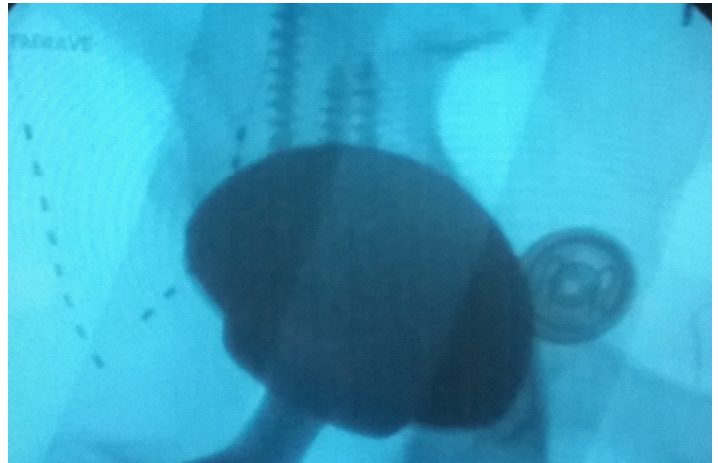
## Methods

### Surgical description for trial placement

Patient was informed of the potential risks of the procedure and consent was given. The patient was then placed prone on the table, and sterile preparation and draping was performed. Fluoroscopy was used to locate the sciatic foramen and greater trochanter. Needle entry points and stimulator pathways were planned and marked on the skin.

The first needle entry point, lateral to the left Posterior Superior Iliac Spine (PSIS), was infiltrated with local anesthetic. The 13-gauge PNS introducer needle was advanced under fluoroscopic guidance until reaching the greater sciatic foramen where the sciatic nerve passes. An 8 contact Stimwave Freedom-8 trial stimulator was introduced through the introducer and advanced to the sciatic nerve's exit point at the foramen (Figure 1). The steering stylet and the introducer were removed, and the receiver stylet was advanced into the lumen of the stimulator. Intraoperative testing was performed, confirming appropriate location.

The second needle entry point (about 4 inches lateral to the previous stimulator) was injected with local anesthetic and the PNS introducer needle was inserted and advanced under fluoroscopic guidance lateral to the sciatic foramen and medial to the greater trochanter to the branches of the superior gluteal nerve between the piriformis and gluteus medius muscles (Figure 1). An 8 contact Stimwave Freedom-8 lead was then inserted through the needle and advanced to target the branches of the superior gluteal nerve. The steering stylet and needle were removed, the receiver stylet was advanced into the lumen of the stimulator, and intraoperative testing was performed confirming the appropriate location.



**Figure 1:** Image showing the 8-contact neurostimulator with the first stimulator at the sciatic nerve's exit point at the foramen and the second array about 4 inches lateral to the previous lead and advanced lateral to the sciatic foramen and medial to the greater trochanter. The leads are not over the sciatic notch.

The lead tails were secured with Mastisol and Steri-Strips with the tails directed straight upward toward the lower back and close enough in proximity to fit beneath one antenna. A Tegaderm was placed to cover the entirety of the lead tails.

The patient reported a 75% reduction in pain with the trial and, given the excellent results, agreed to move forward with a permanent implant.

### **Surgical description for permanent implant**

After obtaining an informed consent, patient was taken to the operating room and placed in the prone position; the site was cleaned with chlorhexidine and sterile drapes were applied. Bony landmarks and the pathway of both the superior gluteal and sciatic nerves were visualized using fluoroscopy. The leads were placed on the skin to plan entry points and lead routes. A 13-gauge PNS Introducer needle was inserted lateral to the left PSIS after the needle entry point was numbed with local anesthetic. The needle was advanced under fluoroscopic guidance until the tip reached the greater sciatic foramen where the sciatic nerve passes. A 4 contact Stimwave StimQ lead with tines was introduced through the catheter and advanced to the sciatic nerve's exit point at the foramen. The steering stylet was removed, and the receiver antenna was threaded through the stimulator.

The second needle entry point was infiltrated with local anesthetic and the PNS introducer needle was inserted about 4 inches lateral to the previous stimulator and advanced under fluoroscopic guidance to a position lateral to the sciatic foramen and medial to the greater trochanter, encompassing the branches of the superior gluteal nerve between the piriformis and gluteus medius muscles. A 4 contact Stimwave StimQ lead with tines was then inserted through the needle and advanced to target the branches of the superior gluteal nerve. The steering stylet was removed, and the receiver stylet was placed. Both stimulators were placed running superior to inferior, vertically, to cross respective nerve branches. Intraoperative testing was done individually for each lead and paresthesias over the painful areas was reported by the patient.

The PNS introducer needles were removed and a single anchor stitch with 2-0 Silk was placed deep into the fascia, then around the lead body at the channel marker band. A small, approximately 1-inch, receiver pocket was created after the "cut" marker band on each stimulator. The stimulators were tunneled beneath the skin from the needle entry points to the receiver pocket. A knot was tied in each lead tail and the tip of the tail, after the knot, was secured by passing anchor stitches through deep fascia and then through the tail itself on each stimulator. Intraoperative testing of each stimulator was again performed with good coverage of the painful areas. The receiver pocket was closed in layers.

The patient's antenna is worn on the left low back region between the receiver pocket and the needle entry points, which corresponds to the area between the two sets of marker bands on the stimulator. Both stimulators use the same antenna and are controlled with 1 controller. A stimulation scheme with pulse rate of 1.5 kHz and pulse width of 30  $\mu$ s at 2-3 mA was tested and found effective.

### **Results**

At the 3 months follow up, patient reported 75% pain relief, with pain scores down from 8/10 to 2/10, and he has sustained this level of relief through the 12 months follow up. No complications were reported.

### **Discussion**

Surgically induced Neuropathic Pain (SNPP) occurs in 10-50% of patients [4]. The pain does not develop necessarily due to nerve transection, but can occur due to contusion, stretching, entrapment or inflammation of the [5]. In 2006, it was estimated that 53.3 million surgical and non-surgical procedures were performed during 34.7 million ambulatory surgery visits [6]. Considering the number of surgeries performed, the percent of SNPPs translates to millions of patients who will develop chronic post surgical pain. Some authors indicated that SNPP is an epidemic, as it affects a large number of patients and significantly impacts both the individual and society [7,8].

SNPP will most likely be diagnosed long after surgery due to the common practice of discharging patients early after the surgical intervention. After a few post-surgical follow ups, the patient will then be seen only by the primary care provider. The patient will likely have pain for quite some time before either they, or the primary care physician, realize this is not typical post-operative pain that will resolve on its own. The delayed nature of realizing that this pain is not a normal part of the healing process means that the relationship between chronic pain and surgery may be missed [9].

Pain of this nature may start as a peripheral pain, but the lack of pain control and chronicity of its course can lead to central sensitization. The pain then becomes severe and difficult to control with conservative modalities and medications [4]. Traditional treatments for neuropathic pain are not highly successful, with clinical trials showing only 30 % efficacy [10]. In fact, some treatments, such as opioids, were found to aggravate this type of pain and may potentially cause hyperalgesia [11].

### **Conclusion**

This case highlights an occurrence of severe neuropathic pain resistant to conservative management and medications. Peripheral nerve stimulation was used as a last resort and provided excellent

pain relief. Peripheral nerve stimulation should be considered for patients with post-surgical, superior gluteal and sciatic neuropathies resistant to other treatment modalities.

## References

1. Trescot AM (2016) Superior gluteal nerve entrapment. In: *Peripheral Nerve Entrapment, Clinical Diagnosis and Management*. Springer. New York, NY, USA.
2. Gallagher AE, Gulati A, Dallas-Prunskis T (2016) Proximal Sciatic Nerve Entrapment: Low Back. In: *Peripheral Nerve Entrapment, Clinical Diagnosis and Management*. Springer. New York, NY, USA.
3. Drake R, Vogl AW, Mitchell A (2019) *Gray's Anatomy for Students*. Philadelphia: Elsevier/Churchill Livingstone.
4. Kehlet H, Jensen TS, Woolf CJ (2006) Persistent postsurgical pain: risk factors and prevention. *Lancet* 367: 1618-1625.
5. Staff NP, Engelstad J, Klein CJ, Amrami KK, Spinner RJ, et al. (2010) Post-surgical inflammatory neuropathy. *Brain* 133: 2866-2880.
6. Cullen KA, Hall MJ, Golosinskiy A (2009) Ambulatory surgery in the United States, 2006. *Natl Health Stat Report* (11): 1-25.
7. Shipton EA, Tait B (2005) Flagging the pain: preventing the burden of chronic pain by identifying and treating risk factors in acute pain. *Eur J Anaesthesiol* 22: 405-412.
8. Haller G, Laroche T, Clergue F (2011) Morbidity in anaesthesia: today and tomorrow. *Best Pract Res Clin Anaesthesiol* 25: 123-132.
9. Schott GD (2001) Delayed onset and resolution of pain: some observations and implications. *Brain* 124: 1067-1076.
10. Rowbotham M, Harden N, Stacey B, Bernstein P, Magnus-Miller L (1998) Gabapentin for the treatment of postherpetic neuralgia: a randomized controlled trial. *JAMA* 280: 1837-1842.
11. Bannister K, Dickenson AH (2010) Opioid hyperalgesia. *Curr Opin Support Palliat Care* 4: 1-5.