



Case Report

Disfigured Woman with Ocular Involvement by Dog Bites

Miray Louis De Gonzague^{1*}, Ndrianarivony Simon Carnot², Rabeloson Rado³, Julienne Cyris⁴, Rafanomezantsoa Rindra⁵, Raobela Léa⁶

¹Department of Ophthalmology University Hospital of Tambohobe Fianarantsoa, Madagascar

²Department of Maxilli-Facial surgery, University Hospital of Befelatanana Antananarivo, Madagascar

³Department of Ophthalmology, University Hospital of Joseph Ravoahangy Andrianavalona Antananarivo, Madagascar

⁴Medical Doctor at Regional Direction of Health of Haute Matsiatra Region, Madagascar

⁵Department of Ophthalmology, University Hospital of Joseph Ravoahangy Andrianavalona Antananarivo, Madagascar

⁶Department of Ophthalmology, University Hospital of Joseph Ravoahangy Andrianavalona Antananarivo, Madagascar

*Corresponding author: Miray Louis De Gonzague, Department of Ophthalmology University Hospital of Tambohobe Fianarantsoa, Madagascar

Citation: De Gonzague ML, Carnot NS, Rado R, Cyris J, Rindra R, et al. (2019) Disfigured Woman with Ocular Involvement by Dog Bites. Arch Surg Clin Case Rep 2: 115. DOI: 10.29011/2689-0526.100015

Received Date: 18 November, 2019; **Accepted Date :** 26 December, 2019; **Published Date :** 31 December, 2019

Abstract

Man and dog have co-existed for thousands of years in a mutually beneficial manner, but occasionally problems arise. The commonest problem is that of a dog biting an individual. The purpose is to report a case of disfigured woman with ocular involvement by dog bites. The patient sustained multiple facial injuries associated with full thickness tissue loss majoritary in the left side of the face involving the front, eyelid with ocular muscles and scleral lacerations, nose, upper lips and a part of her left ear. Greater research is needed to identify specific risk factors for dog bite related injuries in the elderly population, with implementation of public service awareness programs targeting this vulnerable population.

Keywords : Disfigured; Dog Bites; Elderly

Introduction

Man and dog have co-existed for thousands of years in a mutually beneficial manner, but occasionally problems arise. The commonest problem is that of a dog biting an individual [1-4]. The total dog population in the Urban Municipality of Antananarivo Madagascar was estimated to be 231,085 owned dogs and 29,449 unowned dogs. The mean owned dog to person ratio was 1 dog per 4.5 persons [5]. In nearly all parts of the world, dogs pose serious human health, socio-economic, political and animal welfare problems. They may threaten, injure or kill children or adults [6]. Dog bite injury is an important global public health problem, although underreported in the developing countries. In the USA, a survey conducted in 2001-2003 indicates that victims of dog bite are about 4.5 million each year, and 19% of them sustained injury necessitating medical attention [7,8]. Severe bites tended to occur in the homes where

the dogs lived, and to be directed towards children and older adults [9]. Children are the main victims of canine attacks, both in morbidity and lethality [9] whereas cat bites are more common in adult women [10]. The purpose is to report a case of disfigured old woman by dog bite.

Observation

A 94-year-old woman with a history of hypertension stage III, which was adequately managed with antihypertensive drugs, was found seriously injured following an attack by her own dog. She was reportedly able to perform most activities of daily living, and was able to ambulate around the home independently. She was brought to the hospital by her neighbour. Medical examination observed that Glasgow scoring was 10/15. The patient sustained multiple and deep facial injuries associated with full thickness tissue loss majoritary in the left side of the face involving the front, eyelid with ocular muscles and scleral lacerations, nose, upper lips and a part of her left ear. Amazingly, the cornea was fine (Figure

1A,1B).

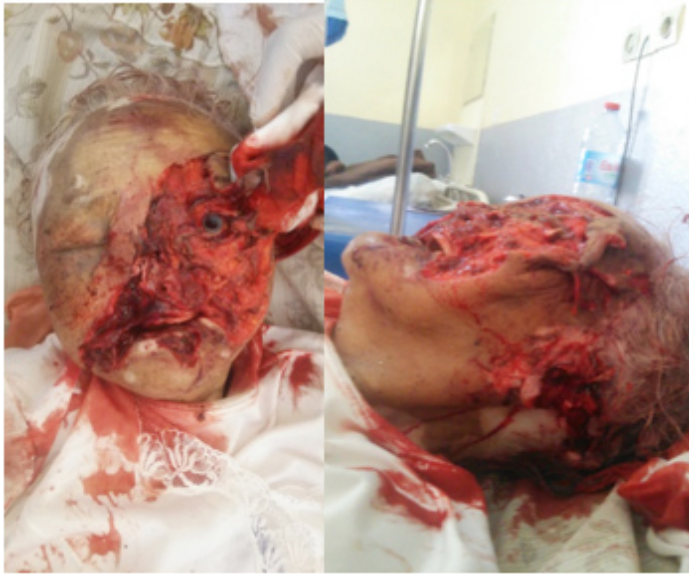

Figure 1A

Figure 1B

Figure 1A, 1B: Preoperative photos of an old woman disfigured by dog bite.

The visual acuity was light perception negative at the left eye. Tetanus toxoid and antibiotics were administered, and the patient was admitted to the intensive care unit for wound care and resuscitation. The patient underwent a debridement of the wound, suture, multiple skin and tissue graft coverage and grafting. An evisceration of the left eye by the medical team of Maxillo-Facial surgery service and Ophthalmology service under a general anesthesia (Figure 2A, 2B).

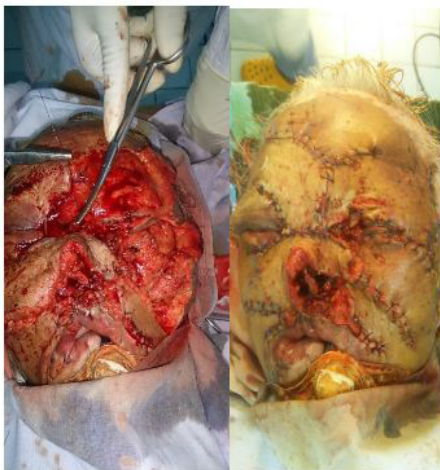


Figure 2A

Figure 2B

Figure 2A, 2B: Perioperative and postoperative photos of an old woman disfigured by dog bites.

At first and second days after the operation, there was an haemodynamic stability and a good outcome of the surgery. But at third day of postoperative periode , there was an occurrence of cardiac and respiratory failures leading to the death of the patient.

Discussion

It was hypothesized that children would be more likely the victim of high severity incidents than older persons. In the older adult population, an association between fractures and walking dogs on leashes has recently been reported [11,12] whereas an increased odds of admission to hospital following a dog bite injury in adults over 75 years has been reported in the US [13]. Similarly, an increased risk of significant injury, defined as patients death, hospitalization, surgery, or diagnosis of fracture or amputation following a dog bite injury was reported in adults over the age of 60 in Korea [14]. Jones reported a case of 56-year-old man attacked by his own dog. Puncture wound over the right temple, and a complex perforation of the right globe, comprising a circumferential medial scleral rupture, and a corneal laceration crossing the visual axis were observed. The crystalline lens was disrupted but present. The eye is blind. This case is similar to ours with involvement of the eyeball. But the differences are that our patient ws bitten on her nose, cheek and ear [15].

Regarding the age of the patient, most of the patients (52.3%) were in the age group of 1-6 years. Concerning the site of the bite, it is reported that face was the commonest affected organ by the dog bite and was the affected site in children aged between. Limbs were most commonly affected in older age group. Our case is exceptional because the patient was bitten on the face and the remaining of her bodie was intact. As far as treatment is concerned, we performed debridement, skin and tissue grafting. Ovais et al performed also the same process of care to their patients [16]. Animal-related factors such as age, spay/neuter status and breed of the dog have long been implicated as risk factors for dog bites. It was found that the most severe bites occurred in the Home [9]. According to Patronek et al, in 256 dog bite related fatalities in the USA between 2000-2009, the following potentially preventable factors were considered to have played a role: Owner mismanagement of dogs , owners with a history of abuse or neglect of dogs, and dogs kept isolated from regular positive human interactions [17]. The study by Langley found that children in the age group of 1e4 years have the highest number of deaths, and infants less than 1 year of age have the highest death rate, with victims less than 10 years of age accounting for 55.6% of total deaths, while persons 65 years or older accounting for 24.0% of deaths. However, elderly victims have been found to have a higher in-hospital fatality rate compared with younger persons. This is most likely related to the presence of comorbid conditions, preinjury medications, reduced physiologic reserve, and the physical changes of aging compounding the traumatic injury sustained by the attack [18]. We can see that dog

attacks are a serious problem that requires a serious and effective long-term solution. These aforementioned report results indicate that greater public awareness regarding dog-bite injuries is needed especially in Madagascar. Parkinson and Sylvie, through their study concluded that more attention should be paid to the risks that dogs pose to older adults. Failure to protect people from dog-bite injuries has implications for the dogs' own welfare, as well as for human health [9].

Conclusion

In nearly all parts of the world, dogs pose serious human health, socio-economic, political and animal welfare problems. Dog bites remain a growing public health problem, with possible long-lasting physical and psychological impairment, economic loss, and death. The elderly and the very young populations are disproportionately adversely affected by severe dog bite injuries. Perhaps greater research is needed to identify specific risk factors for dog bite-related injuries in the elderly population, with implementation of public service awareness programs targeting this vulnerable population.

References

1. Ogun SA (2001) Human Rabies- A review of current literature. Nigerian Medical Practitioner 40: 3-5.
2. Zanini F, Padinger P, Ellissondo M C, Perez H (2008) Epidemiology of dog bite lesions in Tierra del Fuego, Argentina. Medicina (B. Aires) 68: 1-5.
3. Wright JC (1985) Severe attack by dogs: characteristics of the dogs, the victims, and the settings. Public Health Rep 100: 55-61.
4. Dwyer JP, Douglas TS, Van AB (2007) Dogbite injuries in children – a review from South African Paediatric trauma unit. S. Afr Med. J 97: 597-600.
5. Maherisoa R, Jhon H R, Soloherilala R, Hary R, Marie-Perle A, et al. (2009) Dog ecology and demography in Antananarivo, 2007 BMC Veterinary Research 5: 21.
6. Bogel K, Meslin FX (1990) Economics of human and canine rabies elimination: guidelines for programme orientation. Bull World Health Organ, 68: 281-91.
7. Gilchrist J, Sacks JJ, White D, Kresnow MJ (2008) Dog bites: Still a problem? Inj Prev 14: 296-301.
8. (2004) World Health Organization: WHO Expert Consultation on Rabies: First report WHO Technical Report Series 931. World Health Organization, Geneva, Switzerland.
9. Parkinson, Sylvia L (2019) Checkley insights about the epidemiology of dog bites in a Canadian city using a dog aggression scale and administrative data. Animals 9 : E324.
10. Sacks JJ, Lockwood R, Hornreich J, Sattin RW (1996) Fatal dog attacks, 1989-1994. Pediatrics 9: 891-895.
11. Feldman KA, Trent R, Jay MT (2004) Epidemiology of hospitalizations resulting from dog bites in California, 1991-1998. Am J Public Health 94: 1940-1941.
12. Pirruccio K, Yoon YM, Ahn J (2019) Fractures in elderly americans associated with walking leashed dogs. JAMA Surg 154 : 458-459.
13. Loder RT (2019) The demographics of dog bites in the United States. Heliyon 5: e01360.
14. Park J W, Kim DK, Jung JY, Lee SU, Chang I, et al. (2019) Dog-bite injuries in Korea and risk factors for significant dog-bite injuries: A 6-year cross-sectional study. PLoS ONE 14: e0210541.
15. Jones N P (1990) Perforating eye injuries caused by dog bites. Journal of the Royal Society of Medicine 83: 332-333.
16. Ovais H, Adil H, Darzi MA, et al. (2017) Analysis of dog bite injuries in Kashmir. Pulsus Journal of Surgical Research 1: 2-9.
17. Patronek GJ, Sacks JJ, Delise KM, Cleary DV, Marder AR (2013) Co-occurrence of potentially preventable factors in 256 dog bite-related fatalities in the United States (2000–2009). J. Am. Vet. Med. Assoc 243 :1726-1736.
18. Langley RL (2009) Human fatalities resulting from dog attacks in the United States. Wilderness Environ Med 20: 19-25.