

Ulnar Artery Pseudoaneurysm That Developed During Rehabilitation for Paraplegia in A Patient with Hemophilia B: A Case Report

Shigenori Ito^{1*}, Tomoharu Koike², Yoshio Matsushige³, Junji Hiraga⁴, Hironobu Inagaki⁵, and Shinji Kato⁶

^{1*}Department of Cardiology, Sankuro Hospital, Toyoya, Japan

²Department of Rehabilitation Medicine, Sankuro Hospital, Toyota, Japan

³Department of Rehabilitation, Sankuro Hospital, Toyota, Japan

⁴Department of Hematology, Toyota Kosei Hospital, Toyota, Japan

⁵Department of Orthopedic Surgery, Toyota Kosei Hospital, Toyota, Japan

⁶Department of Internal Medicine, Sankuro Hospital, Toyota, Japan

***Corresponding author:** Shigenori Ito, Department of Cardiology, Sankuro Hospital, 7-80, Kosaka-cho, Toyota-shi, Aichi-ken, 471-0035, Japan. Tel: +81-565320282; Fax: +81-565352570; Email: shigeito918@gmail.com

Citation: Ito S, Koike T, Matsushige Y, Hiraga J, Inagaki H, et al. (2019) Ulnar Artery Pseudoaneurysm That Developed During Rehabilitation for Paraplegia in A Patient with Hemophilia B: A Case Report. Ann Case Report 12: 273. DOI: 10.29011/2574-7754/100273

Received Date: 08 November, 2019; **Accepted Date:** 20 November, 2019; **Published Date:** 25 November, 2019

Abstract

Here we reported a case of ulnar artery pseudoaneurysm that developed during rehabilitation for paraplegia in the acute phase in a 70-year-old patient with spinal cord infarction due to an acute thoracic aortic dissection. Hemophilia B, which was first diagnosed during this hospitalization, was a potential cause of this disease. The aneurysm was excised and the ulnar artery was reconstructed using direct end-to-end anastomosis via microsurgery under the use of recombinant coagulation factor IX nonacog alfa. Physiotherapy should be performed to recognize the potential development of this disease in cases of bleeding tendency like hemophilia.

Keywords: Hemophilia B; Hypothenar hammer syndrome; Palmar artery; Paraplegia; Physiotherapy; Pseudoaneurysm; Ulnar artery

Introduction

Pseudoaneurysm (PSA) of the palmar artery is a relatively rare disease [1-5]. PSA of the ulnar artery is a sequela of Hypothenar Hammer Syndrome (HHS) that occurs when repeated impacts to the palmar aspect of the wrist and hand at the hypothenar eminence causes damage to the underlying ulnar artery. Reports on this disease are very limited in patients with paraplegia and/or hemophilia [6,7]. We present an interesting case of the ulnar artery PSA, which developed during rehabilitation for paraplegia. The pathogenesis including hemophilia [6] and treatment will be discussed in this case report.

Case Report

A 70-year-old man suffered from acute thoracic aortic dissection type A associated with spinal infarction and underwent successful emergent artificial vessel replacement but paraplegia in the Th12 level, showing a manual-muscle-testing grade of 1-2, persisted in February 2017 thereafter. He was transferred to our hospital for rehabilitation in April 2017. He had dilated cardiomyopathy and paroxysmal atrial fibrillation. The rehabilitation program included push-ups, transfers, and wheelchair propulsions. His bleeding tendency, which was manifested as nasal bleeding, bloody stool, and macrohematuria, was found immediately after hospital admission. Although these symptoms improved after the cessation of edoxaban tosylate hydrate 30 mg/day and a switch to warfarin control at strict Prothrombin Time-International Ratio (PT-INR) of 1.5; however, intra muscular hemorrhage in the left psoas and the

right middle gluteal muscle occurred on two separate occasions separated by a 40-day gap, and was associated with severe anemia. The warfarin was stopped thereafter. A detailed examination revealed abnormal coagulation function in July 2017. Platelet count and Prothrombin Time (PT) were within normal limits. Activated Partial Prothrombin Time (APTT) was prolonged at 49.0 seconds. The activity level of coagulation factor IX was reduced to 4 % (normal range, 70–130%). Factor IX auto-antibody inhibitors were not detected. The Von Willebrand factor antigen activity level was 103% (normal range, 50–155), and that of coagulation factor VIII was 83% (normal range, 60–150%), respectively. On the basis of these results, the patient was diagnosed as having congenital hemophilia B (Moderate type) and received recombinant coagulation factor IX nonacog alfa 3000 IU. In August 2017, a hypothenar pulsatile mass was found in his right hand (Figure 1).

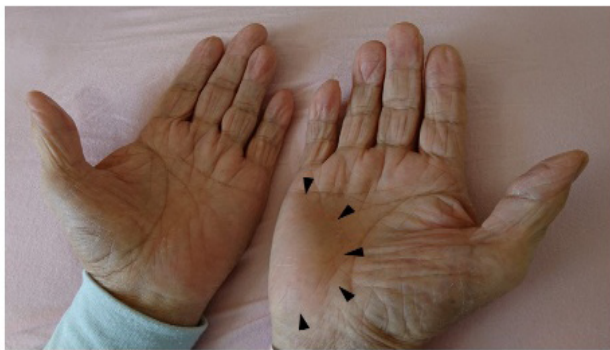


Figure 1: Photograph of palmar mass at the time of first detection. Black arrow heads indicate a mass in the right hypothenar eminence.

Ultrasonography (Figure 2) showed a pulsatile aneurysm with a maximum diameter of 16.0 mm and a two-layered mural material, which could be a thrombus. The outer material was high-echoic, while the inner material was low-echoic. Doppler imaging confirmed the presence of blood flow within the PSA but did not detect blood inflow to the PSA. Digital Subtraction Angiography (DSA) demonstrated a saccular delayed outpouching in the palmar segment of the ulnar artery (Just proximal to the bifurcation of superficial and profound palmar arches) (Figure 3). Before the development of the aneurysm, there were no obvious episodes of trauma or bruising. The exact onset date was unknown because of a lack of symptoms such as pain. The aneurysm was excised and the ulnar artery was reconstructed with direct end-to-end anastomosis during microsurgery 2 weeks after its detection. The patient was introduced to specialists at another hospital over the course of 2 weeks during which time DSA and subsequent surgery were planned. There was no severe atherosclerosis or specific abnormalities of ulnar artery around the PSA. Bleeding was controlled during the peri-operative period with the administration

of additional recombinant coagulation factor IX nonacog alfa for hemophilia B. The pathological findings revealed a PSA. Although transient bleeding from the wound developed 2 days after the stitches were removed, the anastomosed site showed no trouble and hemostasis was achieved.

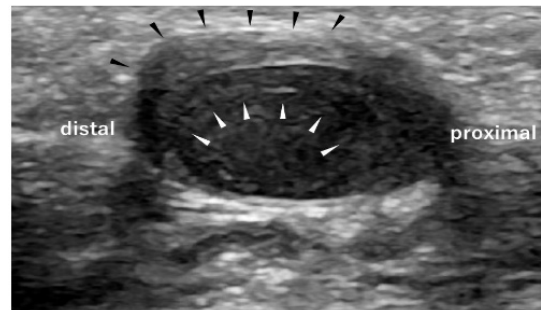


Figure 2: Ultrasonography. Ultrasonography showing a pulsatile aneurysm with a maximum diameter of 16.0 mm and a two-layered mural material that could be thrombus. The outer material (black arrow heads) was high-echoic, while the inner material (white arrow heads) was low-echoic.

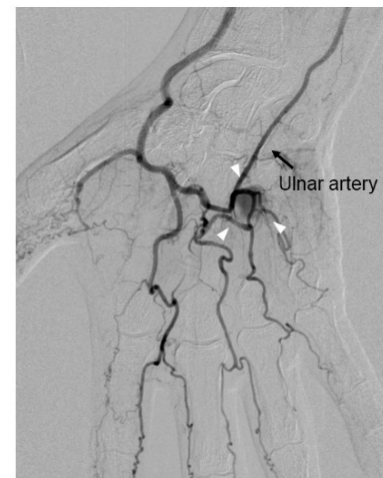


Figure 3: Digital subtraction angiography. Digital subtraction angiography demonstrating a saccular delayed outpouching (white arrow heads) in the palmar segment of the ulnar artery just proximal to the bifurcation of the superficial and profound palmar arches

Discussion

To the best of our knowledge, this is the first case report of ulnar artery PSA occurred in a patient with hemophilia B and paraplegia. A PubMed search revealed only two case reports of this disease; in one patient with hemophilia B [6] and another patient during physiotherapy [7]. A PSA of the palmar artery could be included in HHS [8-10]. HHS includes a constellation

of symptoms resulting from repetitive trauma to the hypothenar eminence, often due to the use of the hand as a hammer. Sequelae of this syndrome include both true and false aneurysms as well as thrombosis of the ulnar artery due to its vulnerability to blunt trauma. The ulnar artery is particularly vulnerable to traumatic damage where it exits Guyon's canal and passes over the hook of the hamate. This anatomical location has the potential to be trapped between a hammer (external trauma) and the hamate bone with only a thin layer of tissue superficially to protect the ulnar artery [9]. The mechanism of PSA formation involves a break in the endothelium (generally secondary to blunt or penetrating trauma) with subsequent extravascular hematoma formation, clot reorganization and recanalization of the vasculature through a newly formed false lumen [6,11].

The push-up motion is a fundamental and important activity in physiotherapy and daily living of subjects with paraplegia, in which both upper extremities, especially the hands, would play a very large role and receive a tremendously large load on the palm [12]. The load on the hypothenar could vary among patients. However, palm PSA in handicapped disabilities with paraplegia is rare despite the potential stress on the palms during daily life. In our case, anticoagulation therapy for dilated cardiomyopathy and paroxysmal atrial fibrillation might have augmented the coagulation insufficiency due to the hemophilia B. However, it was stopped at the time of pseudoaneurysm development. Because of the clotting deficiencies in hemophilia, blood extravasation following trauma is increased, allowing for the formation of a larger hematoma than would be expected in an individual with normal clotting abilities [6]. We suspect that repeated stress to the right ulnar artery, during physiotherapy and daily physical activity composed of the push-up motion for transfer and wheelchair propulsion might have developed an aneurysm in the ulnar artery based on the coagulation insufficiency. However, the possibility of an asymptomatic blunt injury could not be completely ruled out as the cause of the PSA. The two-layered echogenic thrombus-like material may have resulted from the long-lasting PSA.

As the risk of rupture [13,14], nerve compression [15,16], and distal thrombus in the future exists in this disease, we chose surgical intervention. Under treatment with recombinant coagulation factor IX nonacog alfa, no major bleeding complications occurred in the peri-operative period. Treatment of the ulnar PSA with coiling for the ulnar PSA has been reported [4]. Iatrogenic PSA was previously treated with ultrasound-guided thrombin injections [17]. These less-invasive methods may have been appropriate alternative treatments for this case. However, we selected open surgery because the patient was at risk for bleeding due to hemophilia. We were also concerned about recurrence, even after successful obliteration by coiling or ultrasound-guided thrombin injections.

Though our patient was of advanced age, factor IX auto-antibody inhibitors were not detected. Thus, acquired hemophilia B was ruled out. Acquired hemophilia B is extremely rare. It has been rarely reported in Western countries [18] and never reported in Japan according to the practice guidelines of acquired hemophilia A by The Japanese Society on Thrombosis and Hemostasis.

The cause of the acute aortic dissection in this case was considered to be atherosclerosis. The patient had no family history that suggested vulnerability of the aorta or signs of connective tissue disease. He showed no bleeding tendency in the past, but had a family history of hemophilia. We suspect that the subclinical bleeding tendency increased due to the use of anticoagulants during and after the operation for aortic dissection. Compared to DSA, in this case CT angiography and magnetic resonance imaging could be more favorable and non-invasive methods for reducing complications.

Conclusions

Here we reported a case of ulnar artery PSA that developed during rehabilitation for paraplegia. Hemophilia B, which was first diagnosed during this hospitalization, was a potential cause of this disease. Physiotherapy should be performed recognizing the potential occurrence of this disease in cases of bleeding tendency like hemophilia.

Declaration of Conflicting Interests

The authors declared no potential conflicts of interest with respect to the research, authorship and/or publication of this article.

Ethical Approval

Our institution does not require ethical approval for reporting individual cases or case series.

Funding

The authors received no financial support for the research, authorship and/or publication of this article.

Informed consent

The patient described herein had given consent to the use of deidentified patient data for use in research and education.

References

1. Hurst SA, Raveendran S, Eckersley JR (2014) Ulnar artery pseudoaneurysm following single non-penetrating trauma to the hypothenar region. *J Hand Surg Eur* 39: 786-788.
2. Nour M, Talha H, El Idrissi R, Lahraoui Y, Ouazzani L, et al. (2014) false traumatic aneurysm of the ulnar artery in a teenager. *J Mal Vasc* 39: 426-429.

3. Torres-Blanco A, Gomez-Palones F, Ortiz-Monzon E (2015) Rapidly expanding ulnar false aneurysm related to a tablet computer. *Ann Vasc Surg* 29: 1015 e5-1015e8.
4. Woodley-Cook J, Konieczny M, Simons M (2015) The ulnar artery pseudoaneurysm. *BMJ Case Rep pii: bcr-2015-212791*.
5. Cheng CL, Chiang LC, Ho CH, Liu PY, Lai CS, et al. (2017) "Ulnar artery pseudoaneurysm and compartment syndrome formation after snake bite to the left forearm" by lan pin et al., *Clin Toxicol (Phila)* 2017 nov. 10. *Clin Toxicol (Phila)* 20:1-2.
6. Plant MA, Scilley CG (2007) Ulnar artery pseudoaneurysm in a patient with factor IX deficiency (hemophilia B). *Can J Plast Surg* 15: 223-225.
7. Sadat U, Gaunt M (2007) Physiotherapy as a cause of hypothenar hammer syndrome. *J Hand Surg Eur* 32: 715-716.
8. Brinkman JN, van Akkooi AC, Jaquet JB, Leeuwenburgh BP, Fioole B, et al. (2013) Hypothenar hammer syndrome; rare arterial disorder of the hand due to blunt trauma. *Ned Tijdschr Geneeskd* 157: A6077.
9. De Monaco D, Fritsche E, Rigoni G, Schlunke S, Von Wartburg U (1999) Hypothenar hammer syndrome. Retrospective study of nine cases. *J Hand Surg Br* 24: 731-734.
10. Houshian S, Mahdi BH (1999) Hypothenar hammer syndrome. *Ugeskr Laeger* 161: 4643-4644.
11. Wang AA, Strauch RJ, Moore JA (1998) Pseudoaneurysm of the ulnar artery occurring after fracture of the distal radius and ulna: A case report. *J Hand Surg Am* 23: 933-937.
12. Kunju N, Ojha R, Devasahayam SR (2013) A palmar pressure sensor for measurement of upper limb weight bearing by the hands during transfers by paraplegics. *J Med Eng Technol* 37: 424-428.
13. Erdoes LS, Brown WC (1995) Ruptured ulnar artery pseudoaneurysm. *Ann Vasc Surg* 9: 394-396.
14. Dey S, Baruah A, Mohanta PK (2009) Ruptured pseudoaneurysm of the radial artery. *BMJ Case Rep pii: bcr06.2008.0080*.
15. Kalisman M, Laborde K, Wolff TW (1982) Ulnar nerve compression secondary to ulnar artery false aneurysm at the guyon's canal. *J Hand Surg Am* 7: 137-139.
16. Smith RJ (1982) Ulnar nerve compression secondary to ulnar artery false aneurysm at the Guyon's canal. *J Hand Surg Am* 7: 631-632.
17. Lewandowski P, Baran J, Maciejewski P, Budai A (2019) A novel technique for iatrogenic pseudoaneurysm obliteration with ultrasound-guided thrombin foam injection. *Vasa* 48: 181-184.
18. Cohen AJ, Kessler CM (1996) Acquired inhibitors. *Baillieres Clin Haematol* 1996; 9: 331-354.