

Bakir's Suspension Technique for Cheek Augmentation and Rejuvenation

Yousef Bakir MD*, Ahmed Mokhtar Mahmoud Elbayer MD, MS

Plastic Surgeons, Qatar.

*Corresponding author: Yousef Bakir, Senior Consultant Plastic Surgery, Qatar. Tel: +97455044251; Email: dr.bakir@live.com

Citation: Bakir Y, Elbayer A (2019) Bakir's Suspension Technique for Cheek Augmentation and Rejuvenation. Plast Surg Mod Tech 4: 151. DOI: 10.29011/2577-1701.100051

Received Date: 16 September, 2019; **Accepted Date:** 25 September, 2019; **Published Date:** 30 September, 2019

Abstract

This paper is introducing a new technique for cheek rejuvenation. It's safe, simple, quick, and minimally invasive. It can be done as an office procedure or in combination with a facelift. The technique involves suspension stitching on the cheek.

Keywords: Augmentation; Cheeks; Face; Innovation; Idea; Lift; New; Rejuvenation; Stitches; Suspension; Sutures

Introduction

Cheek rejuvenation has been changed by introducing many techniques and methods through modern history; including fillers therapy; fat grafting and thread lifting (Aptos). Some of these methods have higher complications rate and needs general anesthesia compared to the others. It's well known in plastic surgery that there is no "one technique fits all." Each case has its criteria that favor one technique or procedure on another. In this technique, I am discussing a new idea that helps in facial rejuvenation using two small incisions, and a suture with a Liver/ blunt opened needle and local anesthesia which makes it very easy and applicable. In literature, a lot of authors are describing the threading technique, which involves the temporal fascia, which has higher morbidity due to the possibility of injuring the temporal branch of the facial nerve.

Method

I developed the zygomatic arch thread suspension technique for cheek augmentation and rejuvenation. I am using it in many cases for the past 18 years. It showed great results and patient satisfaction due to its ease. I use it also to suspend sagging jowls.

Instruments

- Liver/ blunt open needle
- No 11 blade
- 4/0 Nylon thread with round needle
- 4/0 Vicryl thread round needle
- Needle holder
- 2 Addison toothed forceps
- Stristrips

Technique

1. 2x 1-2mm Incisions over the zygomatic arch, a half-centimeter apart to form a thin skin bridge. Figure 1
2. Incision on the nasolabial fold. (Figures 1,2).

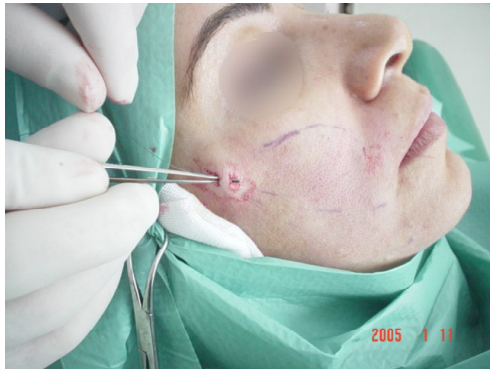

Figure 1: Creating a skin bridge by the two zygomatic incisions.

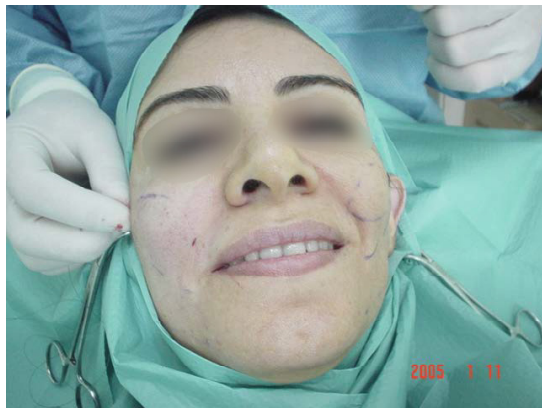


Figure 2: Right side; post-op. Left side; pre-op while smiling.

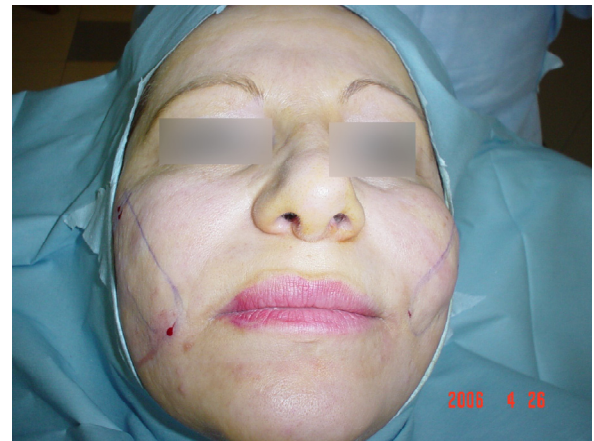

Figure 3: Right side; before. Left side; after.

Case selection criteria (Figure 4):

Young patients (25 - 45 years old) with good skin elasticity with full and dropped malar fat pads (Figure 3). Bell's Palsy patient shows good results (more studies for long term results are needed) Patients with sagging jowls.

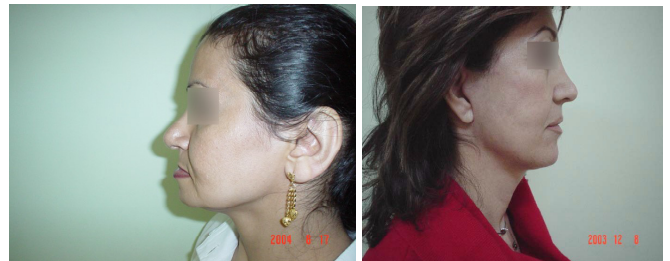

Figure 4: two different indicated cases for this technique.

3. Insertion of straight needle with monofilaments suture from the lower zygomatic incision and pass the needle through the cheek fat pad to exit from the nasolabial incision.
4. Reinsertion of the needle back from the last incision through a different track in the fat pads to make a loop holding the fat pad, then to exit through the upper zygomatic incision.
5. I am tugging the suture down to the zygomatic arch periosteum by the suture needle after the application of the needed tension that gives the requested results.
6. Skin closure by Stristrrips.

Usually, I use more than one thread in this method, e.g., 2 Nylon threads with 1 Vicryl, which I suggest it gives the best results. The usage of oral antibiotics for five days showed no infection rate with this technique. Procedure duration: 30 mins Anesthesia type: local anesthesia (Figure 3).

Discussion

I have used this technique in more than 150 cases which showed excellent results (Figure 5).

Complications encountered:

- Mild edema
- Temporarily Skin irregularity in some patients with skin laxity usually resolves after ten days. Asymmetry happened in few patients and fully corrected by re-fixing the thread or adding another on the loose side.
- zero hematomas, ecchymosis, and infection.

Comparison to current cheek augmentation methods to Bakir's Technique:

The current methods in plastic surgery to augment the cheeks are:

1. Fillers: will not tackle the dropped malar fat pad. They are not the best in chubby cheeks with dropped fat pads (it will make over the fullness of the cheeks)
2. Mini Facelift: more invasive
3. Threads [1-3], e.g., Aptos: not giving good fixation because there is no strong suspension.
4. other suspension methods that are using temporalis fascia are not as safe because they are in close relation to the temporal branch of the facial nerve (Figures 5A,5B).

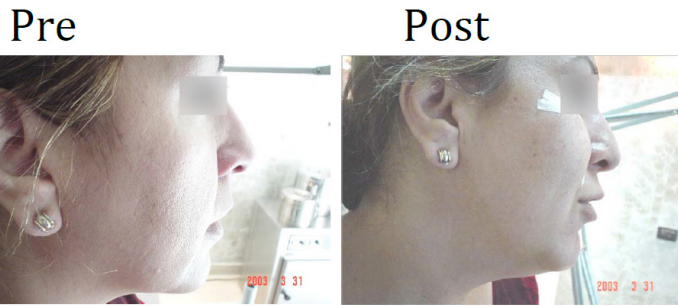

Figure 5A: Some pre and post-op cases.

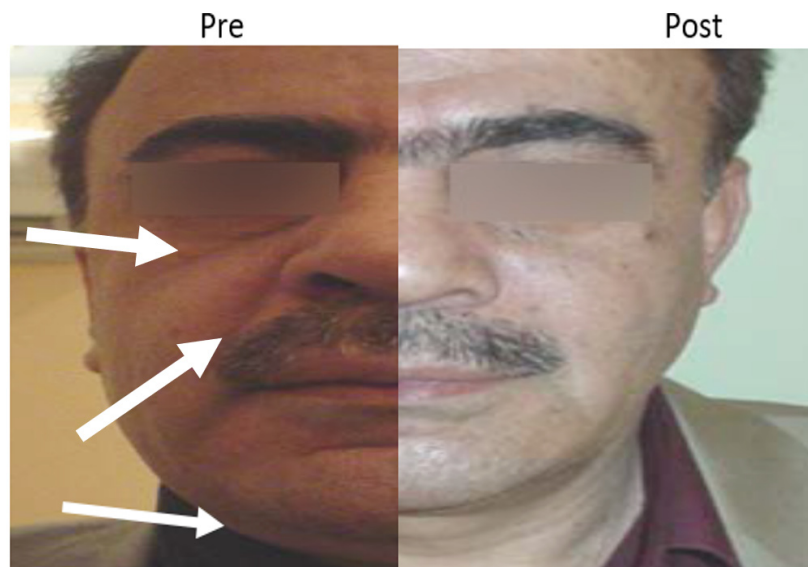


Figure 5B: Some pre and post-op cases (improvement in the nasolabial fold with disappearing of tear trough with an accumulation of the fat at the tip of the cheeks plus decrease of jowls and neck laxity).

Conclusion

This technique is effective, easy, simple, with good results and good patients' satisfaction.

I recommend using this technique in such indicated cases.

Acknowledgment

Thanks to Dr. Ahmed Elbayer for his contribution to this paper.

Conflict of interest

No Conflict of interest

References

1. Helling ER, Okpaku A, Wang PTH, Levine RA (2007) Complications of facial suspension sutures. *Aesthetic Surgery Journal* 27: 155-161.
2. Robinson JK (2003) Suspension Sutures in Facial Reconstruction. *Dermatologic Surgery* 29: 386-393.
3. Isse NG, Fodor PB (2005) Elevating the midface with barbed polypropylene sutures. *Aesthetic Surgery Journal* 25: 301-303.