

ABC Surgical Risk Scale for Skull Base Meningioma

Rajan Kumar Sharma*, Jha RK, Bista P

Department of Neurosurgery, National Academy of Medical Sciences, Bir Hospital, Kathmandu, Nepal

***Corresponding author:** Rajan Kumar Sharma, Department of Neurosurgery, National Academy of Medical Sciences, Bir Hospital, Kathmandu, Nepal. Tel: +977-9849193725; Email: rajanktm58@gmail.com

Citation: Sharma RK, Jha RK, Bista P (2019) ABC Surgical Risk Scale for Skull Base Meningioma. J Surg 13: 1238. DOI: 10.29011/2575-9760.001238

Received Date: 09 July, 2019; **Accepted Date:** 22 July, 2019; **Published Date:** 26 July, 2019

Abstract

Purpose: Surgery for Skull Base Meningioma (SBMs) can lead to various complications because these lesions are difficult to approach and can involve cranial nerves and arteries. We used a scoring system to evaluate the relative risks and benefits of surgical treatment of Skull Base Meningioma.

Methods: All patients presenting to Neurosurgical OPD or Emergency department of National Academy of Medical Sciences, Bir Hospital were initially examined by the Neurosurgical Resident in training under the supervision of Consultant Neurosurgeon. All patients were examined and sent laboratory investigation with radiological investigation required for the diagnosis. We validated the predictive accuracy of this scoring system in 25 consecutive cases treated surgically between January 2017 and December 2018, including both primary and repeated surgeries.

Results: We identified five items that predicted surgical risk like: 1) tumor attachment size; 2) arterial involvement; 3) brainstem contact; 4) central cavity location; and 5) cranial nerve group involvement. We used this scoring system the ABC Surgical Risk Scale, after the initial letters of these items. Each factor was assigned a score of 0-2 points giving a possible total score of 10 points. On average, the scoring system allocated 2 points for gross-total resections, 6 points for near-total resections, and 9 points for sub-total resections, with significant differences between groups.

Conclusion: We concluded that this ABC scoring system can be used to predict the extent of tumor removal and that the scores reflect the surgical risk.

Introduction

Intracranial meningiomas constitute 15 to 20% of primary brain tumors [1]. Of these intracranial meningiomas, 20 to 30% are in the skull base [2]. Meningiomas located on the convexity are usually accessible, circumscribed, and well demarcated from the neural and vascular structures. In contrast, skull base meningiomas are extensive, invasive, and intimately associated with cranial nerves, vessels, and brainstem. The skull base meningiomas are difficult lesions to treat when insinuated among cranial nerves and vital neurovascular structures. Nowadays, different protocols are applied to deal with such tumors, including simple observation, partial resection, radiosurgery as primary or adjuvant therapy, and aggressive surgical removal. Nevertheless, large and giant meningiomas usually are surgical lesions because of the mass effect and involvement of the brain stem, cranial nerves, dural sinuses or vascular structures. ABC Surgical Risk Scale introduced in this

paper is simple, easy to remember, useful for determining the best management strategy for patients with SBM, and calculated on the basis of preoperative imaging analyses.

Methods

All patients presenting to Neurosurgical OPD or Emergency department of National Academy of Medical Sciences, Bir Hospital were initially examined by the Neurosurgical Resident in training under the supervision of Consultant Neurosurgeon. All patients were examined and sent laboratory investigation with radiological investigation required for the diagnosis. We validated the predictive accuracy of this scoring system in 25 consecutive cases treated surgically between January 2017 and December 2018, including both primary and repeated surgeries. We classified each case as GTR, NTR, or STR, according to the intraoperative findings and post-operative MR imaging findings, defined in terms of the Simpson grading system: [3,4] GTR matches Simpson

Grade I and II, defined as showing no intraoperative evidence of residual tumor and no evidence of contrast-enhancing tumor on postoperative MR images; NTR matches Simpson Grade III, defined as 1) intraoperatively observed residual tumor despite negative postoperative imaging, 2) extracavernous enhancing tumor < 1 cm³ on postoperative contrast enhanced axial images, and/or 3) persistent or residual CS tumor of any volume. The designation STR matches Simpson Grade IV and V and was defined as > 1 cm³ of extra- cavernous residual enhancing tumor on postoperative MR images.

The ABC Surgical Risk Scale⁴

- Attachment Size (A)

Attachment size was defined as the largest diameter on axial, coronal, or sagittal MR images, measured in centimeters, and scored as follows: ≤ 2 cm, 0 points; 2-4 cm, 1 point; and ≥ 4 cm, 2 points.

- Arterial Involvement (AI)

Arterial involvement was scored as follows: no involvement, 0 points; 1 artery involved, 1 point; and multiple arteries involved, 2 points.

- Brainstem Contact (B)

Brainstem contact was scored as follows: visible CSF space on MR images, 0 points; no visible CSF space, 1 point; and perifocal edema and no visible CSF space, 2 points.

- Central Cavity (C)

Central cavity is the space at the base of the skull delimited by the dural entry of CN II-XII. Skull base meningiomas that were located completely outside this space were defined as “outside” the central cavity and if it is within the boundaries it was defined as “inside” the cavity. Partial involvement describes SBMs that extended into the central cavity.

Location with respect to the central cavity was scored as follows: tumor completely outside the cavity, 0 points; partial involvement of the cavity, 1 point; and tumor mostly within the cavity, 2 points.

- Cranial Nerve Involvement (CN)

Cranial nerve involvement was scored as follows: no involvement, 0 points; single nerve groups involved, 1 point; and multiple nerve groups involved, 2 points.

		POINTS		
		0	1	2
A	Attachment Size	<2 cm	2-4 cm	>4 cm
	Arterial Involvement	None	Single	Multiple
B	Brainstem Contact	CSF space visible	No CSF space visible	Perifocal Oedema
C	Central Cavity	Outside	Partial involvement	Inside
	Cranial Nerve Group Involvement	None	one	>=2

Results

This group of cases involved 8 males and 17 female patients, with a mean age of 49.6 ± 8.7 years (Figure 1). The major location of the SBM was the anterior cranial fossa in 44% of the cases, anterior and middle cranial fossae in 20%, middle cranial fossa in 16 %, middle and posterior cranial fossae in 8 %, posterior cranial fossa in 8%, and anterior, middle, and posterior cranial fossae in 4% (Figure 2). The extent of resection was GTR in 72% (18 cases), NTR in 16% (4 cases), and STR in 12% (3 cases). In this series, the anterior cranial fossa was the most common location of the SBM (Table 1).

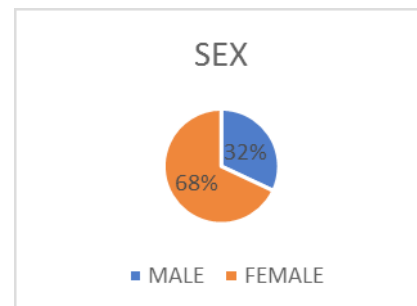


Figure 1: Figure showing frequency of sex.

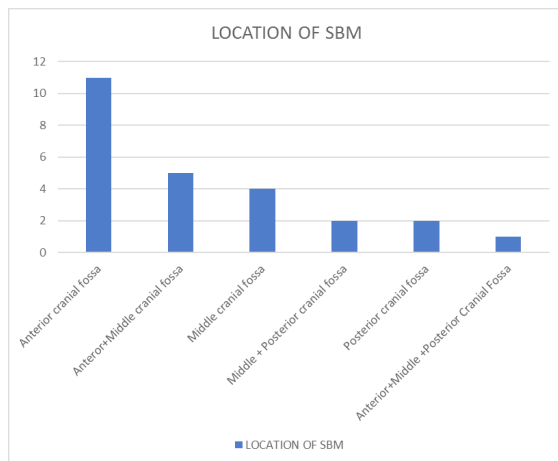


Figure 2: Figure showing location of SBM.

S.NO	A	AI	B	C	CN	TOTAL	RESECTION	
							GTR	
1	2	0	0	0	0	2	✓	
2	2	2	1	1	1	7		X
3	1	2	2	2	2	9		X
4	2	2	0	0	0	4	✓	
5	2	2	0	1	0	5	✓	
6	1	1	0	0	0	2	✓	
7	2	2	1	1	1	7		X
8	2	2	1	0	0	5	✓	
9	1	2	2	2	2	9		X
10	1	1	0	0	0	2	✓	
11	2	2	1	0	0	5	✓	
12	1	2	2	2	2	9		X
13	2	2	0	1	0	5	✓	
14	2	0	0	0	0	2	✓	
15	2	0	0	0	0	2	✓	
16	1	1	0	0	0	2	✓	
17	2	2	0	1	0	5	✓	
18	2	2	0	1	0	5	✓	
19	2	2	0	0	0	4	✓	
20	2	2	1	0	0	5	✓	
21	2	2	1	1	1	7		X
22	2	2	1	0	0	5	✓	
23	2	2	1	0	0	5	✓	
24	2	2	0	1	0	5	✓	
25	1	2	2	2	2	9		X

Table 1: Showing the Gross Total Excision and total scoring as per ABC scoring system.

Discussion

Because of the deep location of SBMs and the possible involvement of arteries and CNs and of adhesion to the brainstem, it can be difficult to discern the best treatment strategy for a given case. The possibilities are surgery, radiation, and/or observation. A practical risk scale should be simple and easy to recall and should provide a straightforward preoperative determination. The ABC Surgical Risk Scale meets these criteria. A practical protocol for risk assessment will have tremendous benefits for the surgeon and patient because it will allow rational decision-making about the treatment that is most likely to minimize the risk of complications. A grading system that does not take the lower CNs into account results in errors, because the surgery is most difficult when the SBM is located in the posterior cranial fossa [5,6] The benefit of focusing on the posterior cranial fossa in our scoring system is that many factors influence tumor removal in this space, which is the tightest and complex of the cranial fossae. In fact, the results of our study indicate that SBMs located in the posterior cranial fossa are the most difficult to resect.

We divided cranial nerves as four groups. Group 1 (optic nerve), visual function; Group 2 (oculomotor, abducens, trigeminal, and trochlear nerves), ocular motility and facial sensory functions; Group 3 (facial, vestibular, and cochlear nerves), facial motor and hearing; and Group 4 (glossopharyngeal, vagus, accessory, and hypoglossal nerves), deglutition and vocal functions. Kawase, et al. [7] and Sekhar, et al. [8] classified meningioma stages according to the relationship between the brainstem and the tumors. ABC Surgical Risk Scale can be used to predict the likelihood of complete resection of a given SBM, and of a positive outcome in terms of an improvement in pre-operative symptoms. Therefore, this scale can be very useful both for determining the best treatment modality for a given SBM case and for explaining the surgical risk to the patient.

Conclusion

ABC Surgical Risk Scale represents a very simple and useful scoring tool that can be taken in the consideration in the clinical practice for the pre-operative prediction of the extent of tumor removal. Use of this scoring system will assist surgeons in making informed decisions about the best treatment modality to offer to the patients.

References

1. Cushing H, Eisenhardt L (1986) Meningiomas: their classification, regional behavior, life history, and surgical end results. In: Zu 'lch KJ, ed. *Brain Tumors: Their Biology and Pathology*. New York: Springer-Verlag 1: 380-383.
2. Lefkowitz MA, Hinton DR, Weiss MH, Giannotta SL, Couldwell WT (1997) Prognostic variables in surgery for skull base meningiomas. *Neurosurg Focus* 2: 2.
3. Simpson D (1957) The recurrence of intracranial meningiomas after surgical treatment. *J Neurol Neurosurg Psychiatry* 20: 22-39.
4. Adachi K, Kawase T, Yoshida K, YazaKi T, Onozuka S (2009) ABC Surgical Risk Scale for skull base meningioma: a new scoring system for predicting the extent of tumor removal and neurological outcome *J Neurosurg* 111: 1053-1061.
5. Levine ZT, Buchanan RI, Sekhar LN, Rosen CL, Wright DC (1999) Proposed grading system to predict the extent of resection and outcomes for cranial base meningiomas. *Neurosurgery* 45: 221-230.
6. Saberi H, Meybodi AT, Rezai AS (2006) Levine-Sekhar grading system for prediction of the extent of resection of cranial base meningiomas revisited: study of 124 cases. *Neurosurg Rev* 29: 138-144.
7. Kawase T, Shiobara R, Toya S (1994) Middle fossa transpetrosal transtentorial approaches for petroclival meningiomas. Selective pyramid resection and radicality. *Acta Neurochir (Wien)* 129: 113-120.
8. Sekhar LN, Swamy NK, Jaiswal V, Rubinstein E, Hirsch WE, et al. (1994) Surgical excision of meningiomas involving the clivus: preoperative and intraoperative features as predictors of postoperative functional deterioration. *J Neurosurg* 81: 860-868.