



Cutting Study of the Ischiofemoral Ligament and Short External Rotator Tendons: Soft-Tissue Restraint of Hip Internal Rotation

Yoshifumi Harada¹, Koichi Akaishi², Yuji Yamamoto^{1*}, Ryo Inoue¹, Yasuyuki Ishibashi¹

¹Department of Orthopaedic Surgery, Hirosaki University Graduate School of Medicine, Zaifu-cho, Hirosaki, Japan

²Department of Orthopaedic Surgery, Hirosaki Memorial Hospital, Sakaizeki-Nishida, Hirosaki, Japan

*Corresponding author: Yuji Yamamoto, Department of Orthopaedic Surgery, Hirosaki University Graduate School of Medicine, 5 Zaifu-cho, Hirosaki, Aomori 036-8562, Japan. Tel: +81-172395083; Fax: +81-172363826; Email: yuji1112@hirosaki-u.ac.jp

Citation: Harada Y, Akaishi K, Yamamoto Y, Inoue R, Yasuyuki Ishibashi Y (2019) Cutting Study of the Ischiofemoral Ligament and Short External Rotator Tendons: Soft-Tissue Restraint of Hip Internal Rotation. J Orthop Res Ther 11: 1143. DOI: 10.29011/2575-8241.001143

Received Date: 10 July, 2019; **Accepted Date:** 19 July, 2019; **Published Date:** 24 July, 2019

Abstract

Background: The ischiofemoral ligament and short external rotator muscles stabilize the hip against posterior subluxation and dislocation. However, the biomechanical function of the ischiofemoral ligament and short external rotator muscles is still unclear. This study measured increases in the hip internal rotation angles after cutting the ischiofemoral ligament and the short external rotator tendons.

Methods: We performed total hip arthroplasty through an anterolateral-supine approach on 8 hips from 4 fresh-frozen cadavers. After arthroplasty, we measured the internal rotation angle with the hip flexed 90° at the following stages: after THA with the ischiofemoral ligament and the short external rotator tendons intact; after cutting the ischiofemoral ligament but leaving the short external rotator tendons intact; after cutting the conjoined tendon in the left hip; after cutting the obturator externus tendon in the right hip.

Results: The internal rotation angle increased $7.6 \pm 1.5^\circ$ after cutting the ischiofemoral ligament, $17.5 \pm 3.3^\circ$ after cutting the conjoined tendon and $7.0 \pm 1.6^\circ$ after cutting the obturator externus tendon. There was significant difference between the variation after cutting the conjoined tendon and after cutting the obturator externus tendon.

Conclusion: Cutting the ischiofemoral ligament, the conjoined tendon and the obturator externus tendon increased the hip internal rotation angles significantly. The greatest increase in the internal rotation angle was observed after cutting the conjoined tendon. Cutting the ischiofemoral ligament and the short external rotator tendons may cause excessive internal rotation, impingement, and dislocation after total hip arthroplasty.

Keywords: Conjoined tendon; Dislocation; Internal rotation; Ischiofemoral ligament; Obturator externus; Range of motion; Short external rotator muscles; Total hip arthroplasty

Abbreviations: ALSA: Anterolateral-Supine Approach; THA: Total Hip Arthroplasty

Introduction

The Anterolateral-Supine Approach (ALSA) is often used in Total Hip Arthroplasty (THA). This intermuscular surgical approach minimizes soft tissue injury while maintaining normal muscle function and joint stability [1]{Bossard, 2005 #5632}. The risk of dislocation is reduced by an anterior surgical approach

rather than a posterior surgical approach after THA. The risk of dislocation is even lower with an anterolateral approach [2]. Anatomical restraints of the hip joint are important for preventing impingement and subluxation after THA, with subsequent edge loading, high wear, or dislocation [3].

Preserving the posterior soft tissue is important for reducing posterior dislocation after THA. However, preserving the posterior soft tissue can make it difficult to access the femoral canal and prepare the femur during ALSA [4]. In some cases, the ischiofemoral ligament has to be detached at appropriate sites to clear the visual field and gain straight access to the femoral canal. Cutting the short external rotator tendons may be necessary to

elevate and move outward the femur to allow insertion of the stem. The short external rotator tendons include the piriformis tendon, obturator externus tendon, and the conjoined tendon of the obturator internus, gemellus superior, and gemellus inferior. The short external rotator tendons can be damaged during the capsular dissection and femoral broaching [5].

There is little data on precisely how the ischiofemoral ligament and short external rotator muscles contribute to stabilizing the hip joint and limiting hip internal rotation. This study was conducted to assess the soft-tissue restraint exerted by the ischiofemoral ligament and short external rotator muscles in hip internal rotation. We measured changes in the hip internal rotation angles after cutting the ischiofemoral ligament and the short external rotator tendons.

Materials and Methods

Cadaveric Specimens

This study was approved by our Institutional Review Board, and we followed institutional policies for cadaver use. We used 8 hips from 4 fresh-frozen cadavers (4 males, aged 67.8 ± 2.6 years at the time of death) donated for medical education and research. The specimens had no history of hip disease. Details of antemortem weight and mobility status were not available.

Surgical Procedures

One senior orthopaedic surgeon performed THA by ALSA for all samples. A G7 cup (Zimmer Biomet, Warsaw, Indiana) was implanted on the acetabular side of the hip, and a high offset tapered wedge stem (Taperloc Complete Microplasty, Zimmer Biomet) was used on the femoral side with a 32-mm delta ceramic femoral head (BIOLOX, CeramTec, Plochingen, Germany). The cadaver was positioned on the operating table in the supine position. After dividing the subcutaneous tissue and fascia, the interval between the tensor fasciae latae and the gluteus medius was opened bluntly by inserting a finger. No muscles were split or detached. The anterior and superior hip capsules and the iliofemoral and pubofemoral ligaments were totally resected, and the femoral neck was exposed. Standard techniques were used for the femoral neck osteotomy, acetabular preparation, and cup insertion. The cups were inserted in 20° anteversion and 45° of inclination (radiographic definition). The femur was placed in extension, rotated externally, and adducted. In this position, an elevating retractor was placed posterior to the greater trochanter to lever the femur out. After preparing the proximal femoral canal, the femoral stem was inserted while carefully preserving the ischiofemoral ligament and short external rotator tendon insertions (Figure 1).

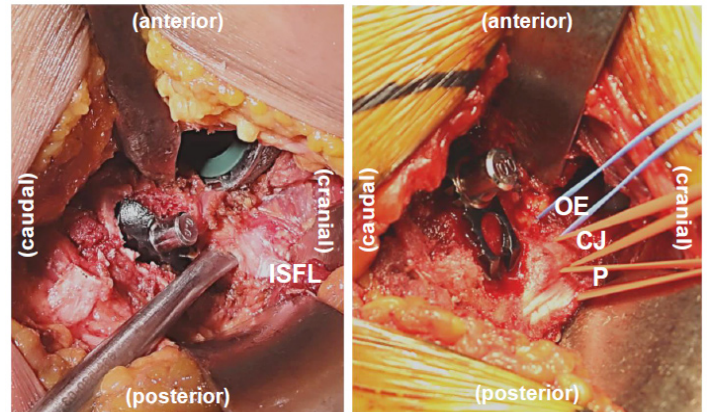


Figure 1: Photographs showing the left hip during total arthroplasty. ISFL, ischiofemoral ligament; P, piriformis tendon; CJ, conjoined tendon; OE, obturator externus tendon.

Measurement and Hip Position

We measured the increase in the internal rotation angle with the hip flexed 90° after cutting the ischiofemoral ligament, conjoined tendon and obturator externus tendon. The bilateral anterior superior iliac spine and longitudinal body axis was used as a reference level. A restraint band was placed on the lower leg 30 cm distal to the knee-joint line, and the band was pulled laterally with 20 N traction with the hip flexed 90° and the knee flexed 90° (Figure 2). With this method, the internal rotation torque for the hip joint was 6 Nm [6]. The traction force was indicated by a tensiometer. The hip internal rotation angles were measured using a goniometer. Internal rotation angle was measured at the following stages: after THA, with the ischiofemoral ligament and the short external rotator tendons intact; after cutting the ischiofemoral ligament but leaving the short external rotator tendons intact; after cutting the conjoined tendon in the left hip; and after cutting the obturator externus tendon in the right hip.

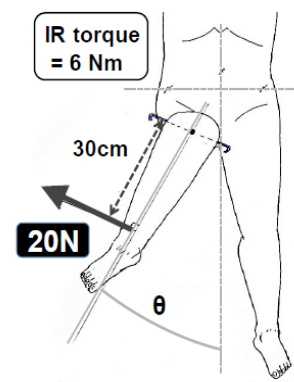


Figure 2: Measurement of the hip internal rotation (IR) angle. Torque amounting to 6 Nm was applied with the hip flexed 90° . θ : hip IR angle.

Statistical Analysis

We used paired t-test to compare the internal rotation angle between before cutting and after cutting on each tendon. We used Mann-Whitney U test to compare the variation of the internal rotation angle between cutting the conjoined tendon and cutting the obturator externus tendon. Data input and calculations were performed with the SPSS ver. 12.0 J (SPSS Inc., Chicago, IL, USA). All quantitative values are expressed as mean \pm standard error of mean. $P < 0.05$ was considered statistically significant.

Results

For eight samples, the internal rotation angle was $23.1 \pm 3.0^\circ$ after THA with ischiofemoral ligament sparing, and $30.8 \pm 3.9^\circ$ after cutting the ischiofemoral ligament (Figure 3).

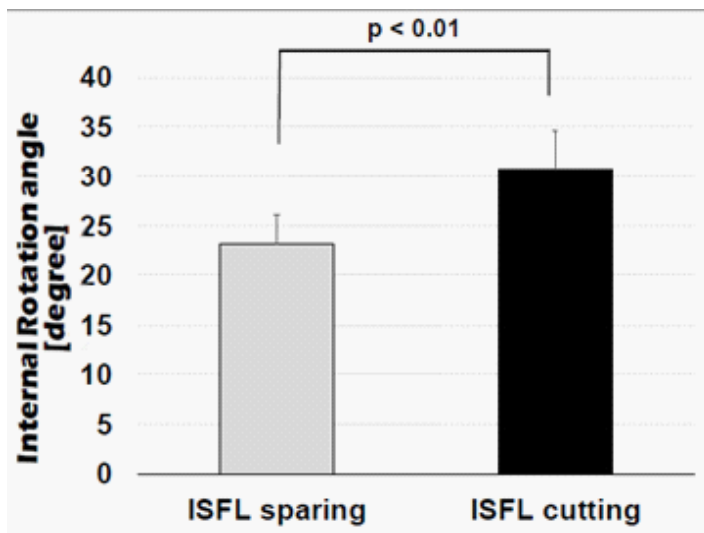


Figure 3: Hip internal rotation angle after cutting the Ischiofemoral Ligament (ISFL).

There was significant difference between before cutting and after cutting of the ischiofemoral ligament ($p < 0.01$). For four samples, the internal rotation angle was $33.5 \pm 6.7^\circ$ with the short external rotator tendons intact, and $51.0 \pm 9.0^\circ$ after cutting the conjoined tendon (Figure 4). There was significant difference between before cutting and after cutting of the conjoined tendon ($p = 0.013$).

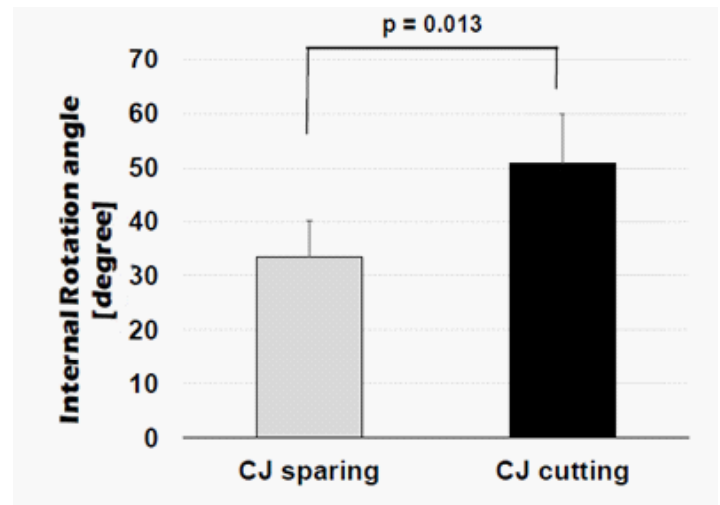


Figure 4: Hip internal rotation angle after cutting the Conjoined tendon (CJ).

For four samples, the internal rotation angle was $28.0 \pm 4.7^\circ$ with the short external rotator tendons intact, and $35.0 \pm 5.6^\circ$ after cutting the obturator externus tendon (Figure 5).

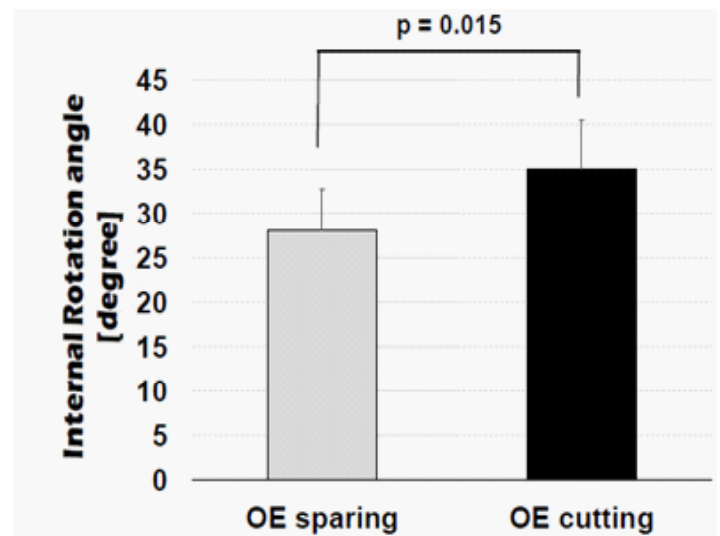


Figure 5: Hip internal rotation angle after cutting the obturator Externus Tendon (OE).

There was significant difference between before cutting and after cutting of the obturator externus tendon ($p = 0.015$). The internal rotation angle increased $7.6 \pm 1.5^\circ$ after cutting the ischiofemoral ligament, $17.5 \pm 3.3^\circ$ after cutting the conjoined tendon, and $7.0 \pm 1.6^\circ$ after cutting the obturator externus tendon (Table 1). There was significant difference between the variation after cutting the conjoined tendon and after cutting the obturator externus tendon ($p = 0.04$).

Table 1: Changes in the hip Internal Rotation (IR) angle. ISFL, ischiofemoral ligament; CJ, conjoined tendon; OE, obturator externus tendon.

	Post-THA	ISFL cutting	CJ cutting
IR angle of the Lt. hip	$25.0 \pm 5.9^\circ$	$33.5 \pm 6.7^\circ$	$51.0 \pm 9.0^\circ$
	Post-THA	ISFL cutting	OE cutting
IR angle of the Rt. hip	$21.3 \pm 2.5^\circ$	$28.0 \pm 4.7^\circ$	$35.0 \pm 5.6^\circ$
	ISFL cutting	CJ cutting	OE cutting
Variation of The hip IR angle	$+ 7.6 \pm 1.5^\circ$	$+ 17.5 \pm 3.3^\circ$	$+ 7.0 \pm 1.6^\circ$
		$p = 0.040$	

Discussion

This study revealed that cutting the ischiofemoral ligament and the short external rotator tendons increased significantly the hip internal rotation angles. We observed the greatest increase in the hip internal rotation angle after cutting the conjoined tendon. Dislocations after THA involve factors such as the femoral stem design, acetabular component orientation, surgical approach, and patient-specific factors such as the femoral head size and soft-tissue laxity [7]. Posterior dislocation, which is most common, tends to occur with hip flexion and internal rotation. Bony impingement is a risk factor for dislocation. To decrease the dislocation rate, it is important to limit excessive internal rotation. Preserving the posterior soft tissue structures of the hip should decrease the risk of posterior dislocation after THA.

The ischiofemoral ligament was more important for restraining internal hip rotation. The ischiofemoral ligament reinforces the posterior portion of the articular capsule [8] and cradles the femoral head in deep hip flexion, thereby stabilizing the hip against posterior subluxation and dislocation [9]. The ischiofemoral ligament originates at the ischial circumference of the acetabular rim and attaches to the base of the greater trochanter, and it is presumed to stretch during internal rotation of the hip based on anatomy. A biomechanical study showed that 10° or 20° hip abduction with maximal internal rotation places high strain on the ischiofemoral ligament [10]. The ischiofemoral ligament

was the greatest contributor to internal rotation in the hip capsular ligaments [11].

We observed the greatest increase in the internal rotation angle of the hip after cutting the conjoined tendon. An electromyography study reported that the obturator internus muscle was the first to become active in external hip rotation [12]. The obturator internus muscle is considered the agonist for hip external rotation. This might explain why releasing the conjoined tendon produced the greatest increase in internal hip rotation. The short external rotators of the hip have been likened to a rotator cuff for the hip in terms of their potential as dynamic joint stabilizers [13]. They act as postural muscles, holding the femoral head in the acetabulum as the hip moves. The anatomy of the short external rotator muscles in the hip is described in previous cadaveric studies [5,13-16]. The obturator internus tendon attaches to the sloping anterosuperior medial surface of the greater trochanter [13]. Ito, et al. reported that the insertion of the conjoined tendon extends to the anterosuperior aspect of the greater trochanter [5]. There is a risk of damage to the tendons during capsular release, and the conjoined tendon is especially at risk due to its insertion to the greater trochanter.

This study had some limitations that should be noted. First, the study included only 8 hips from 4 cadavers. In addition, all specimens were from elderly donors, and we did not have detailed information about their body size or bony morphology. Second, the physical and mechanical properties of cadaveric tissue may differ from those of tissue *in vivo*. This study does not account for dynamic sources of stability. Third, the piriformis tendon was not evaluated. The attachment site of the piriformis tendon was posterosuperior to the attachment of the conjoined tendon and far from the femoral neck [Ito]. Therefore, we thought the risk of damage to the piriformis tendon was lower than the conjoined tendon and the obturator externus tendon in THA.

Conclusion

Cutting the ischiofemoral ligament, the conjoined tendon and the obturator externus tendon increased the hip internal rotation angles significantly. The greatest increase in the internal rotation angle was observed after cutting the conjoined tendon. Damage to the ischiofemoral ligament and short external rotator muscles could cause excessive hip internal rotation after THA, leading to impingement and dislocation. We believe that appropriate soft-tissue balancing is important for achieving good clinical results in THA. ALSA improves the surgeon's ability to control the soft-tissue balance in THA because it provides a satisfactory observation field for identifying the ischiofemoral ligament and short external rotator tendons. Improving surgical techniques for THA to preserve the posterior structures of the hip will help to reduce post-THA dislocation.

References

1. Agten CA, Sutter R, Dora C, Pfirmann CW (2017) MR imaging of soft tissue alterations after total hip arthroplasty: comparison of classic surgical approaches. *Eur J Radiol* 27: 1312-1321.
2. Sheth D, Cafri G, Inacio MC, Paxton EW, Namba RS (2015) Anterior and Anterolateral Approaches for THA Are Associated with Lower Dislocation Risk Without Higher Revision Risk. *Clin Orthop Relat Res* 473: 3401-3408.
3. van Arkel RJ, Amis AA, Jeffers JR (2015) The envelope of passive motion allowed by the capsular ligaments of the hip. *J Biomech* 48: 3803-3809.
4. Nogler M, Krismer M, Hozack WJ, Merritt P, Rachbauer F, et al. (2006) A double offset broach handle for preparation of the femoral cavity in minimally invasive direct anterior total hip arthroplasty. *J Arthroplasty* 21: 1206-1208.
5. Ito Y, Matsushita I, Watanabe H, Kimura T (2012) Anatomic mapping of short external rotators shows the limit of their preservation during total hip arthroplasty. *Clin Orthop Relat Res* 470: 1690-1695.
6. van Arkel RJ, Ng KCG, Muirhead-Allwood SK, Jeffers JRT (2018) Capsular Ligament Function After Total Hip Arthroplasty. *J Bone Joint Surg Am* 100: e94.
7. Nevelos J, Johnson A, Heffernan C, Macintyre J, Markel DC, et al. (2012) What factors affect posterior dislocation distance in THA? *Clin Orthop Relat Res* 471: 519-526.
8. Wagner FV, Negrao JR, Campos J, Ward SR, Haghghi P, et al. (2012) Capsular ligaments of the hip: anatomic, histologic, and positional study in cadaveric specimens with MR arthrography. *Radiology* 263: 189-198.
9. van Arkel RJ, Amis AA, Cobb JP, Jeffers JR (2015) The capsular ligaments provide more hip rotational restraint than the acetabular labrum and the ligamentum teres: an experimental study. *Bone Joint J* 97: 484-491.
10. Hidaka E, Aoki M, Izumi T, Suzuki D, Fujimiya M (2014) Ligament strain on the iliofemoral, pubofemoral, and ischiofemoral ligaments in cadaver specimens: biomechanical measurement and anatomical observation. *Clin Anat* 27: 1068-1075.
11. Martin HD, Savage A, Braly BA, Palmer IJ, Beall DP, et al (2008) The function of the hip capsular ligaments: a quantitative report. *Arthroscopy* 24: 188-195.
12. Hodges PW, McLean L, Hodder J (2014) Insight into the function of the obturator internus muscle in humans: observations with development and validation of an electromyography recording technique. *J Electromyogr Kinesiol* 24: 489-496.
13. Pine J, Binns M, Wright P, Soames R (2011) Piriformis and obturator internus morphology: a cadaveric study. *Clin Anat* 24: 70-76.
14. Cooper HJ, Walters BL, Rodriguez JA (2015) Anatomy of the hip capsule and pericapsular structures: A cadaveric study. *Clin Anat* 28: 665-671.
15. Philippon MJ, Michalski MP, Campbell KJ, Goldsmith MT, Devitt BM, et al. (2014) Surgically Relevant Bony and Soft Tissue Anatomy of the Proximal Femur. *Orthop J Sports Med* 2: 2325967114535188.
16. Tamaki T, Nimura A, Oinuma K, Shiratsuchi H, Iida S, et al. (2014) An anatomic study of the impressions on the greater trochanter: bony geometry indicates the alignment of the short external rotator muscles. *J Arthroplasty* 29: 2473-2477.