

## Wandering Spleen Presents as an Acute Surgical Emergency: A Case Report

Annie Reiss<sup>1</sup>, Safi Khuri<sup>1,2\*</sup>, Kenan Hallon<sup>1</sup>, Ahmad Assalia<sup>1,3</sup>, Sa'd Sayida<sup>1,3</sup>

<sup>1</sup>Department of General Surgery, Rambam Health Care Campus, Haifa, Israel

<sup>2</sup>HPB and Surgical Oncology Unit, Rambam Health Care Campus, Haifa, Israel

<sup>3</sup>Advanced Laparoscopic and Bariatric Surgery Unit, Rambam Health Care Campus, Haifa, Israel

\*Corresponding author: Safi Khuri, Department of General Surgery, Rambam Health Campus, Haifa, Israel. Email: s\_khuri@rambam.health.gov.il

**Citation:** Reiss H, Khuri S, Hallon K, Assalya A, Sayida S (2019) Wandering Spleen Presents as an Acute Surgical Emergency: A Case Report. J Surg 13: 1236. DOI: 10.29011/2575-9760.001236

**Received Date:** 27 June, 2019; **Accepted Date:** 01 July, 2019; **Published Date:** 05 July, 2019

### Abstract

**Introduction:** The wandering spleen is a very rare cause of acute abdominal pain, occurring mostly in children and females of reproductive age. It is characterized by weakness or absence of one or more of the ligaments that hold the spleen in its normal location at the left upper quadrant of the abdomen. Herein, we present a rare case of wandering spleen in a patient with intestinal malrotation and history of an unknown abdominal surgery in the left upper quadrant.

**Case Presentation:** A 37-year-old female patient, presented to our Emergency Medicine department with acute abdominal pain. She was diagnosed with a wandering spleen and intestinal malrotation. Prompt laparotomy was performed, and the patient underwent splenectomy, appendectomy and intestinal fixation.

**Discussion:** We discuss the potential association between the patient's wandering spleen, intestinal malrotation and prior surgery. Congenital malformation of peritoneal ligaments may account for the patient's wandering spleen as well as her intestinal malrotation. The possibility of a repaired congenital diaphragmatic hernia at infancy would support a congenital cause. An acquired laxity of ligaments, more common among women who have experienced pregnancy, provides an alternative though incomplete explanation.

**Conclusion:** We hope this unusual case would raise awareness of the rare diagnosis of the wandering spleen and its potentially associated anomalies.

### Introduction

Wandering spleen, also known as hypermobile spleen, is a very rare clinical entity with an estimated reported incidence of <0.5%. It occurs due to the absence or maldevelopment of the splenic suspensory ligaments [1]. Although it can be an incidental radiologic/operative finding, it can present as an acute/ chronic abdominal pain due to torsion of the wandering spleen or as a palpable abdominal mass. The previously mentioned variable clinical presentations, along its rare incidence, makes its diagnosis challenging for the treating physician.

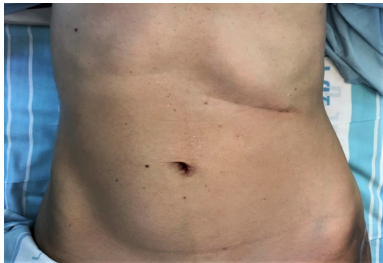
### Case Presentation

A 37-year-old healthy female patient, presented to our Emergency Medicine department with a three-day history of

diffuse abdominal pain, which increased on the day of admission, associated with the sudden appearance of a palpable mass in the right lower quadrant of the abdomen. The patient had no recent history of fever and no gastrointestinal, urinary or gynecological complaints. The patient's history included three normal vaginal deliveries, years before. She also underwent an abdominal surgery for unknown reason at one year of age. Neither the patient nor family members had any recollection or records that would help ascertain the type of surgery.

Upon her admission, the patient's vital signs were within normal limits. Physical examination revealed a slightly distended abdomen, with a palpable sensitive mass at the right lower quadrant and no signs of peritonitis (Figure 1). Digital rectal exam was normal without palpable masses. Complete blood count, liver and

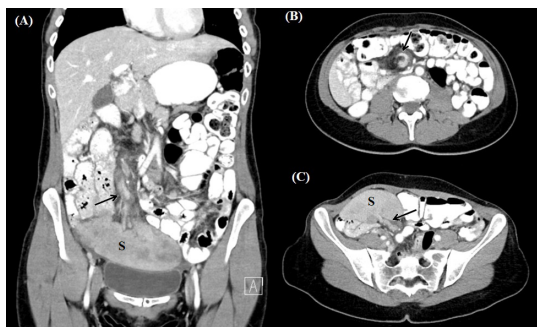kidney function tests were within normal limits. Urine analysis revealed slightly increased urine amylase. Gynecological exam, including Trans-Vaginal Ultrasound (US), was normal. A urine test was negative for pregnancy.



**Figure 1:** Inspection of the patient's abdomen. A protruding mass can be seen in the right lower quadrant. A surgical scar can be seen in the left upper quadrant.

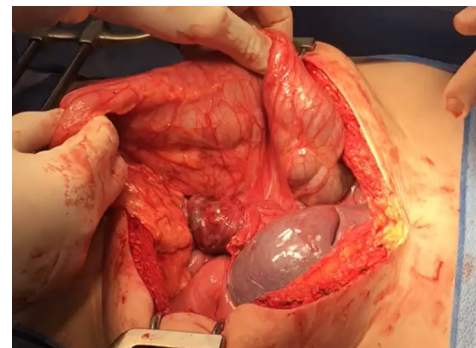
Abdominal US revealed a homogenous elongated mass in the patient's right lower abdomen, separated from adjacent pelvic organs.

A contrast-enhanced Computer Tomography (CT) scan of the abdomen and pelvis revealed an enlarged spleen, measuring 15 cm, located at the abdominopelvic junction rather than the left upper quadrant (Figure 2). Torsion of the splenic vessels were suspected due to positive whirl sign, along with the presence of several splenic hypodense lesions that appeared to be infarcts. The tail of the pancreas was pulled in the right anterior direction. The duodenum, normally crossing the midline from right to left, was found on the right side of the abdomen along with the jejunum, while the ileum, cecum and colon were found on the left. A normal appearing appendix was seen on the left side of the abdomen. The aforementioned CT scan finding were highly suggestive for the diagnosis of a wandering spleen and intestinal malrotation.

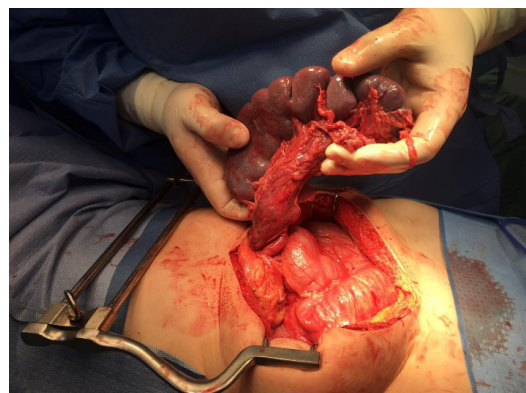

**Figure 2:** Computed tomography scan of the patient's abdomen and pelvis. (A): Coronal view. The wandering or prolapsed spleen (S) is seen in the abdominopelvic junction, compressing the urinary bladder. Torsion of the vascular pedicle is also seen (arrow). (B): Axial view, showing the whirl sign, representing torsion of the splenic vessels. (C): Axial view of the torsed splenic pedicle (arrow) entering the splenic hilum. Hypodense areas, likely infarcts, are visible in the splenic parenchyma.

Due to suspected splenic infarction and a concern of torsion of the small bowel mesentery, the patient underwent an emergent exploratory laparotomy. On exploration of the abdomen, a large and mobile spleen was found in the right lower abdomen (Figure 3). The spleen appeared congested with patches of infarction, and torsion of its vascular pedicle was evident. The small intestine was viable, but abnormally located: the duodenum and jejunum were found in the right upper quadrant, while the cecum was entirely mobile and in the left abdomen, with a normal appearing appendix. Despite partial recovery after detorsion, patches of ischemic splenic tissue were still grossly evident, and splenopexy was unfortunately inappropriate (Figure 4). Total splenectomy and appendectomy (due to cecal malposition) were performed. The cecum was fixated in the right lower abdomen. Her post-operative period was uneventful, and she discharged home on post-operative day 5. Histopathological report revealed spleen with extensive areas of infarction. 2 months following discharge, patient is in good general condition, without any complaint.



**Figure 3:** Intraoperative image, showing the prolapsed spleen at the right lower abdomen. The torsed vascular pedicle is visible at the center of the image (arrow). The large intestine is seen on the left side of the abdomen.



**Figure 4:** The enlarged prolapsed spleen with its torsed splenic pedicle, lifted from the right lower quadrant and detorsed. Areas of infarct are grossly apparent in the splenic parenchyma. Insufficient improvement following detorsion indicated the need for splenectomy.

## Discussion

This is an unusual case of a young woman diagnosed with a wandering spleen and previously unknown intestinal malrotation. We discuss the potential association between these conditions, as well as their connection to the patient's unknown prior abdominal surgery. A wandering spleen is a mobile spleen, abnormally located or oriented due to the hyperlaxity of its ligamentous attachments [2]. It may be displaced from its normal location in the left upper quadrant, raising the risk of torsion around its elongated vascular pedicle and consequent splenic infarction. Clinical presentation may be asymptomatic, chronic intermittent abdominal pain due to recurring torsion and detorsion, or acute abdominal pain due to vessel obstruction and infarct as was the case of our patient. Physical examination may reveal a palpable, solid, oval abdominal mass. Imaging studies are generally required for definitive diagnosis, and CT scan is the imaging modality of choice. Treatment options include operative vs non-operative management. Non-operative management is usually not recommended, as the risk for vascular torsion and splenic infarction is more than 60%. Surgical intervention includes detorsion and splenopexy or splenectomy, and depends on the vascularity of the spleen. Detorsion and splenopexy can be done when there is no vascular compromise, to reduce post-splenectomy risks, such as overwhelming postsplenectomy sepsis, while splenectomy is recommended in case of splenic infarction.

As wandering spleen is a very rare clinical entity, other more common differential diagnosis, such as incarcerated ventral hernia, ovarian torsion or periapical abscess, are usually highly suspected. The wandering spleen is a rare condition, and not easily diagnosed. Reviewing the English literature revealed approximately five hundred cases that were reported [3]. One third of cases affects children, present equally in both sexes, and presumably stem from congenital malformation of the splenic ligaments. Over the age of ten, the incidence among females is approximately tenfold, with an average age of 20-40 years at presentation. Laxity of the splenic ligaments may be congenital, for instance due to an underlying connective tissue disorder, or acquired; it may be exacerbated by trauma or splenomegaly, and may stem from the hormonal effects of pregnancy, explaining the female predominance [2]. An unusual finding in our patient's CT scan and abdominal exploration was the abnormally located intestine. Intestinal malrotation is mostly discussed regarding the pediatric population, as 90% of cases are discovered by one year of age. However, there are patients who enter adulthood undiagnosed. Kapfer and Rappold discuss adult cases, among them a previously undiagnosed 80-year-old man [4]. Apart from fetal ultrasound during her pregnancies, our patient had no previous abdominal imaging. We cannot therefore determine with certainty whether this was a case of asymptomatic congenital malrotation, or a laxity of peritoneal attachments combined with the sudden descent of the patient's spleen toward the pelvis that displaced the bowel. A review of the literature revealed a case of

acquired wandering spleen with intestinal malrotation in a 20-year-old female, described by Dalpe and Cunningham [5]. The authors suggested that both the malrotated bowel and the wandering spleen could be attributable to malformed peritoneal attachments, implying a congenital cause of ligamentous laxity. That patient, however, had additional developmental anomalies that supported this claim. Ooka et al. presented a case of a 22-year-old male with wandering spleen, gastric volvulus and intestinal malrotation [6]. They also suggest a common etiology for the malfixation of the bowel, mesentery and spleen.

History and physical examination indicated our patient underwent an unknown abdominal surgery in her left upper quadrant before the age of one year. Possibilities include prior splenopexy, supporting a congenital issue with spleen fixation; other splenic procedures such as splenic cystectomy; and surgery on adjacent structures, for instance the diaphragm. Had the patient been born with a left-sided Congenital Diaphragmatic Hernia (CDH), and underwent surgery to repair the defect, this may have reduced the strength of the splenic ligaments. We could not confirm nor refute our suspicion with the available history, and our intraoperative exploration revealed neither mesh nor signs of prior splenopexy or primary repair of the diaphragm. Our literature review revealed a case of an 11-year-old female with splenic torsion and a history of left-sided CDH repaired shortly after birth, reported by Mehta, et al. [3]. Four other cases of wandering spleen following CDH repair have been reported. In such cases, a wandering spleen may result from the primarily abnormal splenic attachments due to splenic herniation into the left hemithorax during pregnancy, or from a loss of retroperitoneal fixation following the diaphragmatic repair. An association between CDH and intestinal malrotation has been established. The herniation of abdominal viscera in the thorax is presumed to promote nonfixation of the mesentery and malrotation of the intestinal tract.

In our literature review, we have found one case of a wandering spleen with intestinal malrotation and a history of CDH repair. Hosgor et al. reviewed 20 children with a late presentation of congenital diaphragmatic hernia, 12 of whom had intestinal malrotation. Among them was a 10-year-old female, diagnosed with malrotation and a wandering spleen. This patient presented with abdominal pain, anorexia, fatigue, severe failure to thrive and a palpable abdominal mass. She had been initially misdiagnosed with malignancy and treated accordingly; when correctly diagnosed with congenital diaphragmatic hernia, the patient underwent primary diaphragm repair, a Ladd procedure and splenopexy [7]. The coexistence of a wandering spleen, intestinal malrotation and a suspected congenital diaphragmatic hernia in a single patient is extremely rare. The suggested mechanisms of congenital vs. acquired tissue laxity may help further the discussion of this uncommon condition. We encourage health professionals to consider the diagnosis of wandering spleen in patients presenting

with acute abdominal pain, especially in those with intestinal malrotation and/or a history of surgery in the left upper quadrant.

## Conclusion

In conclusion, we present a rare case of wandering spleen and intestinal malrotation in an otherwise healthy female with history of an unknown abdominal procedure at infancy. The wandering spleen is a rare, yet noteworthy cause of acute abdominal pain. We hope to raise awareness of this rare entity and suggest future directions of study regarding its etiology and associated anomalies.

## References

1. FARIDI MS, KUMARA, INAM L, SHAHID R (2014) Wandering Spleen- A Diagnostic Challenge: Case Report and Review of Literature. *Malays J Med Sci* 21: 57-60.
2. Reisner DC, Burgan CM (2018) Wandering Spleen: An Overview. *Current Problems in Diagnostic Radiology* 47: 68-70.
3. Mehta A, Vana PG, Glynn L (2013) Splenic torsion after congenital diaphragmatic hernia repair: Case report and review of the literature. *Journal of Pediatric Surgery* 48: 29-31.
4. Kapfer SA, Rappold JF (2004) Intestinal malrotation-not just the pediatric surgeon's problem. *Journal of the American College of Surgeons* 199: 628-635.
5. Dalpe C, Cunningham M (2003) Wandering spleen as an asymptomatic pelvic mass. *Obstetrics & Gynecology* 101: 1102-1104.
6. Ooka M, Kohda E, Iizuka Y, Nagamoto M, Ishii T, et al. (2013) Wandering spleen with gastric volvulus and intestinal non-rotation in an adult male patient. *Acta Radiologica Short Reports* 2.
7. Hosgor M, Karaca I, Karkiner A, Ucan B, Temir G, et al. (2004) Associated malformations in delayed presentation of congenital diaphragmatic hernia. *Journal of Pediatric Surgery* 39: 1073-1076.