



Granular Cell Tumor of the Scrotum in a Black African: Case Report of a Very Rare Condition

Edoise M. Isiwele^{1*}, Theophilus Ugbem², Terence A. Azeke³

¹Department of Urology, University of Calabar Teaching Hospital, Nigeria

²Department of Histopathology, University of Calabar Teaching Hospital, Nigeria

³Department of Anatomic Pathology, Irrua Specialist Teaching Hospital, Nigeria

***Corresponding author:** Isiwele EM, Department of Urology, University of Calabar Teaching Hospital, Nigeria. Tel: +234-8039677046; Email: eddieisiwele@yahoo.com

Citation: Isiwele EM, Ugbem T, Azeke TA (2019) Granular Cell Tumor of the Scrotum in a Black African: Case Report of a Very Rare Condition. Curr Trends Med Sur Urol 1: 102. DOI: 10.29011/CTMSU-102.100102

Received Date: 02 May, 2019; **Accepted Date:** 27 May, 2019; **Published Date:** 03 June, 2019

Abstract

Granular Cell Tumor (GCT) of the scrotum is very rare. Generally, granular cell tumors are more common in Blacks. However, this may not be the case with scrotal granular cell tumors. We report the first case seen in a native Black African patient to our knowledge. The 31-year old man presented with a nodular scrotal mass found on histology to be GCT. On immunohistochemistry it was found to have strong reactivity to S - 100 and Vimentin. A strong index of suspicion is needed in making a clinical diagnosis, as the lesion can easily be missed.

Keywords: Black African; Granular Cell Tumor (GCT); Immunohistochemistry; Scrotum; Vimentin

Introduction

Granular Cell Tumor (GCT) is a tumor commonly affecting the head and neck but which can affect any part of the body. They are soft tissue tumors thought to be of neural origin [1,2]. Since 1926 when Abrikossoff first described the condition, some few hundred cases have been reported in literature [3,4]. Most cases are benign with less than 1-2% of cases being reported to be malignant. While benign cases are usually small sized and slow growing, the malignant varieties rapidly grow and assume large proportions and also rapidly metastasize [5-7]. Granular cell tumor of the scrotum is very rare with only 11 cases reported so far in literature. In Nigeria, nine cases of granular cell tumor of the breast seen over a 10-year period were reported by Imam, et al. [8] in their study in Kano while a case of granular cell tumor of the mons pubis was reported by Aniebue and Olusina [9] in Enugu in 2009. No case of scrotal GCT has been reported in literature in the country, to our knowledge. This therefore represents the first case from Nigeria and indeed Africa being reported in literature.

Case Description

A 31 year old male Nigerian presented to the Urology Clinic of University of Calabar Teaching Hospital, Nigeria with history of a small and firm growth on the underside of his scrotum of 5 months' duration. He had not noticed any appreciable change in its size since it was first noticed. It was not associated with pain or pruritus and there were no similar lesions elsewhere. There was no history of preceding trauma or infection at the region affected. On physical examination, there was a dark colored, non-tender, nodular mass, 0.6 cm in diameter, on the lower aspect of the left hemi-scrotum with well-defined edges. Other aspects of scrotal examination were essentially normal. Results of routine investigations were essentially normal with scrotal ultrasound revealing a rounded homogenous solid mass 0.54 × 0.44 cm on the left side of the median raphe with a suspicion of neuroma. The mass was subsequently excised with a rim of about 1 cm of normal tissue. Histological analysis showed irregular groups of polyhedral cells with indistinct borders and abundant eosinophilic granules in the cytoplasm and relatively small hyperchromatic nuclei that are centrally placed (Figure 1). Immunohistochemistry revealed the tumor to be strongly positive both for S - 100 and Vimentin (Figure 2). Post-operative condition was satisfactory and follow up 12 months' post-excision has shown no recurrence.

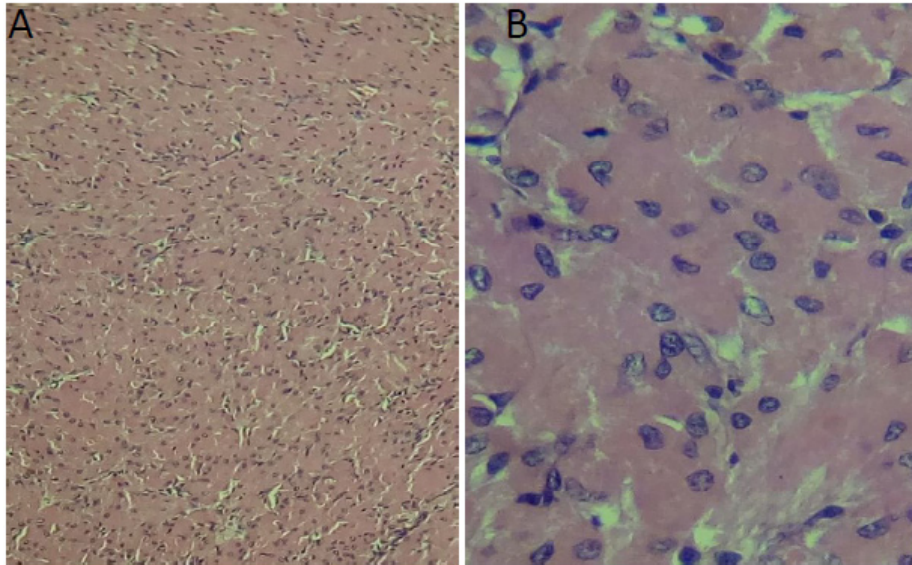


Figure 1: Histological section of the scrotal granular cell tumor (A: H and E x100, B: H and E x400 magnification).

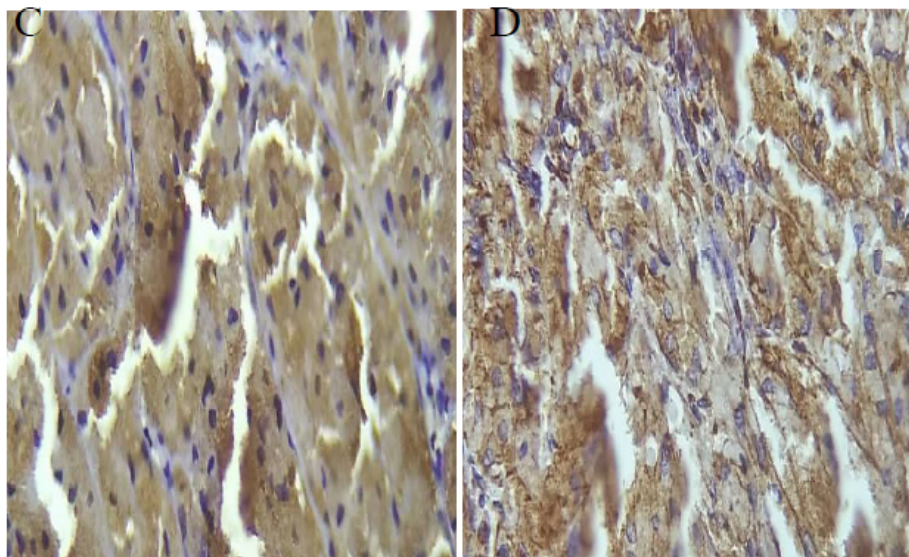


Figure 2: Immunohistochemistry showing tumor cells strongly positive for (C: S - 100, D: Vimentin).

Discussion

Granular Cell Tumor (GCT) has variously been referred to as Abrikossoff's tumor, granular cell myoblastoma, granular cell neuroma, granular cell neurofibroma or granular cell schwannoma. It is a soft tissue neoplasm of neural origin that is distinct from neurofibromas, schwannomas or muscle tumors [10,11]. Scrotal

GCT was first reported in literature by Ha and associates [12] in 1994 and since then this is the twelfth case being reported and the first in Africa (Table 1). Previous reports indicate all patients to have presented with painless nodules [11-13], with one case reported to have been ulcerated at presentation [14]. Nodule was noticed to have been present in various cases for periods ranging from 3 weeks to 35 years with no malignant case recorded so far.

Case	Age (years)	Number of Tumors	Duration before presentation	Size (cm)	Presentation	Treatment	Recurrence
Ha, et al. [12]	40	1	N/A	5	Nodule	Excision	N/A
Bryant [15]	36	1	1 year	0.4	Nodule	Excision	Nil at 6 months
Altman, et al. [16]	55	2	N/A	0.7, 1.1	Nodule	Excision	Nil at 22 months
Medina Perez (1999) [14]	19	1	Months	2	Skin ulcer	Excision	Nil at 24 months
Mendelez Lopez, et al. [17]	38	1	2 years	1	Nodule	Excision	N/A
Craig, et al. [4]	67	1	2 years	1.6	Nodule	Biopsy/Excision	N/A
Godoy, et al. [1]	57	1	35 years	1.5	Nodule	Biopsy/Excision	Nil at 6 months
Sidwell, et al. [2]	6	1	Few months	0.5	Nodule	Excision	N/A
Chen, et al. [10]	89	1	3 weeks	1.5	Nodule	Excision	N/A
Richmond, et al. [13]	15	1	3-4 years	1	Nodule	Excision	Nil at 1 month
Djenic [11]	17	1	Over 10 years	2	Nodule	Excision	N/A
Current case	31	1	5 months	0.6	Nodule	Excision	Nil at 12 months
N/A – Information not available							

Table 1: Summary of scrotal granular cell tumors reported so far in literature. (Adapted from the work by Chen and colleagues [10])

It is essential that GCTs be confirmed with S-100 staining which is noted to be positive in all cases [17]. Positive staining with antiserum to S - 100 indicates that granular cell myoblastomas are of neural origin arising from Schwann cells [18]. Vimentin (fibroblast intermediate filament) which is the major intermediate filament found in non-muscle cells like fibroblasts and Schwann cells is also known to be expressed by GCTs [19,20]. Immunohistochemistry confirmed both in our current case. GCTs have been noted to be more common in blacks generally [10,21] with two-thirds of cases being reported in blacks [22]. However, aside the explicit mention of the patient with scrotal GCT being black in the reports by Craig [4] and Altman [16], this is the third mention of scrotal GCT in a black man and the first mention in a native African from Nigeria, which has the largest population of indigenous black men worldwide. Unanswered questions therefore include; do scrotal GCTs differ from GCTs found in other regions of the body, being less common in blacks or is it a case of the tumors being missed? Benign scrotal GCTs are noted to be small sized, very slow growing tumors which are frequently solitary and hardly presenting with other symptoms. There is thus a high likelihood that patients do not consider them a problem worth reporting. There therefore has to be a high index of suspicion for these tumors to be diagnosed, and especially so because of the small percentage of GCTs that are malignant. However, till date, no malignant case of

scrotal GCT has been recorded. Generally, between 1-2% of cases of GCTs are reported to be malignant [23]. Recurrence rates of benign GCTs range between 2 and 8 %, even when the resection margins show no evidence of tumor; and rise to 20% and above when the surgical margins are positive for tumor [24]. Reported cases of scrotal GCTs have been followed up for variable periods ranging from 1-24 months with no evidence of recurrence. Our own patient has not shown any evidence of recurrence 12 months post operatively.

Conclusion

Scrotal granular cell tumors are very rare. Benign disease is rarely associated with symptoms making it possible for the disease to be missed easily. Diagnosis therefore requires a high index of suspicion. The potential for it to be malignant makes it imperative for there to be histologic diagnosis. Complete excision with tumor free margins is the standard of treatment to reduce chances of recurrence.

References

1. Godoy G, Mufarrij P, Tsou H, Torre P, Taneja S (2008) Granular cell tumor of scrotum: a rare tumor of the male external genitalia. *Urology* 72: 716.e7-716.e9.

2. Sidwell RU, Rouse P, Owen RA, Green JS (2008) Granular Cell Tumor of the Scrotum in a Child with Noonan Syndrome. *Pediatr Derm* 25: 341-343.
3. Bishop H, Wagner B (1957) Granular cell myoblastoma in childhood; report of an unusual case. *Pediatrics* 19: 858-862.
4. Craig E, Rodriguez R, Ruben B (2005) Granular cell tumour of the scrotum. *Dermatol Online J* 11: 25.
5. Simsir A, Osborne BM, Greenebaum E (1996) Malignant granular cell tumor: a case report and review of the recent literature. *Hum Pathol* 27: 853-858.
6. Aksoy S, Abali H, Kilickap S, Harputluoglu H, Erman M (2006) Metastatic granular cell tumor: a case report and review of the literature. *Acta Oncol (Madr)* 45: 91-94.
7. Berg J, Tewari K, Del Rosario R, Berman M (2003) Unusual presentation of a malignant granular cell tumor of the pelvis: case report and literature review. *Gynecol Oncol* 90: 224-230.
8. Imam M, Solomon R, Yusuf I (2016) Benign tumors of the breast in Kano, Northern Nigeria: A 10-year experience and review of literature. *Sahel Med J* 19: 137-141.
9. Aniebue U, Olusina B (2009) Granular Cell Tumor - a Rare Tumor of the Mons Pubis: Case Report and Literature Review. *Trop J Obs Gynaecol* 26: 184-186.
10. Chen K-H, Shang H-S, Lin H-C, Lee H-S, Gao H-W (2013) Granular cell tumor of the scrotum: A case report and literature review. *Indian J Pathol Microbiol* 56: 161-162.
11. Djenic B (2017) Scrotal Granular Cell Tumor: A Case Report. *Open Access J Surg* 4: 1-2.
12. Ha CW, Cho KJ, An HJ, Jang JJ (1994) Granular cell tumor of the scrotum -A case report. *J Korean Cancer Assoc.* 26: 176-179.
13. Richmond AM, La Rosa FG, Said S (2016) Granular cell tumor presenting in the scrotum of a pediatric patient: A case report and review of the literature. *J Med Case Rep* 10: 4-7.
14. Medina Perez M, Valpuesta Fernandez I, Valero Puerta J, Perez Martin D (1999) Granular cell tumor of the scrotum with high pseudoepitheliomatous hyperplasia. *Arch Esp Urol* 52: 169-170.
15. Bryant J (1995) Granular cell tumor of penis and scrotum. *Urology* 45: 332-334.
16. Altman C, Hamill R, Pujals J (1999) Multiple cutaneous granular cell tumors of the scrotum. *Cutis.* 63: 77-80.
17. Mendelez Lopez V, Osman Agha G, Lopez Almansa M, Funez Liebana R, Garcia Gonzalez E (2001) Unusual location of granulosa cell tumor. *Arch Esp Urol* 54: 374-375.
18. Stephanson K, Wollmann RL (1982) S-100 protein in granular cell tumors. (Granular cell myoblastomas). *Cancer* 49:1834-1838.
19. Robinson-Bennett B, Han A (2006) Role of Immunohistochemistry in elucidating lung cancer metastatic to the ovary from primary ovarian carcinoma. In: Hayat M (Ed) *Handbook of Immunohistochemistry and in Situ Hybridization of Human Carcinomas*. Pp: 537-545.
20. Mazur M, Shultz J, Myers J (1990) Granular cell tumor. Immunohistochemical analysis of 21 benign tumors and one malignant tumor. *Arch Pathol Lab Med* 114: 692-696.
21. Bitar M, Al Afif KA, Fatani MI (2011) Granular cell tumor: Case report. *J Saudi Soc Dermatology Dermatologic Surg* 15: 25-27.
22. Peters J, Crowe M (1998) Granular cell tumor of the toe. *Cutis* 62: 147-148.
23. Fanburg-Smith J, Meis-Kindblom J, Fante R, Kindblom L (1998) Malignant granular cell tumor of soft tissue: diagnostic criteria and clinicopathologic correlation. *Am J Surg Pathol* 22: 779-794.
24. Yasak T, Özkaya Ö, Akçay AA, Kayadibi T, Erzurumluoğlu N (2016) Report of two cases of granular cell tumor, a rare tumor in children. *J Pediatr Surg Case Reports* 14: 1-3.