

Clinical & Experimental Dermatology and Therapies

Yang MY, et al. Clin Exp Dermatol Ther: CEDT-149.

DOI: 10.29011/2575-8268/100049

Research Article

Braids or Pony-tail-associated Traction Alopecia in Female Children

Min-Young Yang^{1,2,4#}, Hoon-Soo Kim^{1,2,4#}, Gun-Wook Kim^{1,2}, Hyun-Chang Ko^{1,3}, Byung-Soo Kim^{1,2}, Moon-Bum Kim^{1,2,4*}¹Department of Dermatology, College of Medicine, Pusan National University, Busan, Korea²Department of Dermatology, Pusan National University Hospital, Busan, Korea³Department of Dermatology, Pusan National University Yangsan Hospital, Yangsan, Korea⁴Biomedical Research Institute, Pusan National University Hospital, Busan, Korea

#Contributed equally to this work.

*Corresponding author: Moon-Bum Kim, Department of Dermatology, College of Medicine, Pusan National University, 179, Gudeok-ro, Ami-dong 1(il)-ga, Seo-gu, Busan, Postal code 49241, Korea. Tel: +82512407338; Fax: +82512459467; Email: drkmp@hanmail.net

Citation: Yang MY, Kim HS, Kim GW, Ko HC, Kim BS, et al. (2018) Braids or Pony-tail-associated Traction Alopecia in Female Children. Clin Exp Dermatol Ther: CEDT-149. DOI: 10.29011/2575-8268/100049**Received Date:** 04 June, 2018; **Accepted Date:** 09 June, 2018; **Published Date:** 16 June, 2018

Abstract

Backgrounds: Traction Alopecia (TA) is a type of traumatic hair loss caused by prolonged tension on the scalp hair. And it is not sparse to see TA in girl children with their hairs braided or pony-tailed in Korea. This Braids or Pony-tail-associated Traction Alopecia (BPTA) could be difficult to differentiate from early Alopecia Areata (AA).

Objectives: We intended to propose a new subtype of TA, that is BPTA, and to suggest the diagnostic flow chart for BPTA based on its characteristic clinical and dermoscopic findings through the present study.

Methods: We investigated the clinical features and dermoscopic findings of BPTA in 24 patients. Dermoscopic findings of alopecia areata (AA) in 65 patients were also investigated to compare with.

Results: The mean age of 24 girls was 5.92 year-old. BPTA showed clinical features such as lesional location being predominant near the parting lines of the scalp (83.87%), short duration of disease (1.2 months), quite a few lesions (1.48 lesions), small size of patch and spontaneous regrowth (1.5 months) after causative hairstyle change. In dermoscopic findings, black dots (p-value < 0.001), broken hairs (p-value < 0.001) and split end of broken hair shaft (p-value < 0.001) got to the features of BPTA, and tapering hairs (p-value < 0.001) and yellow dots (p-value < 0.001) were the characteristics of AA.

Conclusions: In the cases of small hairless patches in girl, our proposal for BPTA and its diagnostic flow chart could be very useful for dermatologists, especially who are dealing hair disorders.

Keywords: Alopecia areata; Braids; Dermoscopy; Female children; Pony-tail

Introduction

Traction Alopecia (TA) is a type of mechanical hair loss that is provoked by constant tension on the scalp [1]. The clinical manifestations of TA can be biphasic in nature. Initially, scalp hair

loss can be transient [2]. However, as the traction force continues over a long period, scarring alopecia can occur [2]. Thus, an early diagnosis and rapid intervention to stop the causative act are important [3].

Braided or pony-tailed hairstyles are common in young females due to its neatness. However, it can often result in hair loss that is associated with traction force. Furthermore, this pattern of hair

loss is clinically difficult to distinguish from early Alopecia Areata (AA). Therefore, our study sought to propose a new subtype of TA (i.e., “Braids or Pony tail-associated Traction Alopecia [BPTA]”) in female children to elucidate its clinical and dermoscopic characteristics and to suggest a diagnostic approach algorithm to distinguish BPTA from other types of alopecia, such as AA.

Methods

Study Population and Study Design

We investigated the clinical features and dermoscopic findings of 31 cases of BPTA in 24 patients who visited the alopecia clinic of our hospitals from August 2009 to August 2015. The clinical assessment included the age; sex of patients; the location, number, and size of the hairless patches; disease duration; onset of the disease; histories of treatment on the hairless patches at the local clinic; and the clinical course of the disease. As a dermoscopic control group, 81 small round or oval hairless patches in 65 AA patients were also investigated. Dermoscopic findings were assessed using the DermLite II pro® (3Gen, San Juan Capistrano, CA, USA), a uniform light device.

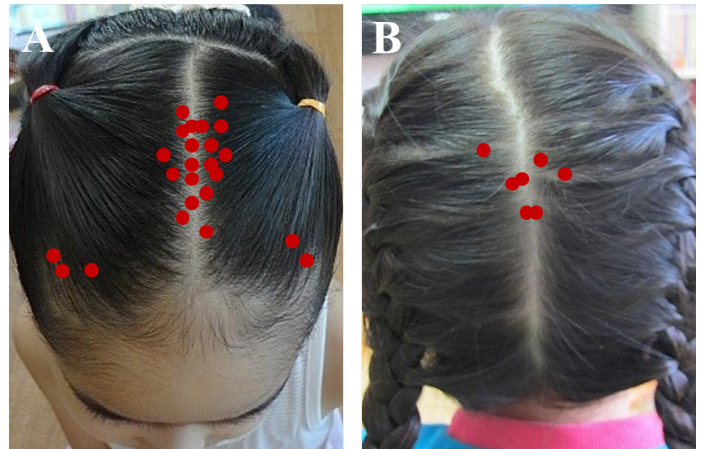
Statistical Analysis

All statistical analyses were performed using IBM Statistical Package for Social Sciences (IBM® SPSS® Statistics, IBM Corporation, NY, USA) version 21. We used Fisher’s exact test to compare dermoscopic findings between BPTA and early AA. P-values less than 0.05 were considered statistically significant.

Results

Clinical Features

All BPTA patients were female children with a mean age of 5.92 years. Regarding the site of hairless patches, 19 lesions (19/31, 61.29%) were located on the frontal and midscalp area of the scalp, seven lesions (7/31, 22.58%) were located on the occipital area and five hairless patches (5/31, 16.13%) were located on the temporal portion of the scalp (Figures 1,2). Overall, the location of the hairless patch was predominant near the parting lines of the scalp (26/31, 83.87%). The duration of the disease was short with a mean value of 1.2 months. The mean duration of the onset of the hairless patch after admission to kindergarten was 4.4 months. There were either one or two lesions per child, with the mean number of lesions being 1.48. The hairless patches were similar in size to their thumb nail plate and round to oval in shape in most patients. The clinical course showed spontaneous regrowth in all patients within 1.5 months of the mean value after changing the causative hairstyle. Moreover, 37.5% (9/24) of patients underwent treatment with triamcinolone intralesional injection or topical therapy, such as steroid and minoxidil, under misdiagnosis of AA at the local clinic before visiting our department.



Figures 1(A-B): Braids or pony-tail associated traction alopecia. Typical symmetrical braided hairstyle parted in midline in Korean girls: (A) Vertical view, (B) Posterior view, and red dots (each lesion of braids or ponytail-associated traction alopecia [BPTA]) showing the distribution of 31 lesions of BPTA.

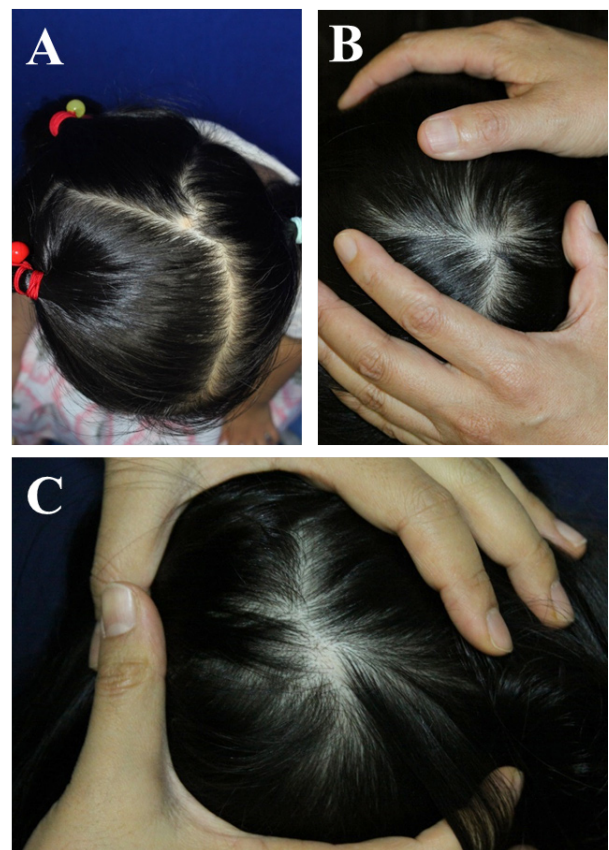

Figure 2: Braids or pony-tail associated traction alopecia. Clinical features of braids or ponytail-associated traction alopecia (BPTA) in girl children: (A) 3-year-old girl, (B) 5-year-old girl, and (C) 4-year-old girl.

Dermoscopic Findings

In BPTA, black dots were the most common finding and occurred in 83.87% (26/31) lesions. This was followed by broken hairs (22/31, 70.97%) and clustered short vellus hairs (9/31, 29.03%). Split ends of the broken hair shaft, pigment network and yellow dots were observed in seven (7/31, 22.58%), three (3/31, 9.68%) and three (3/31, 9.68%) patients, respectively (Figure 3). Nevertheless, tapering hair was not observed in all lesions.

In AA, the most common finding was yellow dots (50/81, 61.73%), followed by clustered short vellus hairs (39/81, 48.15%), black dots (34/81, 41.98%), tapering hairs (32/81, 39.51%), broken hairs (26/81, 32.10%) and pigment network (7/81, 8.64%) (Figure 3). Split ends were not found in all lesions.

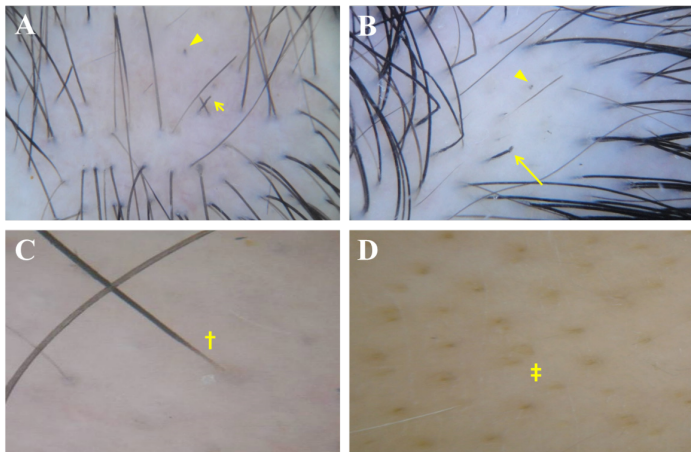


Figure 3: Braids or Ponytail-Associated Traction Alopecia (BPTA) and Alopecia Areata (AA). Dermoscopic findings of BPTA and AA: (A) broken hair (short arrow) and black dot (arrow head) in a 4-year-old girl with BPTA, (B) split end of broken hair shaft (long arrow) and black dot (arrow head) in a 7-year-old girl with BPTA, (C) tapering hair (cross) in a 7-year-old girl with AA, and (D) yellow dot (double cross) in a 5-year-old girl with AA.

Statistical analysis indicated that black dots (p-value < 0.001), broken hairs (p-value < 0.001) and split ends (p-value < 0.001) were the main features of BPTA, while tapering hairs (p-value < 0.001) and yellow dots (p-value < 0.001) were the characteristics of AA (Figure 4, Table 1).

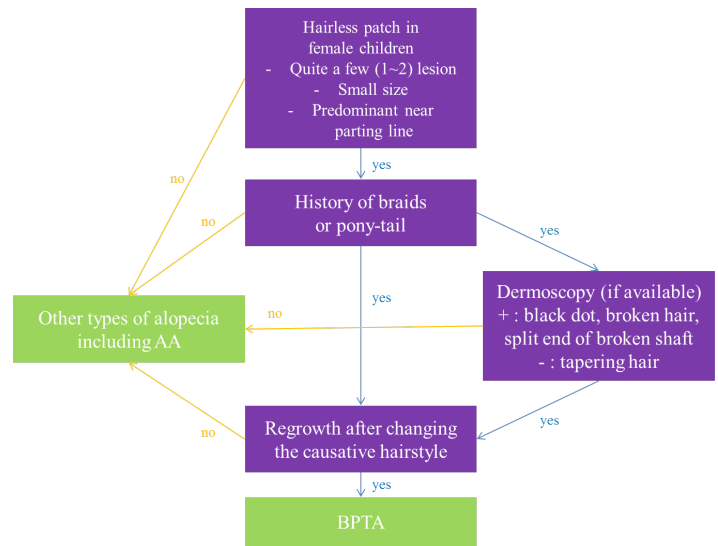


Figure 4: Braids or pony-tail associated traction alopecia. Diagnostic algorithm for braids or pony-tail associated traction alopecia.

Dermoscopic findings	BPTA (n=31)	AA (n=81)	P-value†
Black dots (%)	26 (83.87)	34 (41.98)	<0.001
Broken hairs (%)	22 (70.97)	26 (32.10)	<0.001
Split end of broken hair shaft (%)	7 (22.58)	0 (0.00)	<0.001
Clustered short vellus hairs (%)	9 (29.03)	39 (48.15)	0.088
Pigment network (%)	3 (9.68)	7 (8.64)	0.663
Tapering hairs (%)	0 (0.00)	32 (39.51)	<0.001
Yellow dots (%)	3 (9.68)	50 (61.73)	<0.001

† Fisher's exact test was used to compare dermoscopic findings between two groups, and P-values less than 0.05 were considered statistically significant.

Table 1: Comparison of dermoscopic findings between braids or pony tail-associated traction alopecia (BPTA) and alopecia areata (AA).

Discussion

TA is a type of artifactual hair loss caused by sustained pulling forces on the hair roots [1]. Various clinical manifestations can occur, such as reduced hair density, focal hairless patch and folliculitis [2]. There are no specific symptoms that accompany the condition, but headache is often associated with its manifestation, which is subsequently relieved when the pulling hair is loosened [4]. The early phase of TA is reversible if the causative factor can be halted [2]. However, as the mechanical insult continues for a long period, scarring alopecia can occur [5]. Thus, early diagnosis and rapid intervention are imperative [3].

In Korea, braided or pony-tail hairstyle is popular in female children, particularly after admission to kindergarten (Figures 1A-B). This may be because their mothers or grandmothers prefer these hairstyles due to their tidiness. However, it can also induce TA due to sustained pulling forces. Clinically, this pattern of hair loss might be difficult to distinguish from early AA. Therefore, we performed this study to determine the clinical and dermoscopic characteristics of BPTA, and finally to assist in developing a differential diagnosis of BPTA from AA.

In our study, most lesions of BPTA were located in the central part of the scalp, particularly near parting lines. We speculated that BPTA mostly occurred near parting lines because hair is parted along the midline with an exact proportion of five to five in Korean braided or pony-tail hairstyles (Figures 1A-B). Additionally, the tension on hair near the parting lines is greatest since it contributes to the neatness of braided or pony-tail hairstyles. This is in contrast with TA caused by hairstyles among Afro-Caribbean women, where hairless patches occur most frequently in the temporal area because of an elevated level of tension on the marginal area of the scalp because of the nature of the characteristic African female hairstyle [6]. The number of alopecic lesions in patients was one or two, with the mean being 1.48. The hairless patch was also found to be similar in size to the thumb nail plate of the patients. Considering these clinical characteristics, diagnosing BPTA is not difficult. However, 37.5% of patients were misdiagnosed and treated with AA at their local clinic before visiting our department. To identify additional differential diagnostic characteristics, we looked over the dermoscopic characteristics of BPTA and compared them with those of AA with small round or oval hairless patches.

In dermoscopic findings of BPTA, black dots, broken hairs and split ends of broken hair shafts were observed with statistical significance compared with AA. Tapering hairs and yellow dots were dermoscopic features of AA in our study, which is similar to previous reports [7]. The present dermoscopic findings of BPTA are considered to be partially consistent with those of a previous study of TA [8]. In particular, black dots upon dermoscopic investigation are regarded as a sign of broken hairs [9]. Growing hair shafts (i.e., during the anagen phase) that is broken by traction force

manifests itself as broken hairs [8]. Characteristically, split ends of broken hair shafts, which are reported in the dermoscopic findings of trichotillomania, were observed in this study in patients with BPTA. But, BPTA could be differentiated from trichotillomania clinically in the aspect of round to oval in shape, central part of the scalp in lesion location and the absence of concurrent manifestation other than alopecia such as onychophagia. Split ends of broken hair shafts upon dermoscopic investigation generally intimates irregular and repetitive pulling of hair, thereby resulting in cumulative damage to the shaft [10]. Repetitive and persistent tension on the cuticle that is induced by braids or the ponytail hairstyle may have contributed to the genesis of the split ends of broken hair observed in the present study.

When encountering focal hairless patches in female children, it is important to discern the history of use of braids or the pony-tail hair style if there are lesions on the parting lines of the scalp that are one to two lesions that are small in size and that persist for a relatively short duration. This will allow for the identification of BPTA. In ambiguous cases, dermoscopy might help in differentiating BPTA from other types of alopecia, particularly early AA. If black dots, broken hairs and split ends of broken shafts are found upon dermoscopy, the diagnostic possibility of BPTA increases. If the patient's clinical and dermoscopic findings correspond to BPTA, physicians can observe spontaneous regrowth after changing the causative hair style in approximately 2-3 months to confirm the diagnosis of BPTA.

Conclusively, we propose a new subtype of traction alopecia in female children, "braids or pony-tail-associated traction alopecia." Furthermore, our diagnostic algorithm, which considers the clinical manifestation, dermoscopic examination, and regrowth after changing the causative hairstyle, can help in distinguishing BPTA from other types of alopecia, including early AA. (Figure 4).

Funding Sources: None.

Conflict of Interest Disclosure: None Declared.

IRB approval was acquired from the institutional review board of the hospital (H-1701-002-051).

References

1. Samrao A, Chen C, Zedek D, Price VH (2010) Traction alopecia in a ballerina: clinicopathologic features. *Arch Dermatol* 146: 930-931.
2. Hantash BM, Schwartz RA (2003) Traction alopecia in children. *Cutis* 71: 18-20.
3. Haskin A, Aguh C (2016) All hairstyles are not created equal: What the dermatologist needs to know about black hairstyling practices and the risk of traction alopecia (TA). *J Am Acad Dermatol* 75: 606-611.
4. Blau JN (2004) Ponytail headache: a pure extracranial headache. *Headache* 44: 411-413.

5. Ozcelik D (2005) Extensive traction alopecia attributable to ponytail hairstyle and its treatment with hair transplantation. *Aesthetic Plast Surg* 29: 325-327.
6. Khumalo NP, Jessop S, Gumede F, Ehrlich R (2008) Determinants of marginal traction alopecia in African girls and women. *J Am Acad Dermatol* 59: 432-438.
7. Inui S, Nakajima T, Nakagawa K, Itami S (2008) Clinical significance of dermoscopy in alopecia areata: analysis of 300 cases. *Int J Dermatol* 47: 688-693.
8. Jain N, Doshi B, Khopkar U (2013) Trichoscopy in alopecias: diagnosis simplified. *Int J Trichology* 5: 170-178.
9. Rudnicka L, Olszewska M, Rakowska A, Slowinska M (2011) Trichoscopy update 2011. *J Dermatol Case Rep* 5: 82-88.
10. Ankad BS, Naidu MV, Beergouder SL, Sujana L (2014) Trichoscopy in trichotillomania: a useful diagnostic tool. *Int J Trichology* 6: 160-163.