

## Case Report

# Ophthalmoplegic Migraine: A Single Dose of Prednisolone at the onset Can Shorten the Duration of Headache and Prevent the Ophthalmoplegia

Ayako Senju, Masayuki Shimono\*, Masahiro Ishii, Tomofumi Fukuda, Ryota Igarashi, Koich Kusuhara

Department of Pediatrics, University of Occupational and Environmental Health Faculty of Medicine

**\*Corresponding author:** Masayuki Shimono, Department of Pediatrics, University of Occupational and Environmental Health Faculty of Medicine, 1-1 Iseigaoka, Yahata-nishi-ku, Kitakyushu 807-8555, Japan, Tel: +81-93-691-7254, Fax: +81-93-691-9338 E-mail: shimono@med.uoeh-u.ac.jp

**Citation:** Senju A, Shimono M, Ishii M, Fukud T, Igarashi R, et al. (2017) Ophthalmoplegic Migraine: A Single Dose of Prednisolone at the onset Can Shorten the Duration of Headache and Prevent the Ophthalmoplegia. Ann Case Rep 2017: J138. DOI: 10.29011/2574-7754/100038

**Received Date:** 20 January, 2017; **Accepted Date:** 24 January, 2017; **Published Date:** 30 January, 2017

## Abstract

We report on a 14-year-old boy with ophthalmoplegic migraine (OM). He suffered from ptosis and movement dysfunction of the right eye when he was 1 year 8 months and 3 years 11 months. In both incidences, his ptosis improved spontaneously in a few day, and eye movement dysfunction after two months. At 4 years 3 months, he had a severe headache preceding right oculomotor palsy. Brain MRI showed swelling and gadolinium enhancement in the cisternal segment of his right oculomotor nerve. We diagnosed him as OM, and prescribed oral prednisolone (PSL). On his 8th attack at the age of 6, we began administering the oral PSL immediately after the onset of the headache. That resulted in no ptosis and ophthalmoplegia after slight headache. Now he is 14 years old, a single dose of PSL has been enough to shorten the duration of his headaches and prevent any eye movement disorder.

**Keywords:** Headache; eye movement disorder; Gadolinium enhancement MRI; Steroid

## Introduction

Ophthalmoplegic migraines (OM) is a rare disorder. It is characterized by cranial nerve dysfunction of the oculomotor, abducens or trochlear nerve following severe headaches in childhood. This condition is considered in the category of neuralgia or neuropathy [1-4] whose etiology is inflammatory, vascular, tumorous or infectious in nature [4,5]. If an MRI scan discovers swelling and gadolinium enhancement in the cisternal segments of any of the oculomotor, abducens or trochlear nerve in a patient suffering from severe headaches followed by ophthalmoplegia, we diagnose that patient with OM [6,7].

Preventing OM attacks is important, as there are reports suggesting that recurrent episodes can increase in severity, with permanent neurological sequelae arising in up to 30% of patients [4]. Some papers suggest that  $\beta$ -blockers, calcium channel blockers, or


cycloheptadine hydrochloride is effective for preventing attacks [3]. OM attacks occur rarely, thus administering medicine daily to children is sometimes difficult. Other papers discuss how steroid therapy in the early phases of the disease shortened the duration of eye movement disorder [4,8,9]. Yet there were a minority of controversial reports casting doubt on the beneficial effect of steroids [10].

Since OM is a rare disorder, double blind studies are extremely difficult. Therefore, the results of repeated treatment for the same patient with different medicines and timing are important for understanding effective therapy choices. In this article, we present a case where a single-dose treatment of oral prednisolone (PSL) immediately at the onset of headaches can shorten their duration and prevent ptosis and ophthalmoplegia.

## Case Report

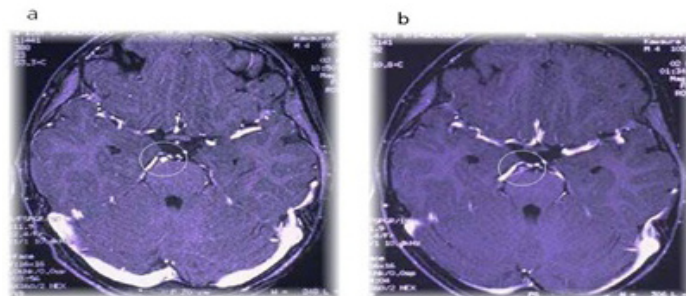
The male patient suffered from right ptosis and eye movement dysfunction without apparent irritability, vomiting or pallor

in two separate instances: when he was 1 year 8 months, and 3 years 11 months old. The ptosis improved spontaneously in a few day, as did eye movement dysfunction within two months. On one occasion when he was 4 years and 3 months old, he suffered from severe headaches with vomiting on day 1, which lasted to day 3. Oculomotor dysfunction set in on day 4. He was admitted to our hospital to have his right oculomotor dysfunction examined on day 7. His first physical examination revealed ptosis, lateral deviation and an inability for adduction in his right eye (Figure 1). His pupils were isocoric, and the bilateral light reflex was prompt. We diagnosed him as suffering from right oculomotor palsy. We performed a contrast enhanced brain MRI and the results showed swelling and gadolinium enhancement of the cisternal segment of the right oculomotor nerve (Figure 2a). No other abnormal lesion was detected. The cerebrospinal fluid examination showed that his white blood cell count was 4/mm<sup>3</sup>, the protein level was 9 mg/mL and his glucose level was 73 mg/mL. Peripheral blood cell count, biochemistry, ESR (9 mm/hr) and urinalysis, anti-acetylcholine receptor antibody level (<0.3 pmol/mL), and the tensilon test results were within the normal limits. Based on these data, we diagnosed the patient as suffering from ophthalmoplegic migraine (OM) [3,7]. Oral prednisolone (1.6mg/kg/day: 20mg/day) was started on day 8 and continued until day 14 (1 week), which was tapered and stopped at day 21 (1 week). The ptosis was completely resolved in a few day and the oculomotor nerve palsy within 2 months. We performed a follow-up MRI 2 months later, which showed reduced swelling and gadolinium enhancement of the right oculomotor nerve (Figure 2-b).



**Figure 1:** When he was 4 years and 3 months old, we observe ptosis, lateral deviation and inability to adduct on his right eye. We diagnosed him as suffering from right oculomotor palsy.

**Figure 2**



**Figure 2(a, b):** Swelling and gadolinium enhancement in cisternal segment of the right oculomotor nerve is shown (2a). Two months later, MRI shows that the swelling and enhancement is reduced (2b).

The 4th attack occurred during his first herpes simplex virus infection at the age of 5 years and 3 months. Abrupt fever and headaches started on day 1 of this attack, and the ptosis and oculomotor palsy of the right eye set in on day 4. Along with intravenous acyclovir, intravenous hydrocortisone (10mg/kg/day) was used from day 4 to day 9, then tapered and stopped at day 19. The patient's ptosis was resolved on day 9, and the oculomotor nerve palsy improved within 3 weeks.

After his 4th attack, he suffered from OM once every few months. Therefore, we started cyproheptadine hydrochloride (0.25mg/kg/day) as a prophylactic drug [4,8]. He suffered 3 more OM attacks, however, within the first 8 months of the prophylactic regimen.

When he was 6 years old, he could distinguish an OM headache from usual headaches. Thus we recommended to his parents to administer his PSL dose immediately after he suffered an OM headache. That resulted in quick headache resolution without vomiting, ptosis and oculomotor palsy. We thereafter changed his oral PSL protocol to follow a one-week regimen; for 3 days PSL was administered (1.0 mg/ kg/day) immediately after he felt an OM headache, then tapered it off over the following 4 days. It seemed that the interval between OM attacks gradually increased after changing to this protocol. He failed to take his oral PSL once, when he and his family went out without it. On that occasion, he was unable to take his PSL until 2 to 3 hours after the beginning of the OM headache. This delay might result in a reoccurrence of ptosis and lateral deviation in his right eye after a few day. As a result of this episode, we insisted that he started his PSL as soon as he felt a sign of OM headache.

He is now 14 years old and has experienced OM headache without any oculomotor palsy, about once or twice a year. The pa-

tient recently discovered that only the single dose of the seven-day regimen was enough to stop any OM headache and oculomotor dysfunction, because he sometimes forgot to take the second or third dose. He now uses only a single dose of oral PSL (20mg/dose; 0.5mg/kg/day), still without any ptosis and eye movement dysfunction if he can use the PSL when he felt a sign of OM headache.

## Discussion

Ophthalmoplegic migraine (OM) is a rare condition, characterized by recurrent eye movement disorder following migraine headaches in childhood [2,3,7,8]. Our patient's MRI showed swelling and enhancement of the cisternal segment of the right oculomotor nerve [2,3,7,4]. Thus, we diagnosed him as suffering from OM.

Optimal medicine and duration of the therapy for headaches and eye movement disorder is still unclear for OM. Some papers report that steroid immediately after headaches was effective in shortening the duration of ptosis and oculomotor palsy [4,10]. Therefore, after his 8th attack at age 6, we insisted the parents try PSL immediately after their son felt a migraine headache for one week regimen. As a result, headaches were resolved quickly within a few hours without any ptosis or oculomotor palsy. From his response to the treatment, we surmise that PSL can prevent ophthalmoplegia if it is administered at the earliest sign of OM. If the PSL is taken with a delay of 2 or 3 hours after the onset of the migraine headache, it proved less effective and did not prevent eye movement disorder. Our case suggests that PSL at the earliest sign of the migraine headache for OM patient, it can prevent ophthalmoplegia [9].

Why is it so important for the patient to take the drug early? Previous papers suggested that OM may be neuralgia or neuropathy which is inflammatory, vascular, tumorous or infectious in etiology [5,2,4,8]. In case the patients respond to steroids, the earlier we start to treat the neuropathy, the easier we can suppress the secondary reactions it causes. In a sense, early recovery from this condition also affects the long term outcome. This explains why the inter OM attack interval becomes longer and we could decrease the PSL dosage for our patient. We strongly believe that quick and complete suppression of each attack with steroids treatment immediately after headache onset could lead to the fulfillment of therapy for OM. That is, if we start the treatment, it weakens the severity of headache and prevents the eye movement disorder. We suppose that the method is better for children to take daily prophylactic drug in case they respond to steroids. However, we do not know of any other case where a single dosage of PSL prevented ophthalmoplegia. Further study is necessary to test the efficacy of PSL use immediately after the onset of migraine headaches.

On this article announcement, we explained it to a patient and his parents and acquired informed consent.

## References

1. Carlow TJ (2002) Oculomotor Ophthalmoplegic Migraine: Is It Really Migraine? *J Neuro-Ophthalmol* 22: 215-221.
2. Lance JW, Zagami AS (2001) Ophthalmoplegic migraine: a recurrent demyelinating neuropathy? *Cephalalgia* 21: 84-89.
3. Levin M, Ward T N (2004) Ophthalmoplegic Migraine. *Curr Pain Headache Rep* 8: 306-9.
4. McMillan HJ, Keene DL, Jacob P, Humphreys P (2007) Ophthalmoplegic Migraine: Inflammatory Neuropathy with Secondary Migraine? *Can J Neurol Sci* 34: 349-355.
5. Akinoto J, Fukami S, Hashimoto R, Haraoka J (2012) Neuromuscular hamartoma is a possible primary pathology of oculomotor ophthalmoplegic migraine. *Cephalalgia* 32: 171-174.
6. Lee TG, Choi WS, Chung KC (2002) Ophthalmoplegic Migraine with Reversible Enhancement of Intraparenchymal Abducens Nerve on MRI. *Headache* 42:140-141.
7. Mark AS, Casselman J, Brown D, Sanchez J, Kolsky M, et al. (1998) Ophthalmoplegic Migraine: Reversible Enhancement and Thickening of the Cisternal Segment of the Oculomotor Nerve on Contrast-Enhanced MR Images. *Am J Neuroradiol* 19: 1887-1891.
8. Østergaard JR, Møller HU, Christensen T (1996) Recurrent ophthalmoplegia in childhood: diagnostic and etiologic considerations. *Cephalalgia* 6: 276-9.
9. Smith CD, Reeves AG (1986) Amelioration of ophthalmoplegic migraine by prednisone: a case report. *Headache* 26: 93-94.
10. Pareja JA, Churrua J, de la Casa Fages B, de Sikanes CL, Sánchez C, et al. (2010) Ophthalmoplegic mmigraine. Two patients with an absolute response to indomethacin. *Cephalalgia* 30: 757-760.