

Intrahepatic Bile Duct Cyst Calculus and Gallbladder Stones Treated with Surgery: A Case Report

Koichi Kimura^{1,2*}, Yasuhiro Doi¹, Yasushi Takii¹, Ryosuke Tsutsumi¹, Kensuke Kudou², Norifumi Tsutsumi¹, Tetsuo Ikeda², Soichiro Maekawa¹

¹Munakata Medical Association Hospital, Munakatashi, Fukuoka, Japan

²Department of Endoscopy and Endoscopic Surgery, Fukuoka Dental College, Fukuokashi, Fukuoka, Japan

***Corresponding author:** Koichi Kimura, Department of Endoscopy and Endoscopic Surgery, Fukuoka Dental College Fukuokashi, Fukuoka 814-0193, Japan. Tel: +81928010411; +819059210778; Fax: +81928013678; Email: cubicseal@gmail.com

Citation: Kimura K, Doi Y, Takii Y, Tsutsumi R, Kudou K, et al. (2018) Intrahepatic Bile Duct Cyst Calculus and Gallbladder Stones Treated with Surgery: A Case Report. Ann Case Rep: ACRT-189. DOI: 10.29011/2574-7754/100089

Received Date: 30 June, 2018; **Accepted Date:** 06 July, 2018; **Published Date:** 13 July, 2018

Abstract

Background: Intrahepatic bile duct cyst calculus is an extremely rare case. We report a case of intrahepatic bile duct cyst calculus and gallbladder stones treated with surgery.

Case Presentation: A 76-year-old woman consulted our institution because of epigastric pain. Her blood chemistry results showed elevation of hepatic-cystic system enzymes. Computed tomography revealed cholecystitis with gallbladder stones and stones within an intrahepatic bile duct cyst at the root of the right hepatic duct, which was suspected as a sub-gallbladder. Endoscopic retrograde cholangi pancreatography and other examinations were performed. Finally, the patient was diagnosed with double gall bladder stones and cholecystitis, and she underwent surgery. Intrahepatic bile duct cyst (considered as accessory gallbladder) and gallbladder resections and hepaticojunostomy were performed with laparotomy. She progressed well postoperatively and was discharged from the hospital on postoperative day 19. Postoperative histopathological examinations showed a definite diagnosis of intrahepatic bile duct cyst calculus and gall bladder stones with cholecystitis.

Conclusions: We report a case of intrahepatic bile duct cyst calculus and gallbladder stones treated with surgery. Decision of surgical procedure by the location of intrahepatic bile duct cysts is essential for the treatment.

Keywords: Gall bladders tone; Intrahepatic bile duct cyst calculus; Type V bile duct cyst

Introduction

Acute cholecystitis is the most frequent complication of cholelithiasis, accounting for up to 20% of patients with symptomatic gallstones [1]. Acute cholecystitis is one of the most frequent causes of urgent admission at surgical departments due to the high prevalence of cholelithiasis [2].

The Todani classification scheme is typically used to classify bile duct cysts based on their location and morphology [3]. Todani type V cysts are described as single or multiple intrahepatic cystic dilations with no extra hepatic involvement. Type V cysts are a rare form of bile duct cyst, and solitary type V cysts are even less common, with an estimated incidence of 1:1,000,000 [4]. Solitary

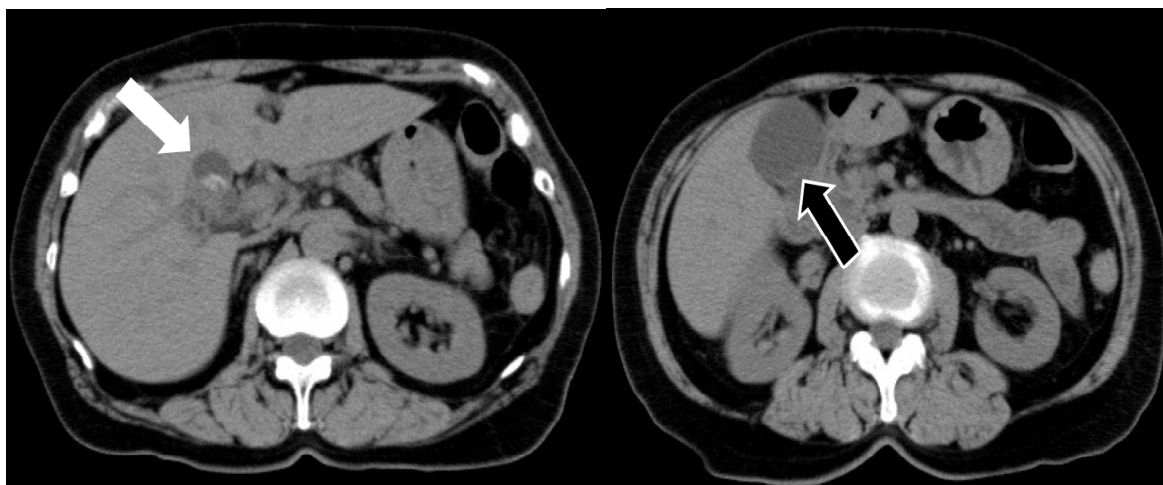diverticular type V cysts are exceedingly rare. Complications associated with bile duct cysts include bile ducts stricture, cholangitis, bile duct stones, pancreatitis, and biliary malignant changes. The risk of biliary malignancies increases with age [5]. Subsequently, bile duct cysts are surgically managed with complete cyst excision and hepaticojunostomy reconstruction or hepatectomy [6].

Here, we present a patient with solitary type V intrahepatic bile duct cyst with calculus and gallbladder stones treated with surgery.

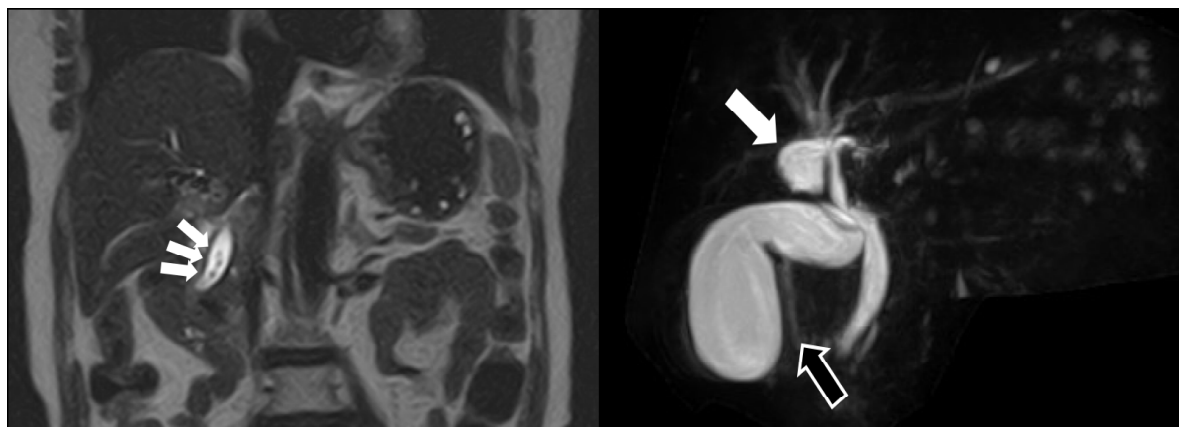
Case Presentation

The patient was a 76-year-old female with epigastric pain. Her blood chemistry study results showed elevation of hepatic-cystic system enzymes (aspartate aminotransferase : 193U/L, alanine aminotransferase : 238U/L, alkaline phosphatase :

826U/L, gamma-glutamyl transpeptidase : 559U/L, total bilirubin : 4.0mg/dL, Creactive protein : 3.93mg/dL). Computed tomography revealed gallbladder enlargement, gallbladder wall thickening with gallbladder stones, common bile duct expansion (8mm), common bile duct stones and stones with in an intrahepatic cyst at the root of right hepatic duct, suspected as an accessory gallbladder (Figures1A,B). Magnetic resonance cholangiopancreatography showed the same findings as computed tomography (Figures 2A,B). Subsequently, she was diagnosed with common bile duct stones, double gallbladder stones, and cholecystitis, and endoscopic retrograde cholangiopancreatography was performed. Cholangiopancreatography showed filling defects in the gallbladder, common bile duct, and intrahepatic cyst at the root of the right hepatic duct, which was suspected as an accessory gallbladder (Figure 3). Endoscopic sphincterotomy was performed for the common bile duct stones. No malfusion of the pancreaticobiliary ducts was observed. Two black stones were discharged from the common bile duct. One biliary stent was placed in to the common bile duct.



Figures1(A,B): Cystic structure (white arrow) (A) and normal gallbladder (black arrow) (B) are confirmed by computed tomography.



Figures 2(A,B): (A) Common bile duct stones (white arrows) are confirmed by magnetic resonance cholangiopancreatography. (B) Cystic structure (white arrow) and normal gallbladder (black arrow) are also confirmed by magnetic resonance cholangiopancreatography.

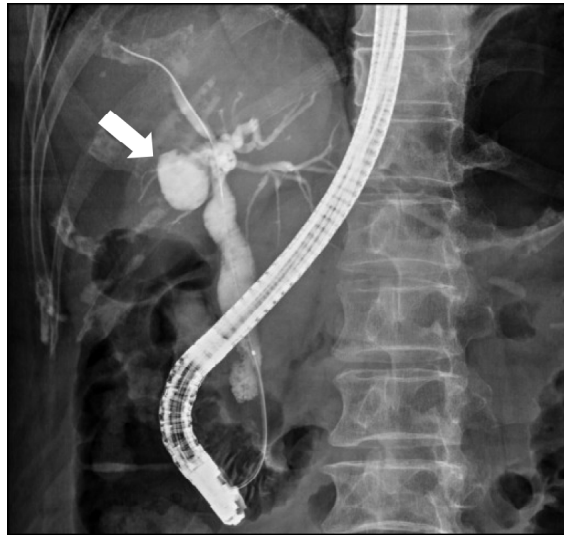
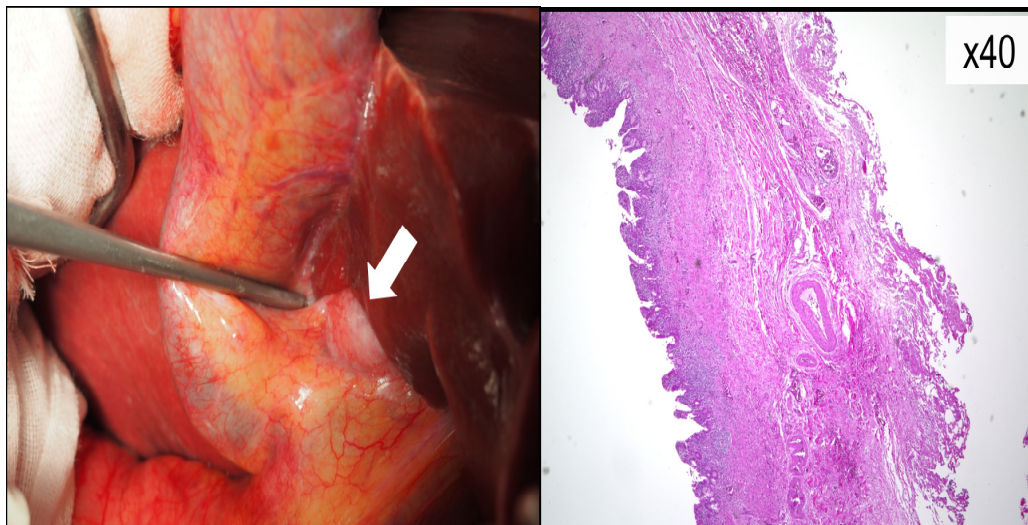


Figure 3: Cystic structure (white arrow) is confirmed by endoscopic retrograde cholangiopancreatography.

Finally, surgical procedure was performed for double gallbladder stones and cholecystitis. First, laparoscopic surgery has been planned; however, almost all the intrahepatic bile duct (considered as accessory gallbladder) existed in the liver parenchyma (Figure 4A). Subsequently, intrahepatic bile duct (considered as accessory gallbladder) and gallbladder resections and hepaticojejunostomy were performed with laparotomy. She progressed well postoperatively and was discharged from the hospital on postoperative day19. Postoperative histopathological examinations revealed no muscular layer in the wall of the intrahepatic cyst (considered as accessory gallbladder) (Figure 4B), and the definite diagnosis was intrahepatic bile duct cyst calculus and gallbladder stones with cholecystitis.



Figures 4(A,B): (A) Intraoperative image of the duct cyst during laparotomy (white arrow). Almost all intrahepatic bile ducts are in the liver parenchyma. (B) Microscopic image of the intrahepatic bile duct cyst. The muscular layer structure of the gallbladder could not be seen in the intrahepatic bile duct cyst.

Discussion

Bile duct cysts are rare worldwide, with an estimated incidence of 1 : 100,000-1:150,000 [7,8]. Early identification and treatment of bile duct cysts is recommended due to the potential for liver injury and malignant degeneration, presumably due to chronic cholestasis and cholangitis [9]. The risk of degeneration to cholangiocarcinoma is the highest for intrahepatic cysts [10]. The case reported here is exceptional because the intrahepatic cyst appears to be a single, diverticular lesion with no other apparent malformations of the biliary tree. To the best of our knowledge, only two previous cases of a solitary diverticular type V cyst have been reported in the literature [11,12].

In contrast, the preoperative diagnosis of this case was double gallbladder stones. Double gallbladder is a rare congenital anomaly, reported in 2 (0.02%) of 9921 autopsy cases and 3 (0.03%) of 9970 cases in a radiographic survey [13]. Gorecki et al. [14] reported a case of double gallbladder in a 69-year-old female with stones in both gallbladders with the accessory gallbladder originating from the left hepatic duct. In 2009, Kim et al. [15] have reported a 78-year-old male with duplicate gallbladder with stones arising from the left hepatic duct 10 years after an open cholecystectomy. However, postoperative histopathological examinations revealed no muscular layer in the wall of the intrahepatic cyst (considered as accessory gallbladder) in this case.

Complications associated with adult choledochal cysts include bile duct stricture, cholangitis, bile duct stones, pancreatitis, and biliary malignant changes. Biliary malignancy is the most important among these complications. The incidence of biliary malignancy in adult choledochal cysts is 9.8%-30%. The risk of biliary malignancies increases with age. Among 204 cases of adult choledochal cysts, Cho et al. [16] found that the incidence of biliary malignancies was 3.9% for the 18-30 years age group, 6.9% for the 31-40 years age group, 10% for the 41-50 years age group, 10.7% for the 51-60 years age group, and 37.5% for the 61-67 years age group. Possible carcinogenic factors included chronic inflammation, cholestasis, and sparse distribution of the protective mucin-secreting glands of the bile duct. Under the influence of these factors, chronic irritation, ulceration, regeneration, and metaplasia of the epithelium of the cystic wall may develop, and invasive carcinoma may eventually occur. The most common type of biliary cancer is adenocarcinoma; only few cases have been reported for undifferentiated carcinoma, squamous cell carcinoma, and adenosquamous carcinoma [5].

Aggressive treatment (total resection or transplantation) has been proposed to lower the risk of subsequent cholangiocarcinoma [4]. In the current case, considering the presence of the stones and the relative respectability of the cyst, the benefits of surgical resection have been decided to outweigh the potential risks. However, this

case is solitary intrahepatic bile duct, and the cyst is partially outside the liver parenchyma. Subsequently, surgical procedures, such as hepatectomy or transplantation, are excessive invasive surgery. Intrahepatic bile duct cyst and gallbladder resection and hepaticojejunostomy seem to be reasonable procedure for this case.

Conclusions

In conclusion, we report a case of solitary type V intrahepatic bile duct cyst with calculus and gallbladder stones treated with surgery. Decision of surgical procedure by the location of intrahepatic bile duct cyst is essential for the treatment.

Declarations

List of Abbreviations: None.

Ethics Approval and Consent to Participate: None.

Consent for Publication: None.

Availability of Data and Materials: None.

Competing Interests: None declared.

Funding: None.

Author's Contributions

KK drafted the manuscript. YD, TY and SM acquired data and revised the manuscript. RY, KK, NT and TI revised the manuscript. All authors read and approved the final manuscript.

Acknowledgements: None.

Author's Information: None.

References

1. Strasberg SM (2008) Clinical practice. Acute calculous cholecystitis. *N Engl J Med* 358: 2804-2811.
2. Al-Jundi W, Cannon T, Antakia R, Anoop U, Balamurugan R, et al. (2012) Percutaneous cholecystostomy as an alternative to cholecystectomy in high risk patients with biliary sepsis: a district general hospital experience. *Ann R Coll Surg Engl* 94: 99-101.
3. Todani T, Watanabe Y, Narusue M, Tabuchi K, Okajima K (1977) Congenital bile duct cysts: classification, operative procedures, and review of thirty-seven cases including cancer arising from choledochal cyst. *Am J Surg* 134: 263-269.
4. Mabrut JY, Partensky C, Jaeck D, Oussoultzoglou E, Baulieux J, et al. (2007) Congenital intrahepatic bile duct dilatation is a potentially curable disease: long-term results of a multi-institutional study. *Ann Surg* 246: 236-245.
5. Liu QY, Lai DM, Gao M, Wan YL, Lin XF, et al. (2013) MRI manifestations of adult choledochal cysts associated with biliary malignancy: a report. *Abdom Imaging* 38: 1061-1070.
6. Mabrut JY, Bozio G, Hubert C, Gigot JF (2010) Management of congenital bile duct cysts. *Dig Surg* 27: 12-18.

7. Singham J, Schaeffer D, Yoshida E, Scudamore C (2007) Choledochal cysts: analysis of disease pattern and optimal treatment in adult and paediatric patients. *HPB (Oxford)* 9: 383-387.
8. Jablonska B (2012) Biliary cysts: etiology, diagnosis and management. *World J Gastroenterol* 18: 4801-4810.
9. Diao M, Li L, Cheng W (2012) Timing of surgery for prenatally diagnosed asymptomatic choledochal cysts: a prospective randomized study. *J Pediatr Surg* 47: 506-512.
10. Edil BH, Cameron JL, Reddy S, Lum Y, Lipsett PA, et al. (2008) Choledochal cyst disease in children and adults: a 30-year single institution experience. *J Am Coll Surg* 206: 1000-1005.
11. Brown DK, Kimura K, Sato Y, Pringle KC, Abu-Yousef MM, Soper RT (1990) Solitary intrahepatic biliary cyst: diagnostic and therapeutic strategy. *J Pediatr Surg* 25: 1248-1249.
12. Burke ZD, Boechat I, Tabsh K, Deugarte DA (2014) Solitary diverticular type V bile duct cyst. *Pediatr Surg Int* 30: 245-247.
13. Boyden EA (1926) The accessory gall-bladder: an embryological and comparative study of aberrant biliary vesicles occurring in man and the domestic mammals. *AJA* 38: 177-231.
14. Gorecki PJ, Andrei VE, Musacchio T, Schein M (1998) Double gallbladder originating from left hepatic duct: a case. report and review of literature. *JSLs* 2: 337-339.
15. Kim RD, Zendejas I, Velopulos C, Fujita S, Magliocca JF, et al. (2009) Duplicate gallbladder arising from the left hepatic duct: report of a case. *Surg Today* 39: 536-539.
16. Cho MJ, Hwang S, Lee YJ, Kim KH, Ahn CS, et al. (2011) Surgical experience of 204 cases of adult choledochal cyst disease over 14 years. *World J Surg* 35: 1094-102.