

Case Report

DOI: 10.29011/2575-9760.001169

Krukenberg Tumors: Two Cases Report and A Literature Review

Marion Crisinel, Meriem Boukrid, Anis Feki, Jean Bouquet de la Jolinière*, Fathi Khomsi Department

of Gynecology and Obstetrics, Cantonal Hospital of Fribourg, Villars-sur-Glâne, Switzerland

***Corresponding author:** Jean Bouquet de la Jolinière, Department of Gynecology and Obstetrics, Cantonal Hospital of Fribourg, HFR, 6 chemin des pensionnats. 1708 CH, Switzerland. Tel : +41263060000; Email: jean.bouquetdejoliniere@h-fr.ch

Citation: Crisinel M, Boukrid M, Feki A, de la Jolinière JB (2018) Krukenberg Tumors: Two Cases Report and A Literature Review. J Surg: JSUR-1169. DOI: 10.29011/2575-9760.001169

Received Date: 10 September, 2018; **Accepted Date:** 21 September, 2018; **Published Date:** 24 September, 2018

Abstract

Krukenberg tumors are rare cases of metastatic ovarian tumors. Generally, they are bilateral and 70% originate in the stomach, but they can also originate in other organs. They are normally found in young women, on average at 45 years of age, and normally present symptoms due to ovarian involvement: abdominal pain, bloating, nonspecific gastrointestinal symptoms or ascites with malignant cells. They can also be asymptomatic. The diagnosis of the primary tumor can be made before surgery, during further investigations, or during the months following operative surgery. CT and MRI allow the diagnosis and the follow up. The best exam is surely the PET-CT to evaluate an extension (metastasis). Post-surgical and post-therapeutic monitoring is provided by these images. The primary tumor is often too small to be detected and diagnosis depends on meticulous radioscopic and endoscopic exploration. They're usually found in young women. Our two cases imposed a difficult discovery but a good survival for both.

Reported Cases

We were able to identify two cases of Krukenberg tumor in Fribourg, Cantonal hospital, during 2016, and we carried out a review of the existing literature about Krukenberg tumors.

Materials

First Case

Mrs. R.D., 62 years old, 2G2P, who presented with abdominal cramps along with constipation and a weight loss of 7 kg. The endoscopic and radiological exams both concluded with the diagnosis of adenocarcinoma. The patient underwent a left hemicolectomy with sigmoid resection, Complete Mesocolic Excision (CME) and side-to-end anastomosis two months later. The definitive anatomo-pathology report showed a moderately differentiated adenocarcinoma, ulcerated and stenosing, with an infiltration of all the layers of the colic wall, multifocal overtaking of the serosa, and venous and perineural infiltration (tumor size 3 cm), 3 positive lymph nodes out of 20. No notion of microsatellite instability on the immunohistochemistry. The final TNM UICC 2009 classification was pT4a N1 (3/20) V1 Pn1 R0 (axial sections) G2. The patient was next treated with an adjuvant chemotherapy of 10 doses of FOLFOX (5-FU and Eloxatine) and 2 doses of 5-FU

and Leucovorin for 6 months. The follow-up CT-scan, about one year after the primary surgery, showed a massive cystic mass of 125 x 130 x 160 mm, with septations, on the ovary with suspect lesions on the spleen and the liver (Figures 1-3).

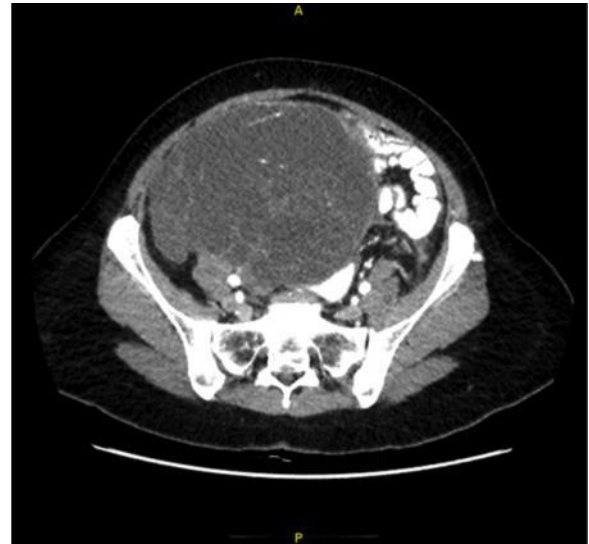

Figure 1: Follow-up CT-scan - appearance of a huge pelvic mass.

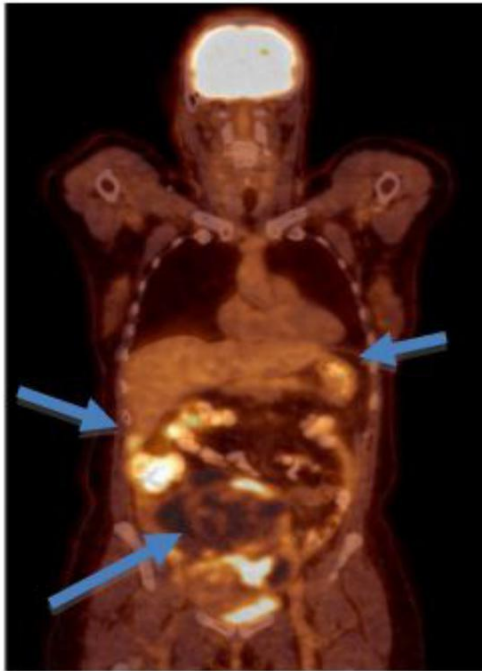

Figure 2: PET-CT 18-FDG-pelvic mass, hyperactive lesions in the liver and the spleen.

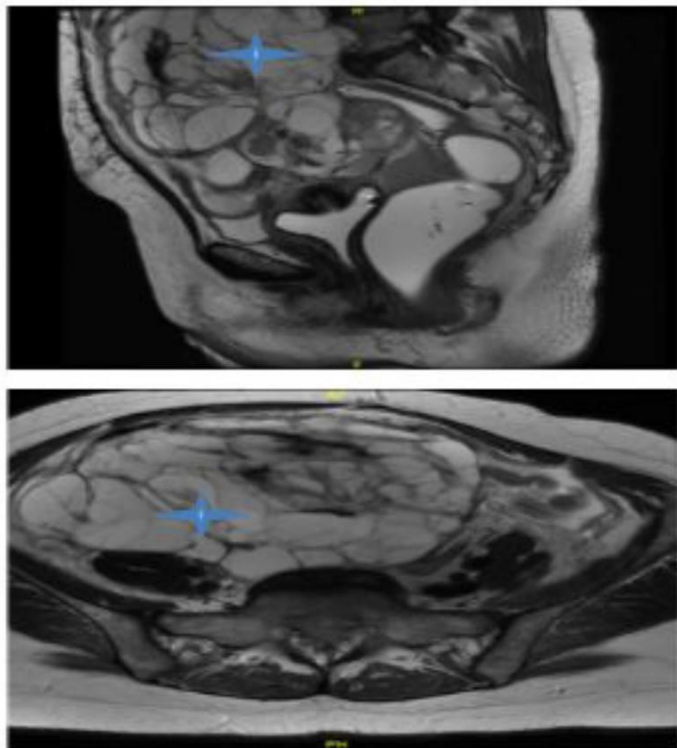


Figure 3: MRI sagittal view T2 (up) and axial view T2 (down).

The CEA was 7.3 ng/ml, the CA 125 was 200 U/ml, the CA 15-3 was 18.6 U/ml, the CA 19-9 was 30 U/ml and the AFP was 1.3 ng/ml. The patient underwent a bilateral adnexectomy, a total hysterectomy, the ablation of a 19 cm annexial mass with omentectomy, appendectomy, splenectomy, resection of hepatic metastasis of segment VI and peritoneal washing under the care of the gynecology and surgical teams. Postoperative period care was uneventful. The definitive histology was positive for bilateral ovarian metastasis with uterine infiltration of a stenosing adenocarcinoma of the descendant colon. The peritoneal washing was negative. The case was presented at the Tumorboard, which proposed a palliative chemotherapy with Erbitux and FOLFIRI and the follow-up thoraco-abdominal CT-scan of 02.01.2017 did not show any evidence of new lesion.

Second Case

Mrs. R.L., 52 years old, 2G2P, menopausal for 2 years, who initially presented with epigastralgia with no sign of improvement despite an appropriate treatment. The endoscopic examinations as well as the biopsies were negative. The radiologic exam with MRI showed two ovarian masses of 10 and 14 cm of diameter (Figure 4), with heterogeneous hypercaptation on the PET-CT (Figure 5).

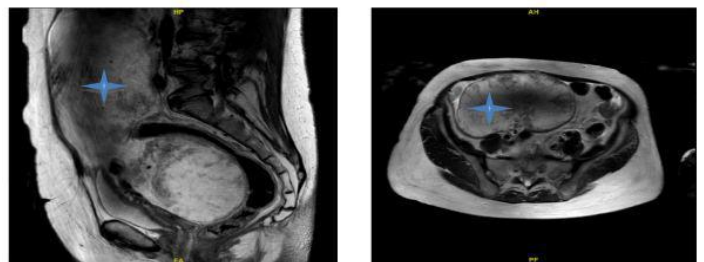


Figure 4: MRI sagittal view T2 (left), axial view T2 (right).

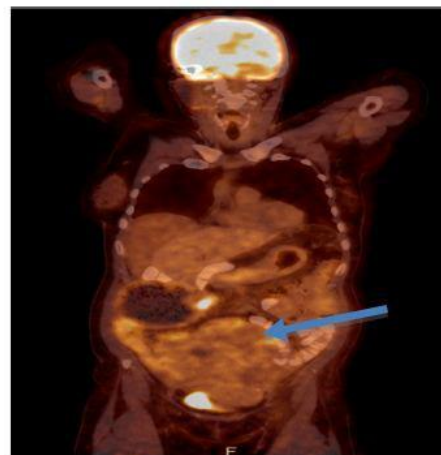


Figure 5: PET-CT 18-FDG heterogeneous hypercaptation of the pelvic tumor.

For the tumoral markers, the CA 19-9 was 236 U/ml, the CA 125 was 149 U/ml and the CA 15-3 was 11-6 U/ml. The patient underwent a median laparotomy, which showed massive ascite, a caecal and right colic dilatation on the anterior face with a stenosis of the right external third of the transverse colon and the presence of a gastric linitis with retroperitoneal infiltration of the entire susmesocolic space. The pelvis contained two solid masses, each of 12 cm of diameter. A bilateral adnexectomy, a total hysterectomy and a right hemicolectomy were performed. Postoperative period care was uneventful.

The cytology of the ascites showed atypical cells, malignant, of an undifferentiated adenocarcinoma. An immunohistochemical study was made, but the origin of the cells could not be identified on the sample. The definitive histology showed an adenocarcinoma, mostly with signet ring cells, with bilateral infiltration of the ovaries, infiltration of the colic wall, peritoneal carcinosis and vascular, lymphatic and perineural invasion; 15 out of 21 lymph nodes were positive. The final diagnosis was a gastric cancer, type adenocarcinoma, stage IV, with ovarian metastasis. The Tumorboard proposed chemotherapy mDCF (Taxotere, 5-FU, Platinol) for which the patient had a portacath inserted. The treatment was well tolerated by the patient and a new PET-CT didn't show any suspicious lesions.

Literature Analysis

Krukenberg tumors are unusual metastatic tumors of the ovaries first described by Friedrich Krukenberg, a German gynecologist and pathologist, in 1896. In 1902 Schlagenhauser emphasized that these ovarian tumors do not originate in the ovary, but are metastases from a primary malignancy somewhere else. Moreover, Schlagenhauser stated that the most common primary site is the gastrointestinal tract [1].

- Nowadays, the term “Krukenberg tumor” indicates any ovarian metastatic carcinoma deriving from a primary malignancy. However, the World Health Organization’s diagnostic criteria states that a diagnosis of a Krukenberg tumor is based on the presence of stromal involvement, mucin-producing neoplastic Signet Ring Cells (SRCC) and ovarian stromal sarcomatoid proliferation [1].
- From 2008 to 2012, an incidence of 584 cases of ovarian cancer was seen in Switzerland, which accounts for 3.3% of all new cases of cancer. The mortality of those tumors is high during the same period, with 425 deaths, which means 5.9% of all cancer deaths. The incidence is the same as the one found in central Europe or in North America [2].
- Metastatic tumors among ovarian carcinomas are rare (about 7%) and Krukenberg tumors represent only 1-2% of all ovarian tumors [1,3]. The signs in favor of metastasis are bilateralism (74% of the cases are bilateral), size of the lesion, involvement of the surface and important intra-abdominal extension [4]. The women who suffer from Krukenberg tumors are particularly

young, with an average age of 45 years [5].

- The stomach is the main primary site of Krukenberg tumors, and represents 70% of the cases, as in our 2nd case study; for this reason, the frequency of those tumors in different countries varies along with the one of gastric carcinoma [5]. The next more frequent localizations are colon (as in our 1st case study), appendix and breast (most invasive lobular carcinomas). Rarely, cases are described coming from the biliary tract, the pancreas, the small intestine, the ampulla of Vater, the cervix and the bladder. Sometimes, the primary tumor is very small and can escape detection, which is the case in our second patient [5].
- Two different sorts of metastasis can be described: synchronous metastases, which are discovered simultaneously with the primary tumor, and metachronous, more frequent, discovered after the primary tumor [6]. The ovaries are the second most frequent sites of metastasis of gastrointestinal tumors, after the liver. The route of metastasis is a controversial mechanism. The most probable hypothesis is that the malignant cells follow a retrograde lymphatic trajectory, a hypothesis supported by microscopic evidence on the lymphatic capillaries, by the initial involvement of the gastric mucosa and the submucosa (rich in lymphatic capillaries) and by some studies that showed a higher risk of ovarian metastasis when more lymph nodes are involved. Moreover, the theory of extension through the peritoneum is minimized because of the frequent lack of tumor cells on the peritoneum and the absence of implants on the surface of the ovaries [5].
- A lot of patients initially present with symptoms of the metastases instead of those of the primary tumor [1]. They are mainly abdominal bloating with a sensation of discomfort, weight loss, dyspnea, abdominal pain, some nausea or vomiting or epigastric pain. Most patients present non-specific gastrointestinal symptoms or are asymptomatic.
- A virilization can also be present, because of the hormonal production of the ovarian stroma. In 50% of cases, ascite is seen with frequent presence of some malignant cells [5].
- The clinical exam can reveal an abdominal or pelvic lesion.

Discussion

- In our two cases, the patients are rather young, respectively 52 and 62 years old. The symptoms are also in both cases non-specific. In the first case, there were no symptoms and in the second case, only some gastrointestinal symptoms with epigastralgia, which can come from the gastric carcinoma itself and with ascite discovered per-operatively, that contained malignant cells.
- Sonography is a good method for the initial evaluation of ovarian neoplasms. CT does not increase the diagnostic accuracy, but can show the extent of the disease, better evaluate the gastrointestinal tract, evaluate recurrent carcinoma and follow the response to treatment.

- When a CT is performed as a preoperative evaluation of gastric or colon carcinoma, the ovaries should also be looked at for possible Krukenberg tumor. On CT, Krukenberg tumors typically look like an oval or kidney-shaped mass, with preservation of the ovary contour. Usually, they're solid or predominantly solid with central necrosis and with an enhancement of solid components or septations after contrast media administration. They can also look like large lobulated cystic masses. Unilateral involvement may be seen, with a normal contralateral ovary, but most of the time the lesions are bilateral.
- On MRI, Krukenberg tumors have either low or high signal intensity on T2-weighted images because they can have abundant collagen formation or marked oedema. They appear normally as complex masses with hypo-intense solid components, with some hyperintensity on T1 and T2-weighted MR images. The wall of the cyst usually shows contrast enhancement [7] (Figures 1,3,4).
- It can be difficult or impossible to make a clear distinction between primary and metastatic ovarian cancers [8,9]. However, a bilateral, sharply delineated, predominantly solid lesion with necrosis suggests metastasis [10,11] (Figure 2,5).
- 3.6 In many cases, the CA 125 is higher in the patients with a Krukenberg tumor, and it decreases after surgery. Thus, it is possible to use this marker for follow-up after a complete resection of the tumor, also for the follow-up of patients known to have an adenocarcinoma of the gastrointestinal tract in order to detect an ovarian involvement early [5].
- In our two patients, the CA 125 was high, 149 and 200 U/ ml respectively. Those values represent a poor prognosis; indeed, the 5-years survival rate is decreased in patients with a postoperative CA 125 level above 75 U/ml [5].
- Theoretically, systemic chemotherapy is the optimal treatment for recurrent or metastatic gastric cancer. However, in the case of Krukenberg tumors, this modality doesn't show any significant survival benefit because the medication normally used for gastrointestinal tract carcinomas has a low anti-neoplastic activity in the ovaries, which represent a sanctuary for the cancer cells [12]. Likewise, a metastasectomy is not clearly beneficial for this precise case. It is also to be noted that as a lot of Krukenberg tumors are metachronous, many patients have already been treated by chemotherapy before the metastasis appears. Presently, we don't have a clear treatment protocol for those tumors.
- A Korean study from 2014 [6] compared the survival benefit of the possible treatments for Krukenberg tumors. The results show that regardless of tumor stage, the patients with complete resection of metastasis and chemotherapy have a better survival rate than those with chemotherapy only. Surgery however is controversial because of the poor prognosis, the bad tolerance of the patients to the surgery, the bad resectability rate and the high risk of surgical complications [5]. In patients with

unilateral metastasis and surgical resection, the unaffected ovary should always be removed, because it has the same probability to be reached by the cancer cells and could already contain micro-metastases. Most authors also suggest that bilateral oophorectomy is prophylactically indicated at the time of colon resection [5].

Conclusion

For now, we only have a restricted vision on our cases follow-up, given the recent date of their occurrence. However, the two patients are now under adjuvant chemotherapy, with absence of lesion recurrence on control CT-scan Krukenberg tumors generally have a poor prognosis, with death of most of the patients in the 2 years after the diagnosis has been made (median survival is 14 months) [12]. Furthermore, the prognosis is worse for patients in whom the primary tumor is discovered after the metastasis and even worse if the primary tumor stays unidentified. The presence of other metastases after the ovary is also a sign of a poor prognosis [5].

In both cases of Krukenberg tumors that we treated at HFR-Fribourg during 2016, both originated from the gastrointestinal tract, one from the stomach and the other one from the colon, initially at an advanced stage and finally a palliative stage. These tumors are rare, but it's very important to be able to recognize them and to treat them early because of their bad prognosis. The difficulty is that this disease is rare, and it can take a lot of time to make the diagnosis, which is made with the help of radiologic and other complementary investigations. For now, the best treatment to improve prognosis seems to be surgery, in addition to a multidisciplinary oncological approach.

Ethics Statements

Written informed consent was obtained from the patient prior to presenting the two cases. No ethical problem and no conflict of interest.

Author Contributions

Each of the authors (MC, MB, NBA, TO, AF, JBJ and FK) participated in caring for the patient. MC is the principal author.

References

1. Spinelli C, Liloia C, Piscioneri J, Ugolini C, Stramb S (2016) An Unusual Evolution of Krukenberg Tumor: A Case Report. Journal of Clinical and Diagnostic Research 10: 7-11.
2. Cancer data extracted from the Swiss national dataset managed by the Foundation National Institute for Cancer Epidemiology and Registration (NICER) 2017.
3. Ghosh A, Ghartimagar D, Thapa S, Sathian B, Narasimhan R, et al. (2016) Ovarian Tumors: Pattern of Histomorphological Types - A 10 Years Study in a Tertiary Referral Center and Review of Literature. Kathmandu University Medical Journal 54: 153.

4. Bayod MJ, Carlón ME, Idoate MA (2007) [Pseudomeigs syndrome in a patient with Krukenberg's tumor]. *Rev Med Univ Navarra* 51: 19-22.
5. Osama M, Al-Agha, Nicastrì AD (2006) An In-depth Look at Krukenberg Tumor. *Archives of Pathology and Laboratory Medicine* 130: 1725-1730.
6. Jang HC, Lim JY, Choi AR, Choi SM, Kim JW, et al. (2015) Comparison of Surgery Plus Chemotherapy and Palliative Chemotherapy Alone for Advanced Gastric Cancer with Krukenberg Tumor. *Cancer Research and Treatment* 47: 697-705.
7. Imaoka I, Wada A, Kaji Y, Hayashi T, Hayashi M, et al. (2006) Develop-ing an MR imaging strategy for diagnosis of ovarian masses. *Radio-graphics* 26: 1431-1448.
8. Mateş IN, Iosif C, Bănceanu G, Ionescu M, Peltecu G, et al. (2008) Features of Krukenberg-type tumors--clinical study and review. *Chiru-rgia (Bucur)* 103: 23-38.
9. Man M, Cazacu M, Oniu T (2008) Physiopathologic and clinical aspects of Krukenberg tumors. *Chirurgia (Bucur)* 103: 13-15.
10. Bartalena T, Rinaldi M, Alboni C, Giannelli G, Leoni C, et al. (2008) Krukenberg Tumor from Gastric Adenocarcinoma: CT findings. *The Internet Journal of Radiology* 2008: 10.
11. Cho CK, BM Gold (1985) Computed Tomography of Krukenberg Tumor. *American Journal of Roentgenology* 145: 2.
12. Xu KY, Gao H, Lian ZJ, Ding L, Li M, et al. (2017) Clinical analysis of Krukenberg tumors in patients with colorectal cancer - a review of 57 cases. *World Journal of Surgical Oncology* 15: 25.